

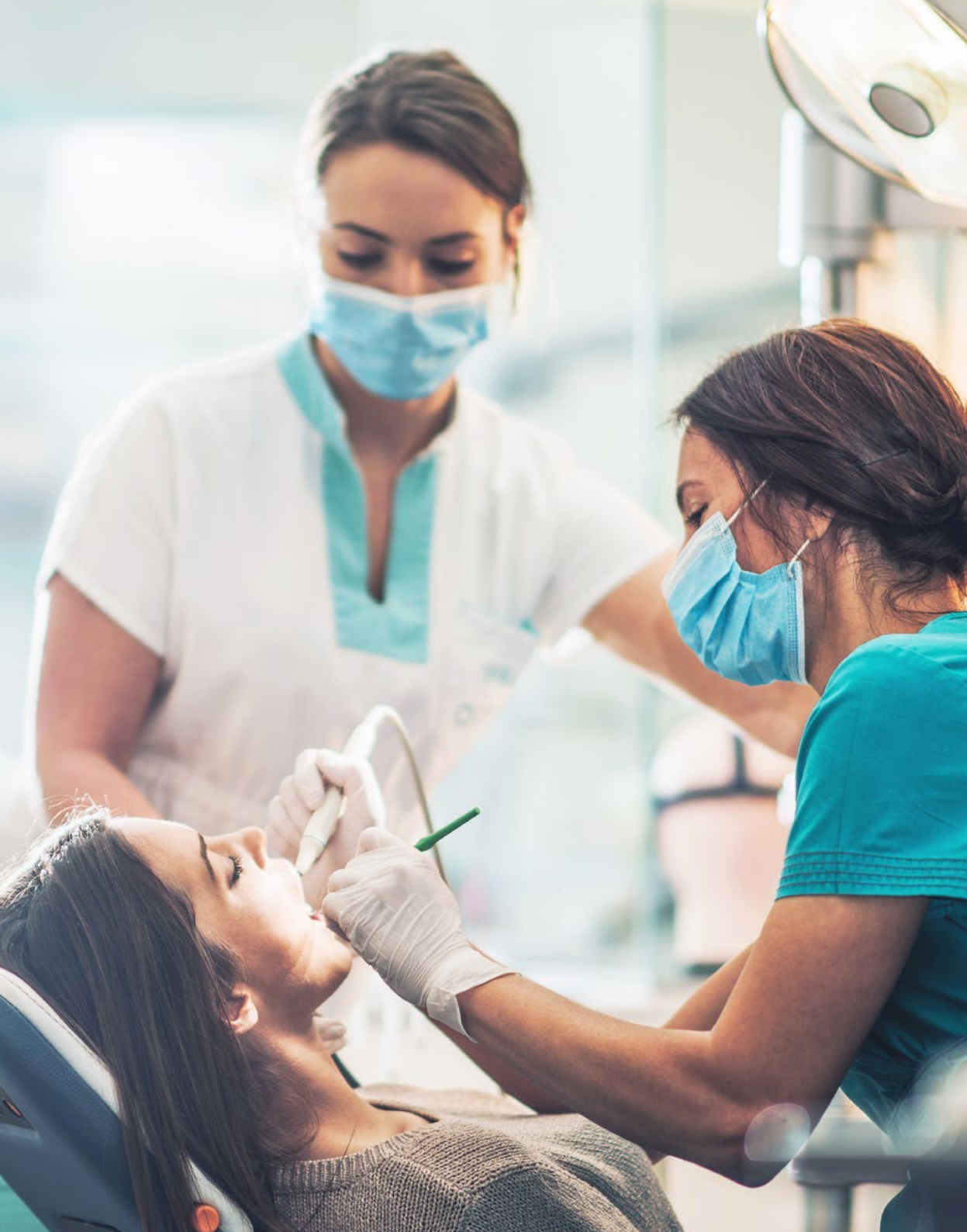

# CLINICAL CASES VIRTUO VIVO™



BRAZIL, 2022

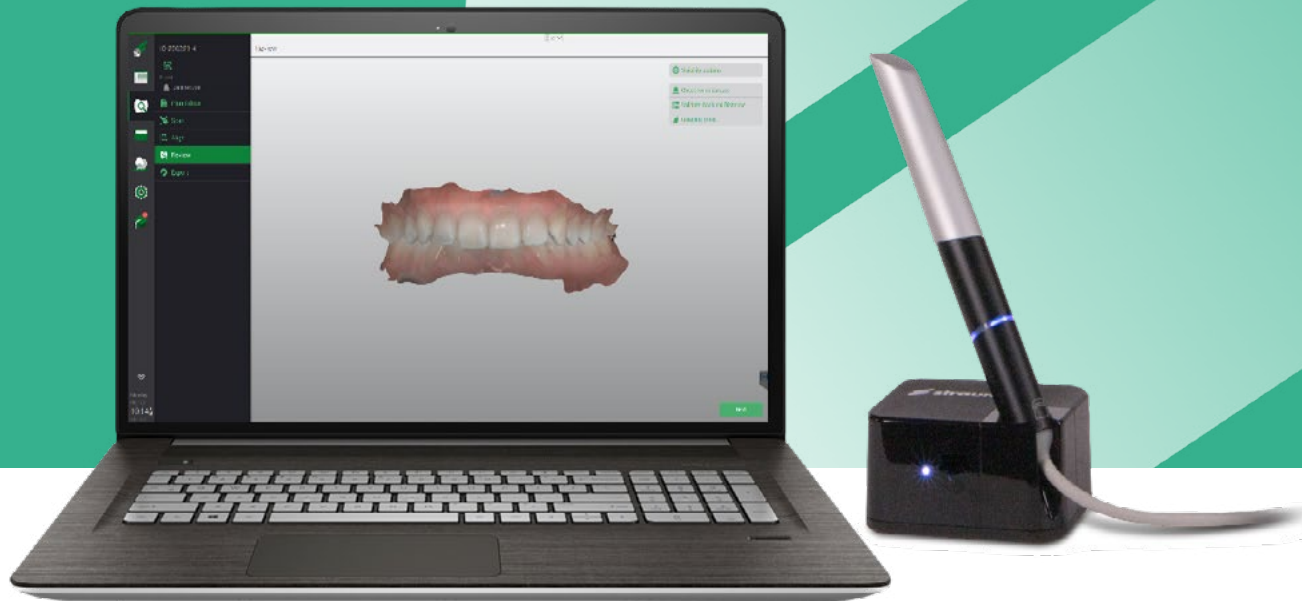




## DEAR DOCTOR,

Digital technology is driving changes that can be seen across the world of dentistry. While technology can make practices productive and more comfortable for the patient, it also helps the practices to sharpen their level of competition and their differentiation. So it is in our combined interest to embrace every opportunity technology has to offer in order to stay ahead of the game. This also means knowing how to highlight what makes your practice stand out from the crowd.

As a world leader in implants, Straumann is constantly developing solutions that offer the highest level of technology. Our aim is to always be at the cutting edge of our industry, empowering our partners to offer world-class treatments. One of our key solutions is the Virtuo Vivo™ Intraoral Scanner, which has already opened the door to the digital world for many dentists.



The use of Virtuo Vivo™ revolutionizes clinical practice, bringing with it improved productivity, simplicity, flexibility and profitability. Introducing Virtuo Vivo™ into your clinic, will open up new opportunities of digital workflows with Straumann® software and service offerings. This will result in an experience that is easy and more efficient for you and more comfortable for your patients.

This e-book details some case reports which explore the use of Virtuo Vivo™ in different situations. The cases come from clinicians who are also beta users, who have been asked to present the planning, procedures and conclusion for each case. We hope these reports inspire you to adopt the best of what digital dentistry has to offer: efficiency, predictability and profitability.

Happy reading!

# CONTENTS

**01** Digital dentistry ..... 05

**02** Case reports ..... 06

**2.1** Dr. Rafael Gama - Veneers and crowns



# DIGITAL DENTISTRY AND ITS **BENEFITS**

The use of a wide range of technologies in dentistry allows procedures that are safer, quicker, more predictable and effective. Technology plays an ever-increasing role in our dentistry practices and prosthetics labs. This benefits the dental professionals by reducing procedure times, and patients by reducing discomfort during treatment.

The digital workflow includes the use of 3D images obtained through intraoral scanning and CBCT (Cone-Beam Computerized Tomography). It also includes the use of software to assist in treatment planning, as well as 3D printers or ceramic grinding and milling, which use prototyping to produce models, surgical guides, restorations or provisional and definitive prostheses.

Automation in dentistry can be divided into three different processes: CAI, CAD and CAM. CAI (Computer Aided Imaging) is the first step in the digital workflow; CAD (Computer Aided Design) is the digital creation and analysis phase, while CAM (Computer Aided Manufacturing) is the computer-controlled production stage, such as grinding and milling.

## DID YOU KNOW THAT...

**2 OUT OF 3 PATIENTS** would consider switching to a dentist who uses more advanced technology.

**72% OF PATIENTS** had a positive experience when their last visit included advanced technology.

Source: The Need for Digital Dentistry Education: A Global Evaluation of Patients' Awareness, Attitudes and Behaviors. Carestream Dental. here. Accessed December 16, 2022.



Simpler and more streamlined workflow



Easy and efficient data exchange with your network



Reduced treatment and chair time



Increased patients comfort



Improved patient communication

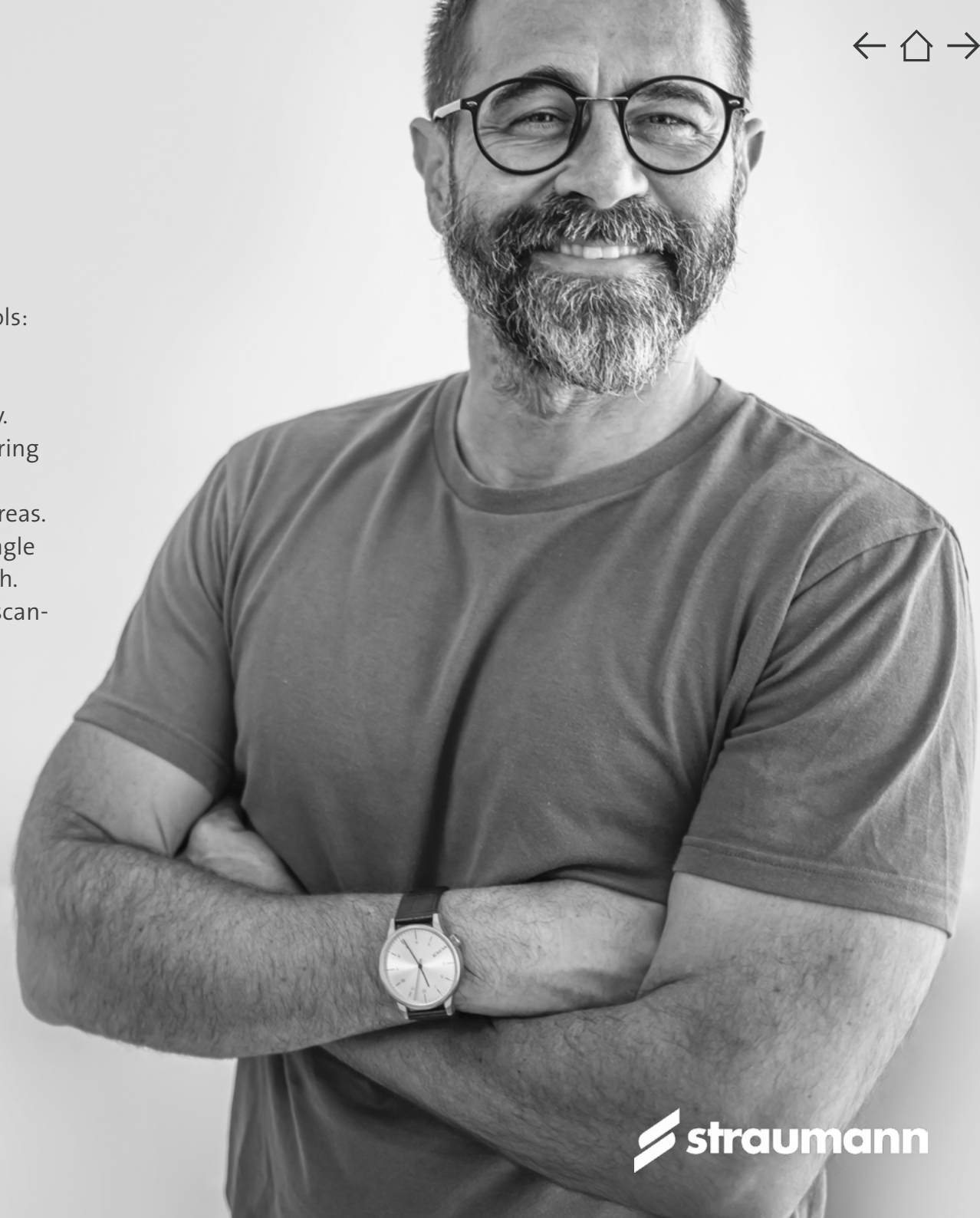

New market positioning for the practice

# CASE REPORTS

Each case presented here followed the recommended protocols:

- 1 - Clean the mirrors on the tip before each scan.
- 2 - Avoid saliva on the scan, use the saliva ejector if necessary.
- 3 - Avoid direct light on the scan, less light is better for capturing the image.
- 4 - Try to angle the handpiece to capture more inaccessible areas.
- 5 - Use the “rock and roll” scanning technique, waving the angle of the handpiece 45 degrees to each side of the dental arch.
- 6 - Scanbodies: validate in the scanner library at the time of scanning to confirm.
- 7 - Run the integrity test at regular intervals (at least once a week).
- 8 - Always scan with the laptop connected to the socket.
- 9 - Always connect the handpiece to the POD.
- 10 - Check the software version is up-to-date.



# 2.1 VENEERS AND CROWNS

## CASE REPORT

Male patient, smoker, presented at the practice determined to undergo major aesthetic treatment. Clinical assessment detected the need to align the zenith of tooth 21, slight crowding in the lower central incisors, minimal overjet class 2.

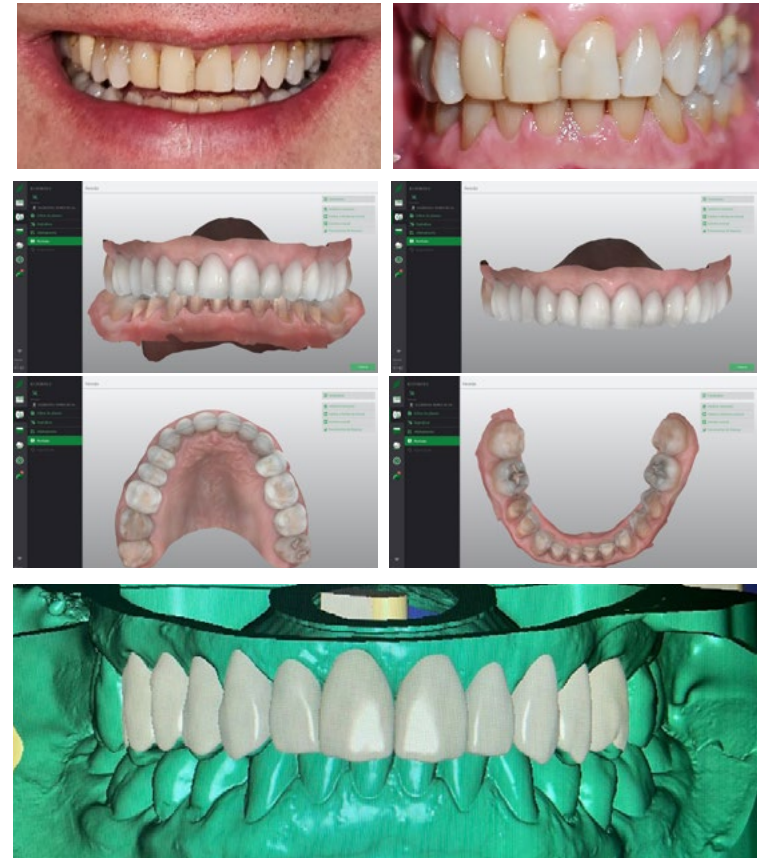## PLANNING

- Imaging assessment
- Photographs
- Periodontal aesthetic surgery tooth 21
- Arch scan with Virtuo Vivo™ scanner
- Virtual planning and wax-up
- 3D printing of the models for mock-up and provisionals
- Tooth preparation plus scanning
- Digital planning of the definitive restorations
- Dental impression with burn-out resin
- Injection of e.max
- Cementing, adjustments, finishing and post-cementing X rays



### Dr. Rafael Gama

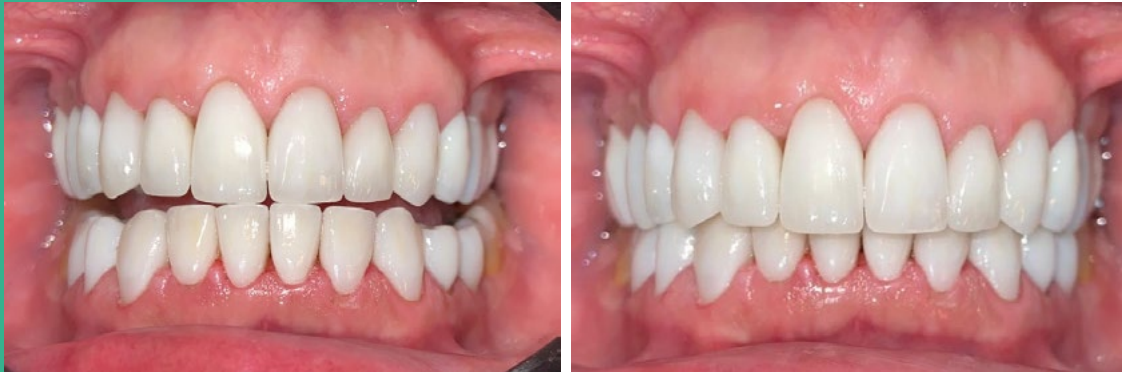
Masters in Digital Dentistry  
Speaker Digital Straumann  
Member of SBO Digital  
Specialist in Implantology  
Specialist in Orthodontics  
Post-graduate in periodontology  
Post-graduate in endodontology






# 2.1

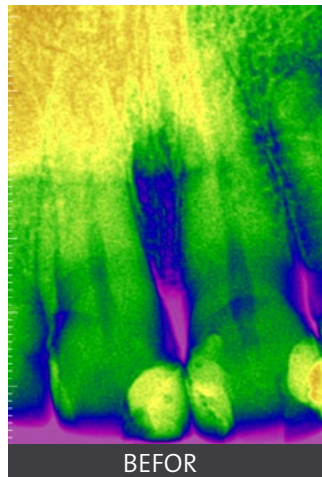
## 2.1 VENEERS AND CROWNS



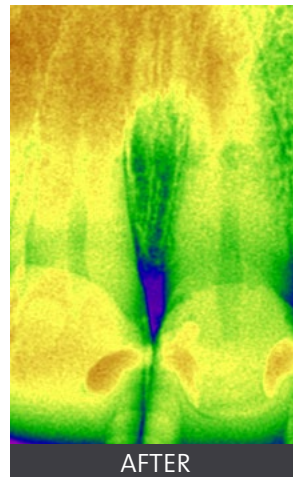
BEFORE



AFTER



BEFOR



AFTER

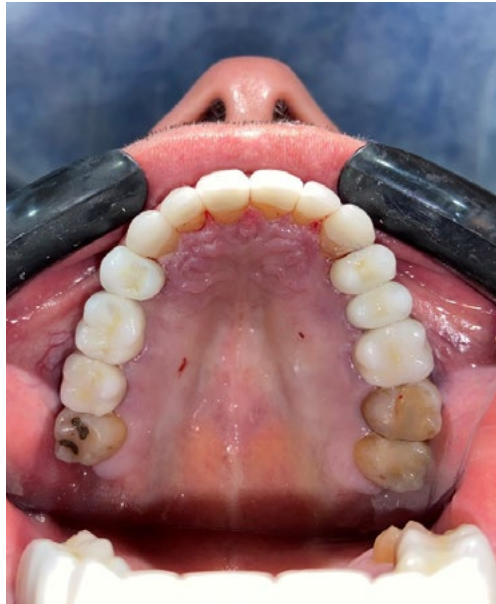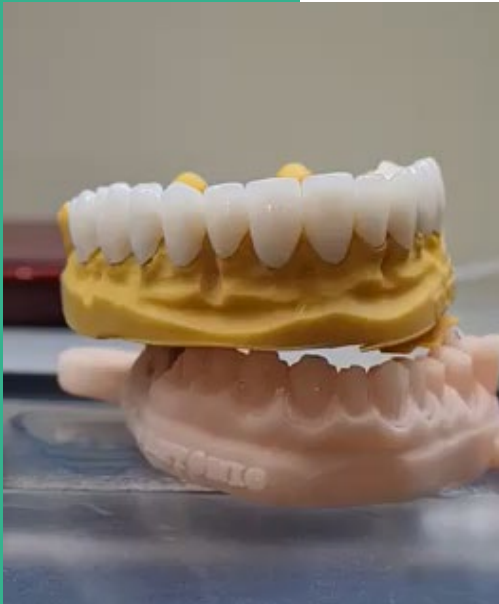### PROCEDURE

An initial gingivoplasty involving a flapless osteotomy on tooth 21, with the aim of aligning the gingival zenith. After thirty days, we entered the prosthetic stage, taking an initial scan and combining it in planning software with the photographs to show the patient what his future smile would like look like. The proposed plan was printed in 3D, which served as a mock-up and was used to manufacture the provisional restoration with bis-acryl resin after the preparation phase. Software was used at the lab to refine the initial wax-up and the dental printing in burn-out resin for later injection of the ceramic, e.max. We followed up with cementing, slight adjustments and final X rays to assess the fit.



2.1

VENEERS AND CROWNS



**CONCLUSION**

Digital workflow using Virtuo Vivo™ has demonstrated excellent results, providing both dental surgeon and patient with an experience that would never have been possible with an analog workflow. With each passing day, new techniques are rapidly appearing and evolving, driven by the growing demands of a society that demands flexible precision dentistry.

## 2.2 ONE-TOOTH ONE-TIME

### CASE REPORT

32-year-old male patient presenting with missing tooth 25 as a result of a fracture. The bone tissue was totally healed, measuring 9.5 mm from the alveolar crest to the cortical bone of the maxillary sinus, 8.5 mm from the vestibular bone wall to the palate with an average bone density of 431HU. The mesiodistal dimensions were compatible with those of the missing tooth, while there was plenty of keratinized tissue.

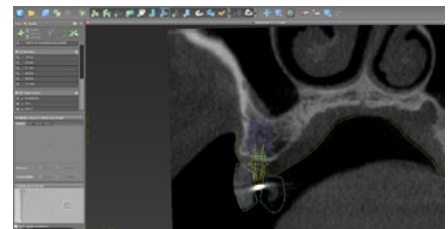
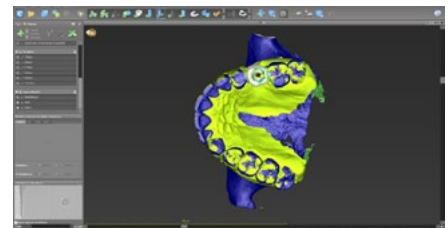
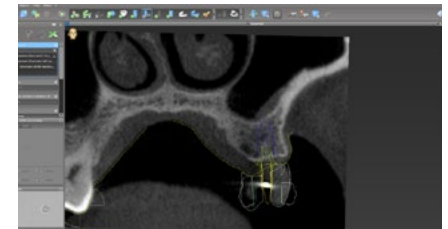
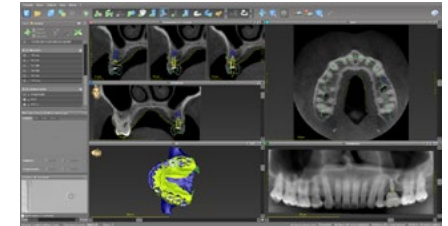
### INTRODUCTION

The rehabilitation of complete or partial edentulism with dental implants is already a well-documented practice and used in clinical routine. However, patients are always uncomfortable about the time required for prosthetic rehabilitation. Technological advances have reduced this period over the years, with improvements in the biological response and rapid evolution of secondary stability. More recently, immediate loading has become safer and more reliable with the combination of the SLActive® surface with dynamic macrogeometry. The reliability achieved has revolutionized contemporary oral rehabilitation, leading to the concept of one-tooth one-time. This concept aims to do much more than simply re-establish the prosthetic crown; it aims to re-establish the whole aesthetic around the lost tooth. Its application also optimizes the process of obtaining the emergence profile and biological distances in a single process.



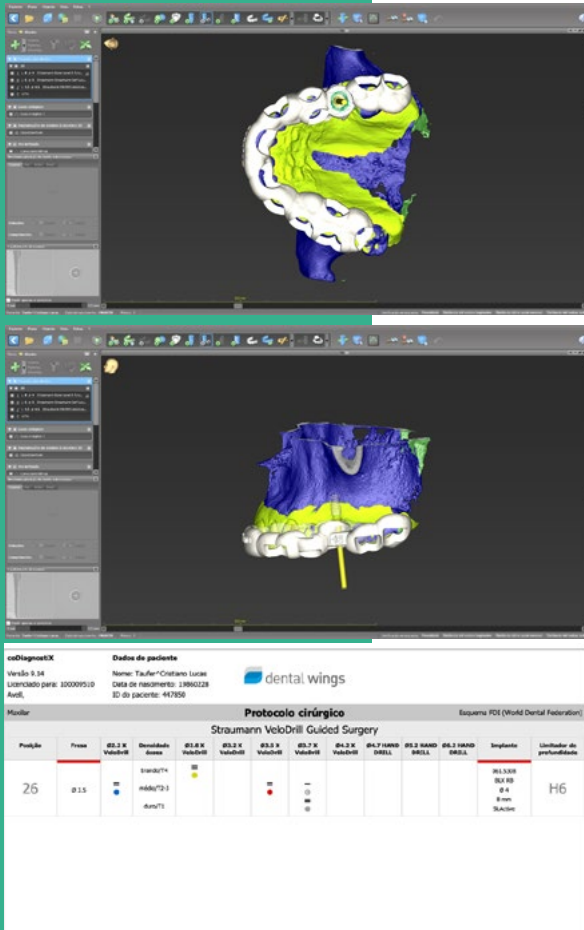
#### Dr Luiz do Carmo

Specialist in Periodontology  
– AONP/PR, Specialist in  
Implantology – Univ Norte do  
Paraná, Master in Implantology  
– SLMandic, Doctor in Dentistry  
– FOP Unicamp, ITI Fellow, ITI  
Speaker, ITI Study Club Director  
and Professor at Universidade  
Positivo



# 2.2

## ONE-TOOTH ONE-TIME

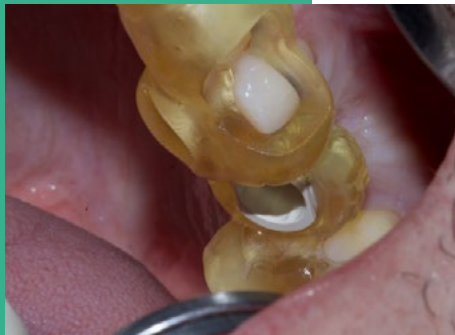
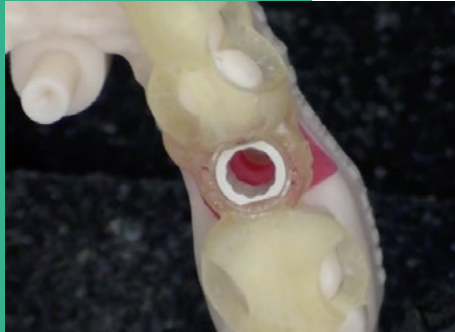


### PLANNING

To supplement clinical and laboratory examinations, the patient underwent cone beam computerized tomography and an intraoral scan with the Virtuo Vivo™ scanner to capture the STL file. The files generated by the computerized tomography (DICOM) and the scanning files (STL) were imported with the coDiagnostiX® planning software. Once the files were imported, they were aligned to reproduce the patient’s bone, tooth and mucosal anatomy. This reproduction of the clinical conditions enables precise reverse planning in a virtual environment and the manufacture of a surgical guide for accurate reproduction of the plan. Surgical planning was carried out using implant BLX, which is safer and more reliable in immediate loading. Alongside implant planning, prosthetic planning was carried out based on the Variobase® Ø 4.5 mm GH 1.5 mm. This implant and abutment position was exported virtually in STL format from the coDiagnostiX® software. The STL file with scanbody was produced by surgical planning in the coDiagnostiX® software. The prosthetic crown was then designed using Straumann® CARES® Chairside software. Thanks to its excellent balance between flexural strength and rigidity, and its outstanding polishing performance with just rubber after the milling process, Straumann® n!ce® glass ceramic was chosen as the restorative material. The surgical guide and prosthetic model were printed after planning. The ceramic crown was also milled to be placed immediately after implant placement.

## 2.2

# ONE-TOOTH ONE-TIME



### SURGICAL PROCEDURE

Local infiltration anesthesia was administered at the missing tooth site. The guide was put in place and the fit with the support teeth was assessed.

Using the BLX Surgery Guide surgical kit, only the site where milling was to be carried out was removed with the rotating punch.

The milling sequence set out in the surgical protocol for the planned implant was followed using varying length of drills and handles to position the implant correctly.

The implant was then placed with a torque of up 50 Ncm at the end of the preparation. This ensures excellent initial stability for immediate prosthetic loading.

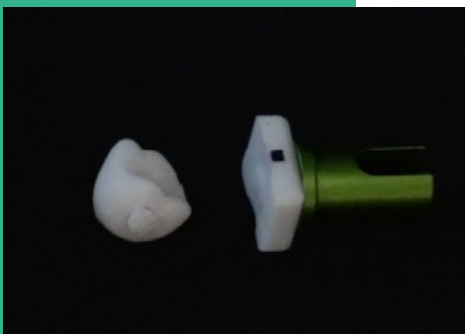
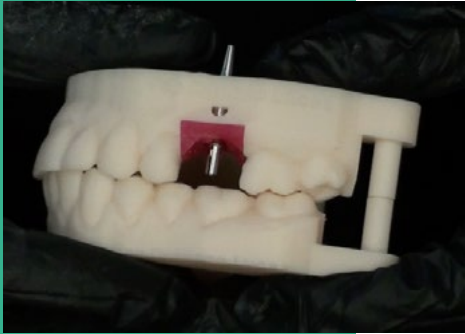
### PROSTHETIC PROCEDURE

After the surgical procedure, the Variobase® Ø 4.5 mm GH 1.5 mm abutment was placed without torque followed by the try-in of the previously milled crown. Once positioning had been checked and proximal contacts adjusted, the internal interface of the glass ceramic crown was acid-conditioned (hydrofluoric acid), and this was cemented onto the selected abutment. Excess cement was removed and the edges polished again. Once the finishing was complete, the crown was placed and the occlusal contacts checked again to avoid any implant overload.



## 2.2

# ONE-TOOTH ONE-TIME

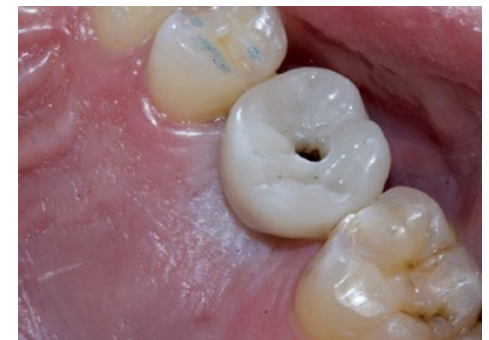
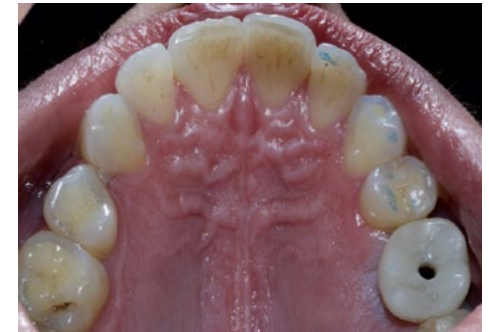
### TREATMENT OUTCOME

Once the procedures were finished, the crown was placed with 35 Ncm torque. The patient was reassessed after 6 weeks for bone integration and peri-implant condition. Excellent peri-implant and cervical contour condition were observed. The patient also reported that he had felt very comfortable and reassured both during and after the procedure.

### CONCLUSION

The one-tooth one-time concept is a revolution in implant-supported rehabilitation. This is thanks to the use of BLX implants offering state-of-the-art macrogeometry and surface treatment with highly reliable immediate loading combined with a digital workflow using coDiagnostiX® and Straumann® CARES® Chairside software, which ensure precision and comfort, greatly reduce intraoperative and post-operative discomfort and allow for treatment flexibility at all stages of the procedure. The one-tooth one-time concept will undoubtedly become the gold standard in implant-supported rehabilitation.



## 2.3 GUIDED DENTAL IMPLANT

### CASE REPORT

44-year-old male patient presented longitudinal fracture in tooth 15 (fig. 1), confirmed in the cone beam computerized tomography examination, indicating surgical removal of the tooth and placement of an immediate implant.

### INTRODUCTION

One of the options for dental implant treatment is guided implant surgery, performed using digital planning which requires a DICOM (tomography) file and a STL (Intraoral scanning) file. In this particular case, the Virtuo Vivo™ scanner (fig. 2) was used to obtain a file for planning in coDiagnostiX®, generating a surgical guide (fig. 3) and a provisional (fig. 4) designed in the Straumann® CARES® Visual software and milled for placement after surgery.



#### Dr. Fernando Lopes

Dental Prosthesis Technician (1999), Dental Surgeon (2007)  
Specialist in Implantology (2015),  
ITI Member (2015)  
Speaker Digital Neodent Straumann (2017) and CEO Digital Center Lab

FIG. 1

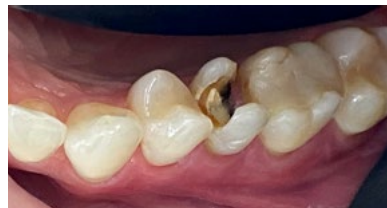

FIG. 2

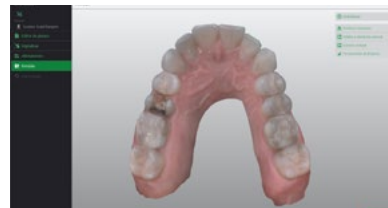

FIG. 3

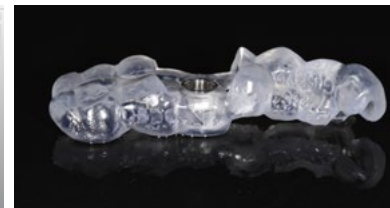

FIG. 4

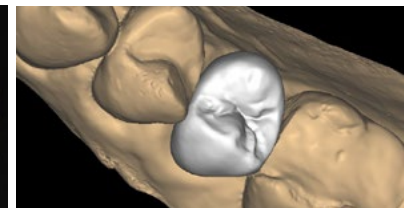


FIG. 5

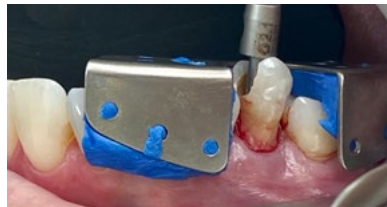

FIG. 6

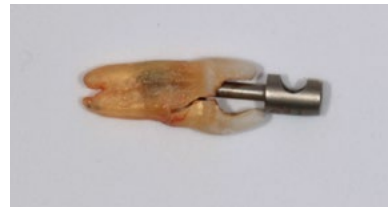

FIG. 7

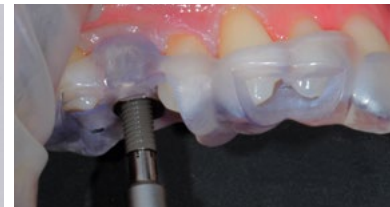
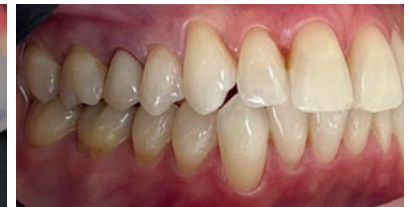
FIG. 8



## 2.3 GUIDED DENTAL IMPLANT

### PROCEDURE

Atraumatic removal with Neodent® tooth extractor (fig. 5 and 6), GM™ Helix 3.75 x 13 mm implant placement (fig. 7), universal abutment-supported provisional crown 3.3 x 6 x 2.5 (fig. 8).

After 45 days, the patient returned for the fabrication of the definitive prosthesis on tooth 15 and the onlay on tooth 16. Once the scanbody and preparation had been selected, a scan was taken with Virtuo Vivo™ (fig. 9), the restoration was designed in Straumann® CARES® Visual (fig. 10), the model was printed (fig. 11) and the parts were milled from Straumann® nice® blocks (fig. 12). Finished case (fig. 13 and 14).

FIG. 9

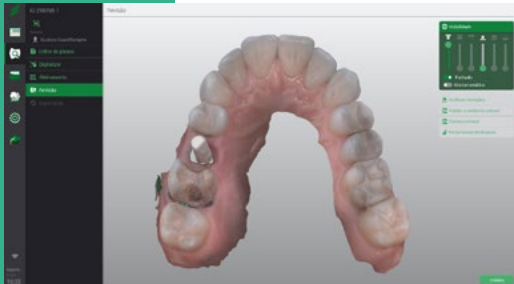

FIG. 10

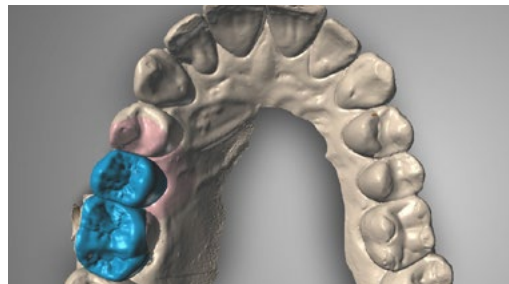


FIG. 11

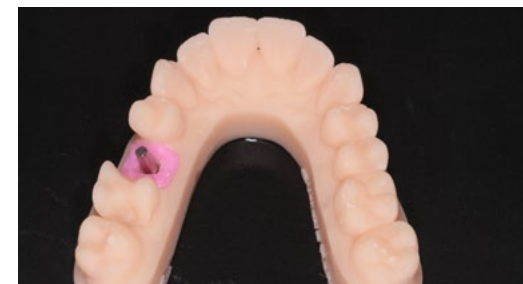

FIG. 12




FIG. 13

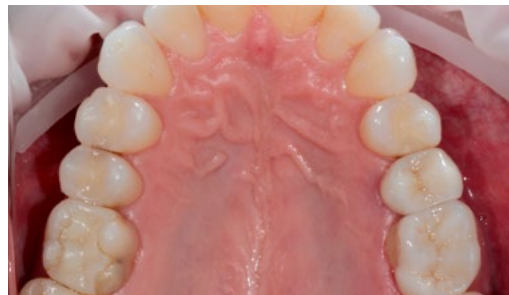
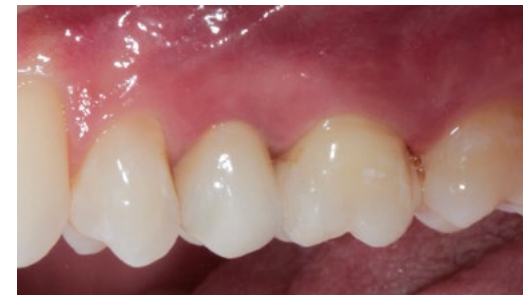
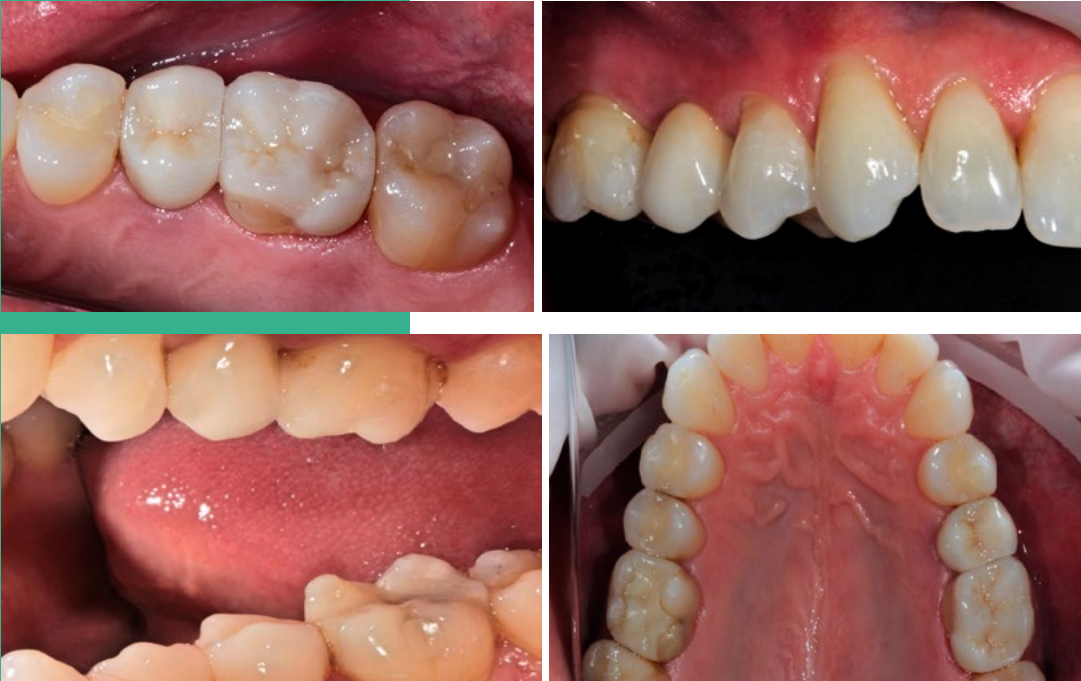FIG. 14



## 2.3 GUIDED DENTAL IMPLANT



### CONCLUSION

The procedure of placing the immediate implant after dental extraction preserves bone height and thickness, reduces treatment cost and time, and maintains gingival architecture, a crucial factor for the aesthetic success of the future prosthetic rehabilitation.

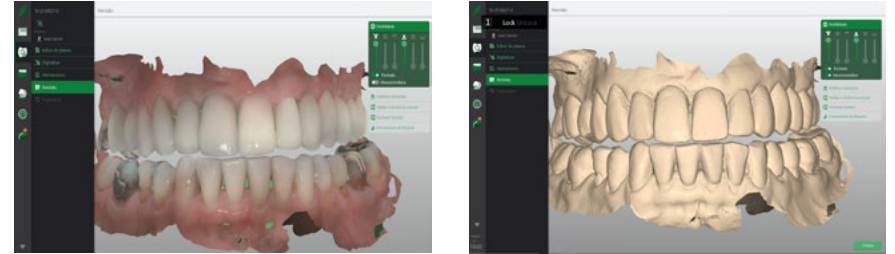
The use of technology involving tomography, scanner, planning software, printer and milling machines, allows more predictable dental procedures and reduces the risk of error.



# 2.4 MOUTHGUARD

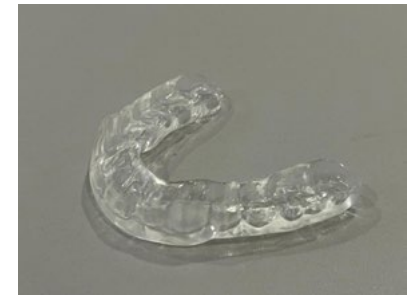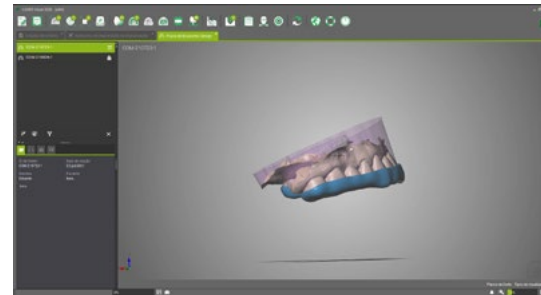
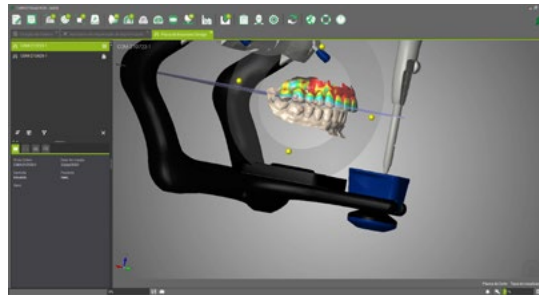
## CASE REPORT

Patient with ceramics on the entire set of upper teeth, requiring a mouthguard to increase the durability and preserve the prostheses. Scanning with Virtuo Vivo™ version 3.4.



## INTRODUCTION

We obtained an excellent result generating STL and PLY files without requiring opacification, even with various materials found in the mouth. The files were sent to the DLab Digital lab which used Straumann® CARES® Visual software to design and mill the mouthguard.



**Dr. Eduardo Romagna**

Specialist in Implantology

Master's in Implantology

Specialist Digital Dentistry at ILAPEO

Professor of Digital Dentistry

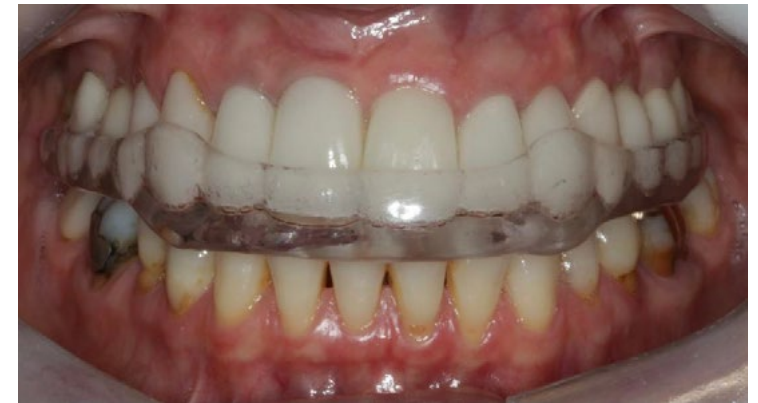## 2.4 MOUTHGUARD

### TREATMENT OUTCOME

Adaptation was perfect both in terms of occlusal contact and the smooth, vestibular, lingual and palatal areas, with only minor adjustment needed.

### CONCLUSION

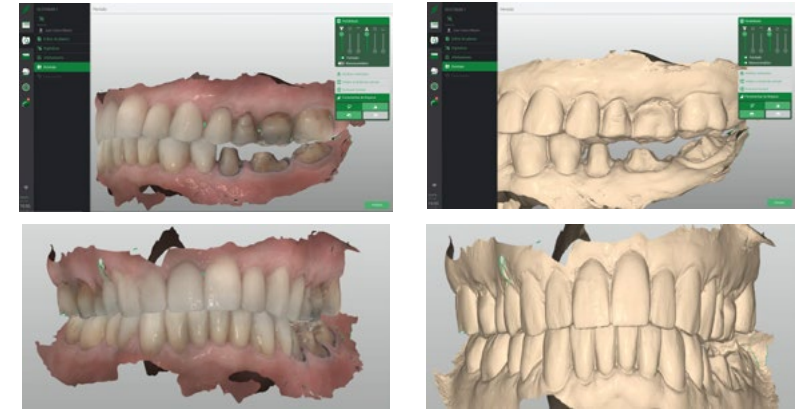
The combination of a bite record to determine prosthetic height and the Virtuo Vivo™ bite scan resulted in a smoother and more reliable workflow than could never have been achieved with analogue techniques, resulting in a precise outcome and enhanced practicality.



## 2.4.1 TOOTH-SUPPORTED MULTI-UNIT PROSTHESES

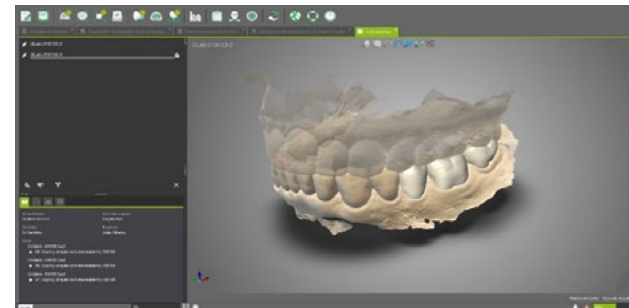
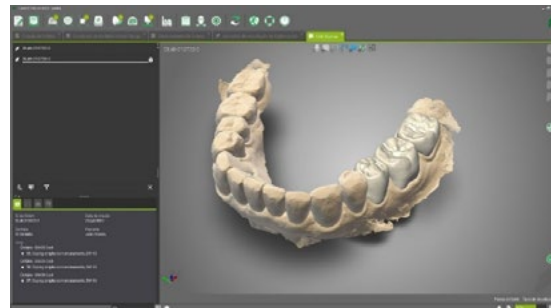
### CASE REPORT

The patient presented with anterior laminated prostheses in the upper and lower jaw, and underwent a process to replace the posterior prosthesis. Preparations were made and soft tissue was removed using a double-wire technique, where the scan was taken after the wire nearer the surface was removed, with the first wire remaining in place. The Virtuo Vivo™ version 3.4 was used for scanning.



### INTRODUCTION

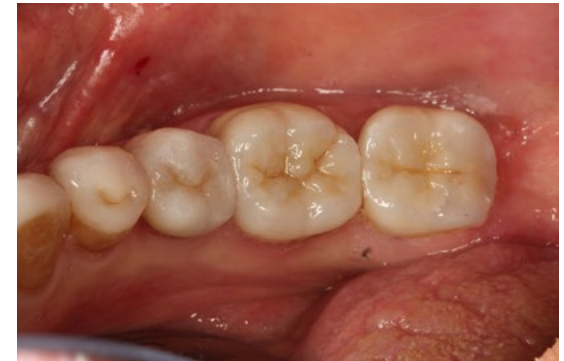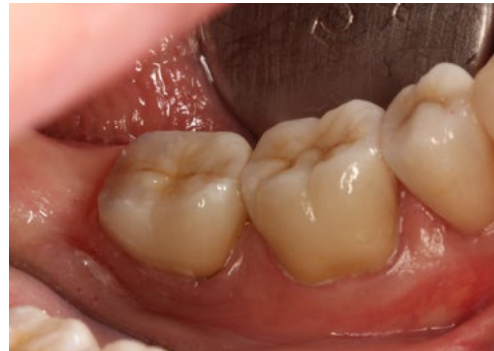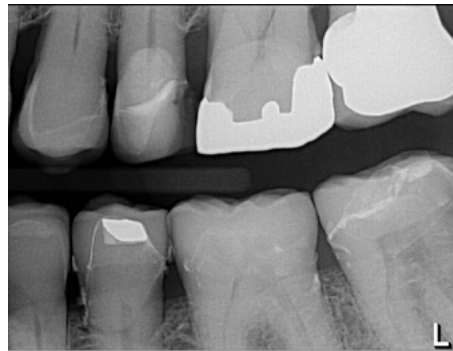
Planning was performed in the Straumann® CARES® Visual software by the Curitiba DLab Digital. The process was extremely quick, practical and seamless, even with different materials used in the mouth.



## 2.4.1 TOOTH-SUPPORTED MULTI-UNIT PROSTHESES

### SURGICAL PROCEDURE

The prosthesis was placed without the need for occlusal or proximal adjustments with perfect adaptation and an ideal cement margin.



### CONCLUSION

The Virtuo Vivo™ offers an excellent digital workflow experience, with perfect predictability and efficiency, even in the most complex of cases. It reduces clinical time, surgical operations and patient returns, offering great satisfaction to both me and the customer.



2.5

# GUIDED IMPLANT WITH IMMEDIATE **CUSTOMIZED** ABUTMENT AND TEMPORARY CROWN

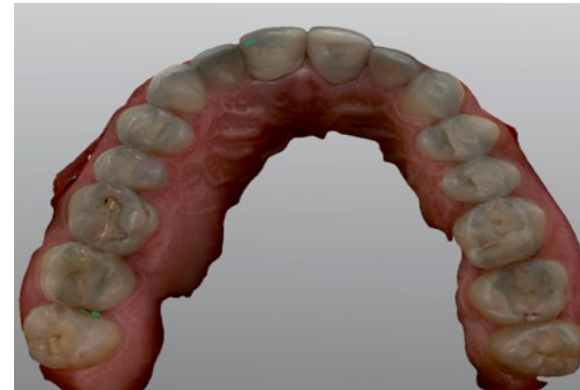
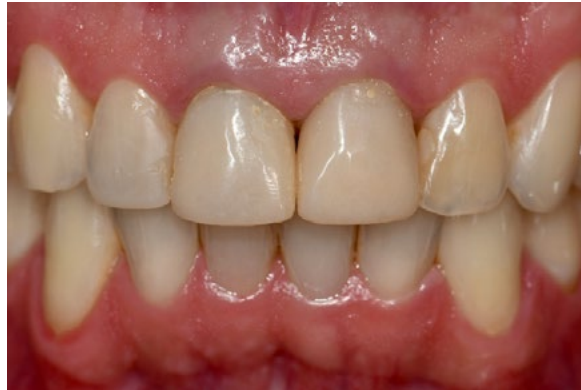
**Dr. José Cicero Dinato**

Oral Surgeon CV: PhD in implantology – UFSC Master in dental prosthetics – UNESP/SJC, Specialist in implantology and dental prosthetics – CFO, Chairman of the Academia, Gaúcha de Odontologia Neodent scientific consultant

### CASE REPORT

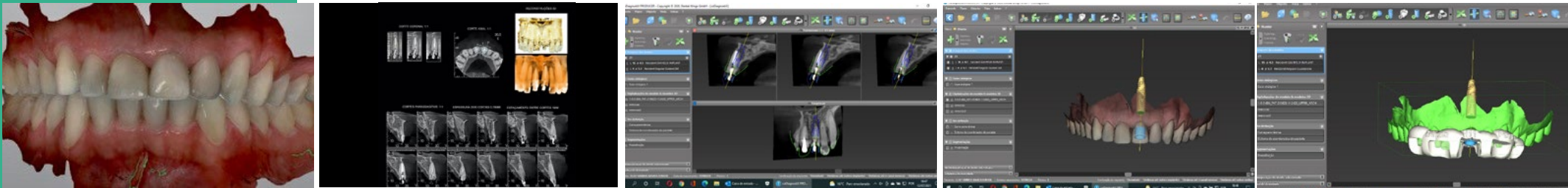
57 year-old male patient was referred by the Dinato Dentistry Clinic for upper left central incisor rehabilitation as he presented with external mesial root resorption. He presented at the practice with provisional crowns and pulp damage in both upper central incisors and metal core in 11. Healthy patient, ASA 1, with no organic, physiological, biochemical or psychiatric findings.



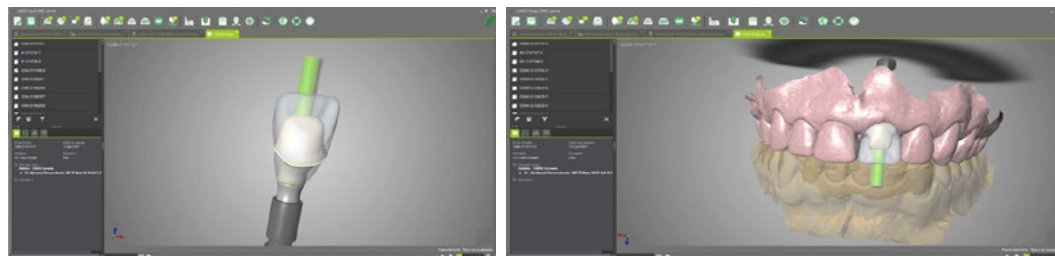
## 2.5 GUIDED IMPLANT WITH IMMEDIATE **CUSTOMIZED** ABUTMENT AND TEMPORARY CROWN

### PLANNING

In the first consultation, we took a periapical X ray of the region and a scan of both arches and an occlusal scan with the Virtuo Vivo™ scanner. We then requested cone-beam computerized tomography. The STL/PLY scanner files and the DICOM tomography files were entered into the coDiagnostiX® software for guided surgery planning and preoperative printing of the surgical guide on the Straumann® P40 printer.



As soon as we determined the position of the implant in the planning software, we were able to transfer this position to the Straumann® CARES® Visual software to design a customized abutment and temporary crown. Three STL files were generated for resin printing: maxilla, mandible and gingiva and 2 STL files for milling: provisional PMMA crown and zirconia abutment to be cemented into the titanium base.

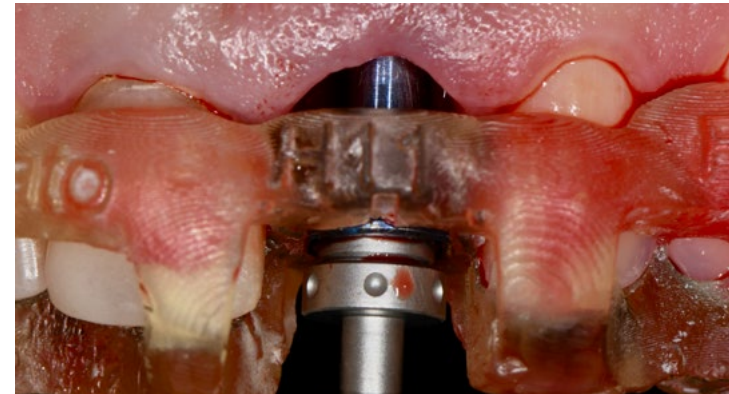
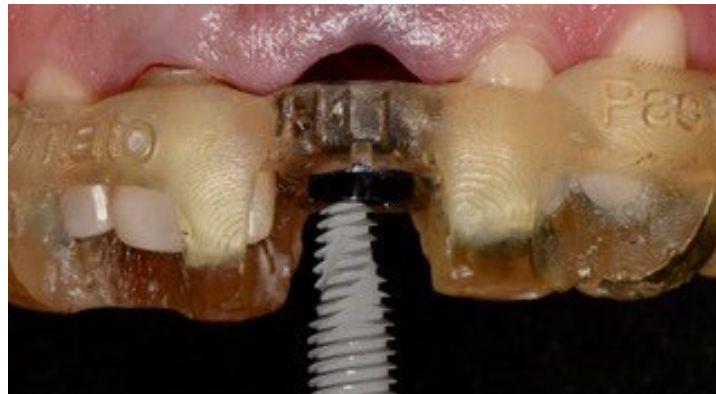

## 2.5 GUIDED IMPLANT WITH IMMEDIATE **CUSTOMIZED** ABUTMENT AND TEMPORARY CROWN

### PROCEDURE

During the first consultation we explained the pre- and post-operative care to the patient. We also prescribed a course of 14 x 875 mg amoxicillin tablets to be taken every 12 hours starting two days before the surgery and 100 mg of Nisulid to be taken every 12 hours for 3 days after the procedure, as well as paracetamol every 8 hours PRN for pain management.

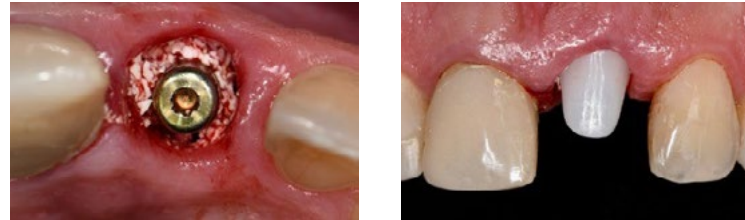At the second consultation, the procedure was carried out with local anesthesia using articaine hydrochloride 4% and epinephrine 1:100,000 and the root was removed with minimum trauma using the tooth extractor. Once the region had been debrided, the H11 surgical guide was placed using drill sequence 2, 3.5 and 4.3 mm in diameter from the Neodent™ GM® guided surgery kit, with 18 mm-deep instrumentation for placement of a GM™ Helix NeoPoros 4.3 x 16 mm implant.



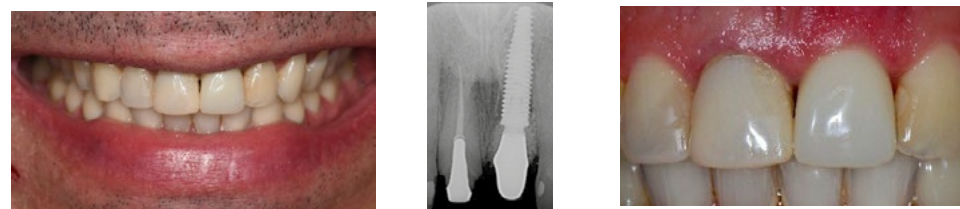## 2.5 GUIDED IMPLANT WITH IMMEDIATE CUSTOMIZED ABUTMENT AND TEMPORARY CROWN

### CONCLUSION

The implant exhibited excellent primary stability with a bond greater than 50 Ncm in bone type 2. The gap between the implant and the buccal bone plate was filled with Straumann® botiss Cerabone, a hydroxyapatite (HA) xenograft bone substitute. The surgery was flapless and sutureless and the zirconia abutment cemented onto the titanium base was screwed immediately after surgery, confining the graft in the alveolus. The provisional crown was adjusted to avoid compressing the elastic fibers in the gingival margin and to prevent antagonist teeth from touching in MIC and excursive movements.



The integration of the scanning software, virtual planning, CAD design, printing and CAM milling allows for highly predictable planning and execution of the surgery, while also enabling a customized prosthetic abutment and provisional crown to be manufactured prior to surgery. The patient is immediately rehabilitated post-extraction with the implant in the ideal position, optimizing the available bone and crown relationship, in addition to the personalized permanent abutment which follows the design of the zirconia gingival margin and temporary PMMA milled crown.



The psychological impact for the patient is extremely favorable because, despite the regrettable loss of the tooth, the patient spends only a few minutes without the crown. This is an example of what outstanding digital workflow precision combined with clinical expertise can offer patients.



## 2.6 ZIRCONIA IMPLANTS



### Dr. Bruno Matias

Graduate in Dentistry UNISANTA. Specialist in Implantology. Lecturer on the post-graduate implantology courses - UNIMES; Permanent Member of the GSPI, KOL Straumann, Expert in Digital Technologies



### Dr. José Marcio do Amaral

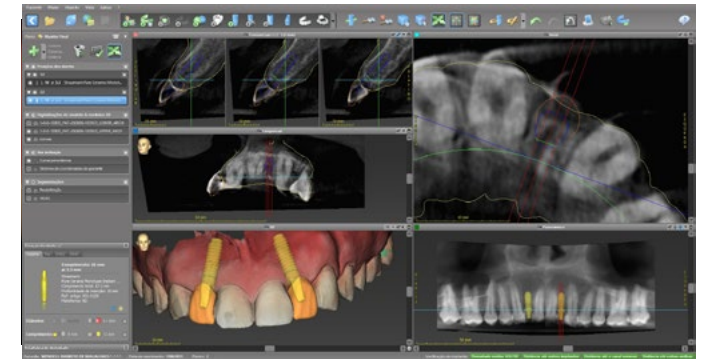
Master and specialist in Implantology-USC. Coordinator of Specialization in Implantology-UNIMES. KOL Straumann Expert in Digital Technologies

### CASE REPORT

Male patient with agnesia in teeth 12 and 22 looking for dental treatment to rehabilitate the missing teeth. After orthodontic treatment aimed at recovering the crown and radicular spaces, we proposed Straumann® PURE Ceramic zirconia implants as a rehabilitation option.

### PLANNING

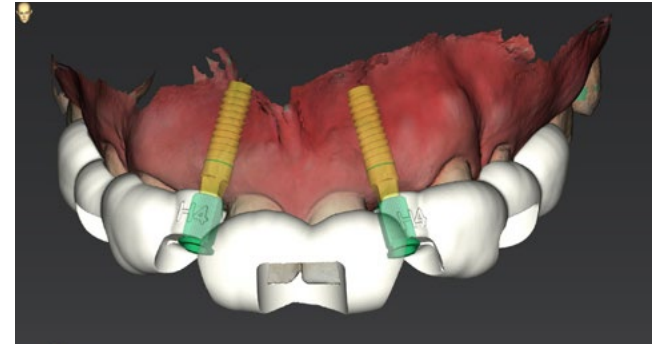
The surgical strategy took into consideration the small space between the roots of the adjacent teeth. To streamline the process, surgery was planned using the coDiagnostiX® software. To transfer the information generated in the planning, a surgical guide was printed to ensure ideal three-dimensional positioning of the implants, respecting the roots of the adjacent teeth and enabling prosthetic, aesthetic and functional rehabilitation.



## 2.6 ZIRCONIA IMPLANTS

### PLANNING

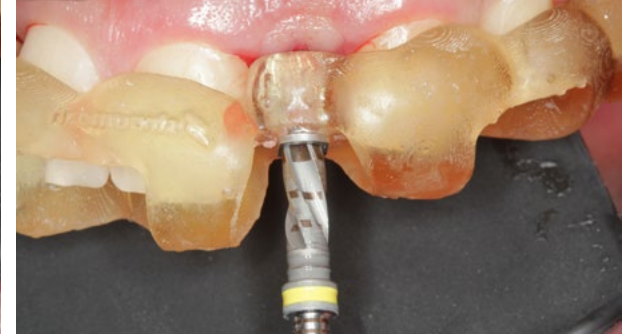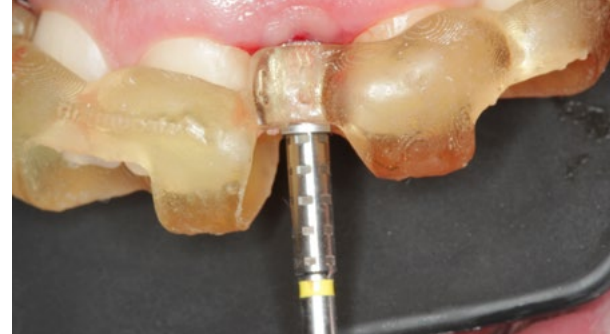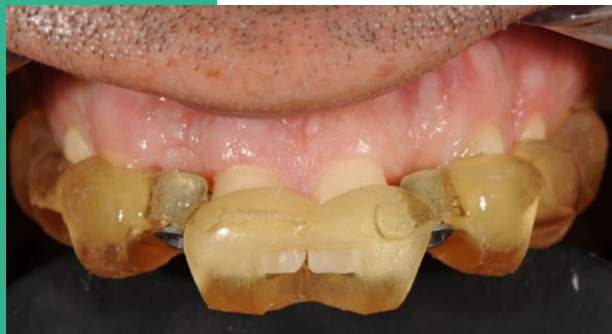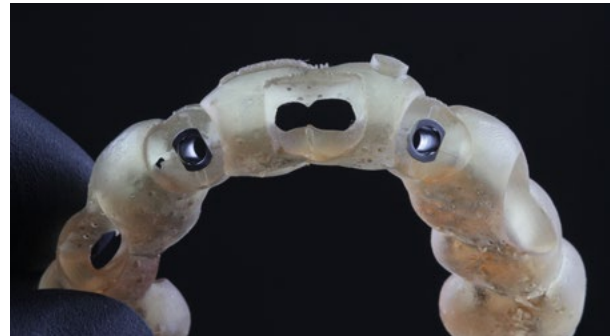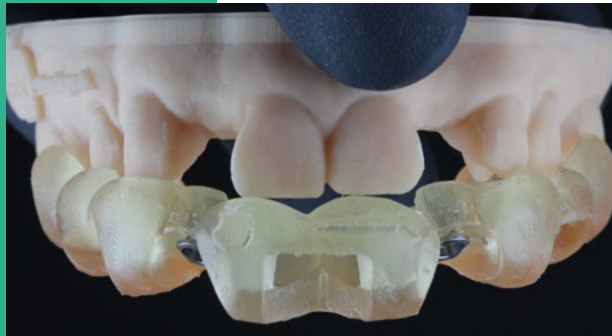1. Intraoral scanning with Virtuo Vivo™. This procedure will generate an STL or PLY file.
2. Computerized tomography will generate a DICOM file.
3. Virtual planning with coDiagnostiX® software will use the STL and DICOM files, enabling bone availability and prosthetic space to be analyzed.
4. Three-dimensional implant planning.
5. The provisional prosthetic crowns of teeth 12 and 22 were planned using Straumann® CARES® Visual software, respecting the virtual positioning of the implants. This procedure was only possible thanks to the Synergy integration software, which unified the surgical and prosthesis planning.



## 2.6 ZIRCONIA IMPLANTS

### PROCEDURE

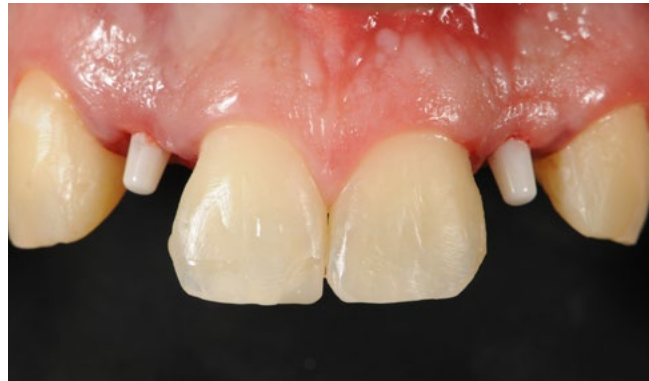6. Surgical guide and provisional teeth printing in P20 Printer.
7. Placement of the guide.
8. Sequential drilling with the VeloDrill™ drill line.



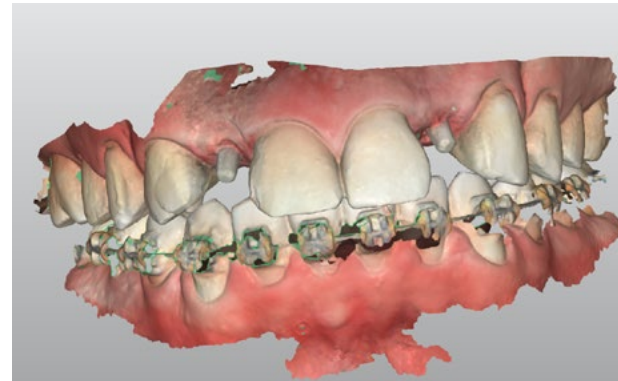
# 2.6 ZIRCONIA IMPLANTS

## PROCEDURE

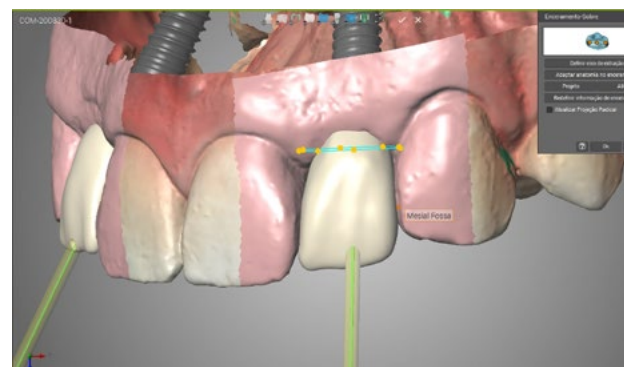
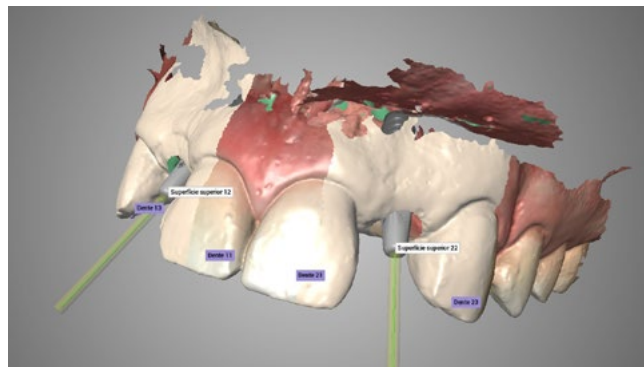
### 9. Implant placement



IMMEDIATE SURGICAL RESULTS



POST-SURGICAL SCANNING



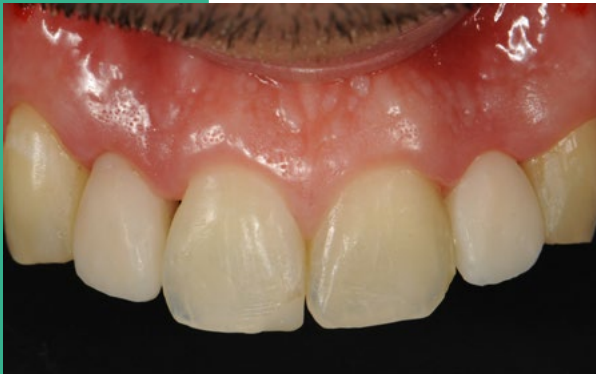PREPARATION IN STRAUMANN® CARES® VISUAL SOFTWARE



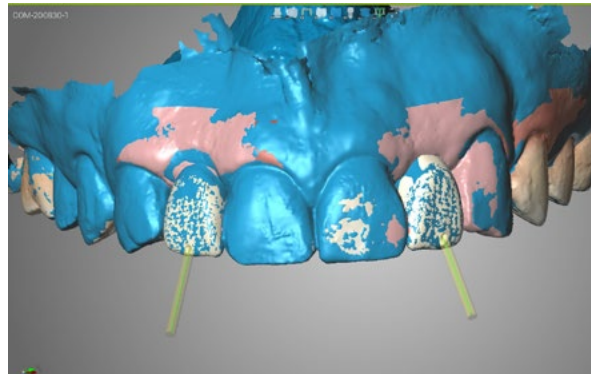
## 2.6 ZIRCONIA IMPLANTS

### PROSTHETIC PROCEDURE

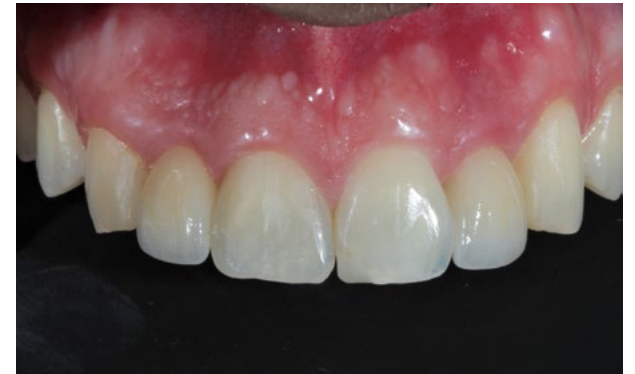#### 10. Prosthetic crown insertion



PROVISIONALS INSERTED AFTER PRINTING ON THE STRAUMANN® P20 PRINTER AND A1 YLLER RESIN



AFTER 42 DAYS, RESCANNING AND PREPARATION IN STRAUMANN® CARES® VISUAL USING THE COPY TOOL



FINAL RESULT OF THE MILLED CROWNS IN EMAX CAD A2

## 2.7 IMPLANT-SUPPORTED CROWN AND VENEERS

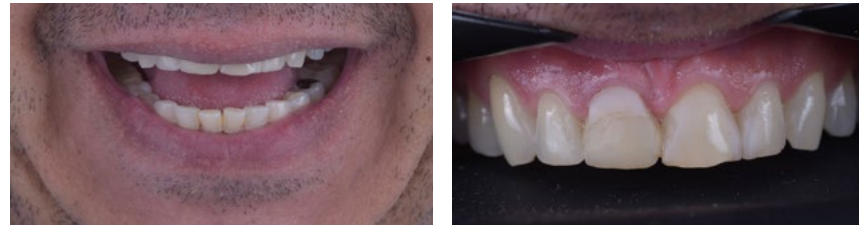### CASE REPORT

52-year-old patient, RL, with a BLT Roxolid® SLActive® Ø 3.3 x 12 mm implant placed in 11, with screw-retained provisional on the implant and emergence profile and ready to carry out the definitive restoration. After analyzing the case a decision was made to place 1 implant-supported crown in tooth 11 and porcelain veneers in teeth 12, 21 and 22.



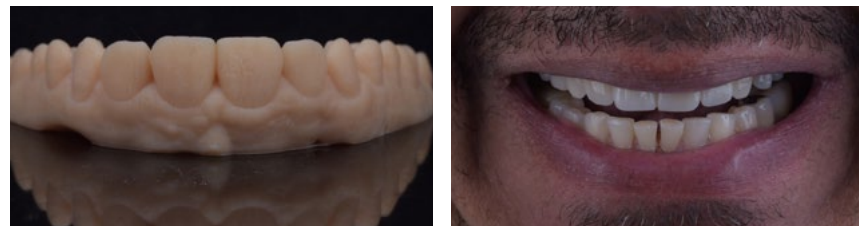
#### Dr. Fabio Persegani

Specialist in dental prosthesis at ABO Caxias; Master in dental prosthesis at UERJ; Postgraduate in dental implants and periodontal plastic surgery; Postgraduate in botulinum toxin and facial filling



### PLANNING

To plan the treatment, an initial scan was taken with Straumann® Virtuo Vivo™ for digital wax-up and subsequent model printing on Straumann® P20+ in Straumann® P pro Dark Beige to make the mock-up.

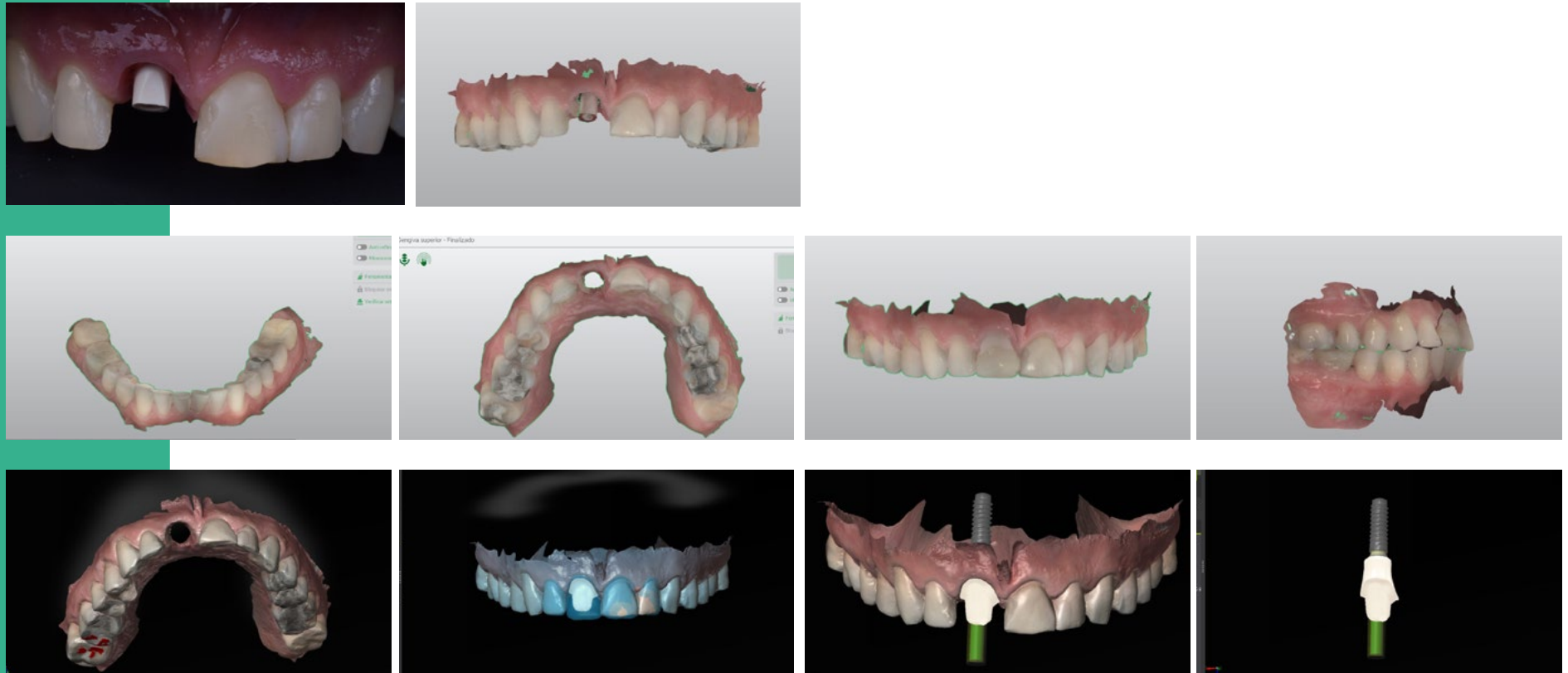


# 2.7

## IMPLANT-SUPPORTED CROWN AND VENEERS

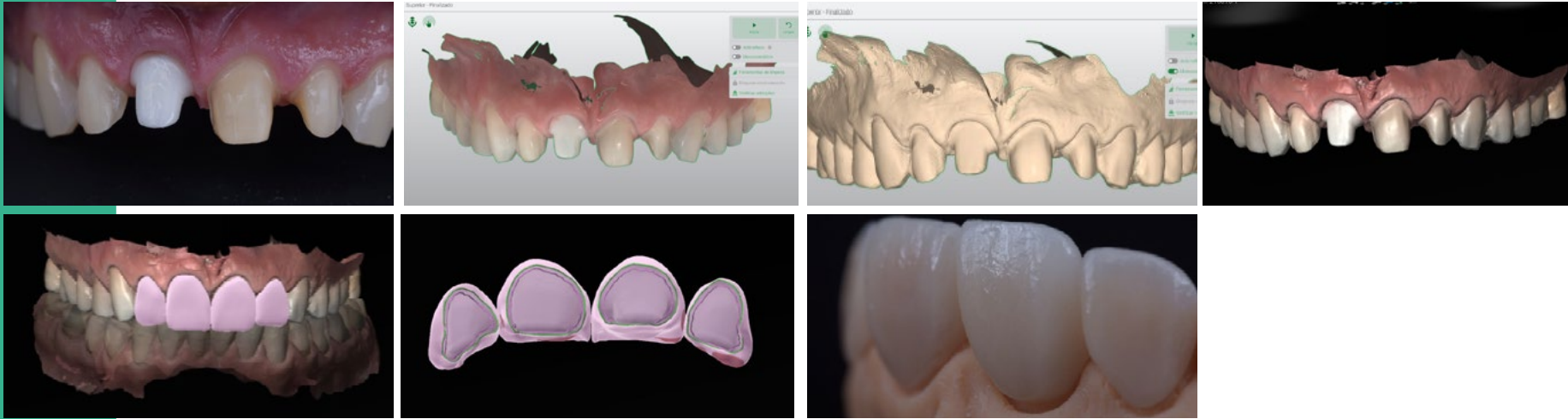
### PROCEDURE

The implant was scanned according to the approved plan using a Straumann® CARES® Mono Scanbody for the zirconia abutment. This was designed in the Straumann® CARES® Visual software and sent for manufacture at the Diabdigital lab.



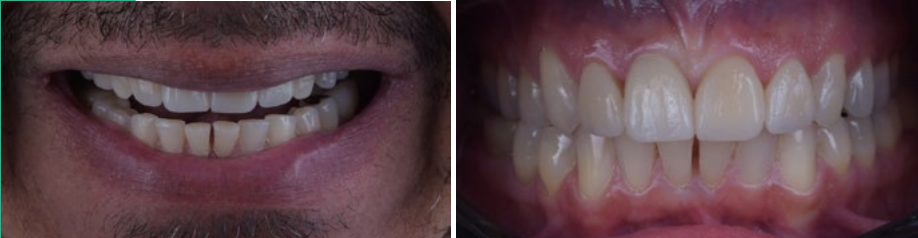## 2.7 IMPLANT-SUPPORTED CROWN AND VENEERS

With the abutment already placed on the implant, the preparations were carried out and scanned with the Straumann® Virtuo Vivo™ for the definitive restorations; these were also designed in the Straumann® CARES® Visual software and milled in the Straumann® C series in IPS e.max® CAD MT (Ivoclar Vivadent) made of lithium disilicate and then finished off with MiYO Esthetic (Odontomega).



### CONCLUSION

Restorations were cemented with Variolink® Esthetic resin cement in "Warm".



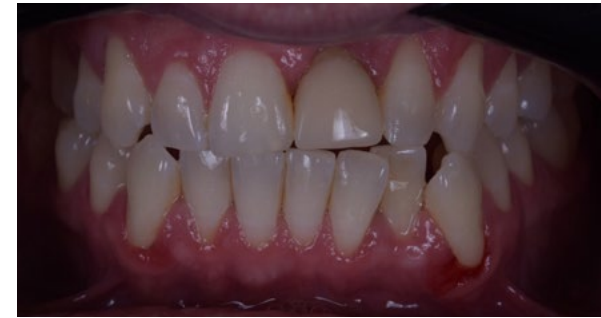
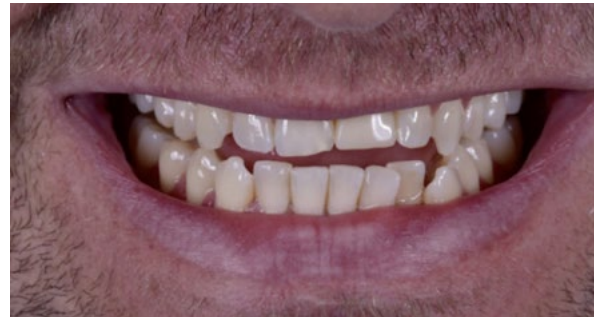
# 2.7.1

## CLEARCORRECT® ALIGNERS AND VENEERS

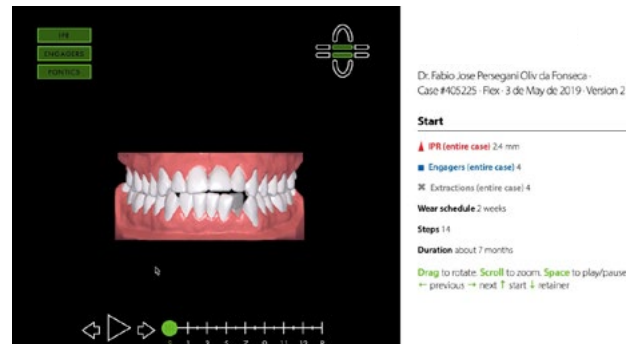
### CASE REPORT

35-year-old patient already presented with a CM implant in 21, with a cement-retained universal abutment-supported provisional. The patient also presented with severe misalignment of the anterior teeth in the mandible with a supernumerary lower incisor and malpositioned canines. After analysis, ClearCorrect® aligners were selected to improve the relationship between the arches, and the supernumerary tooth was removed.



### PLANNING

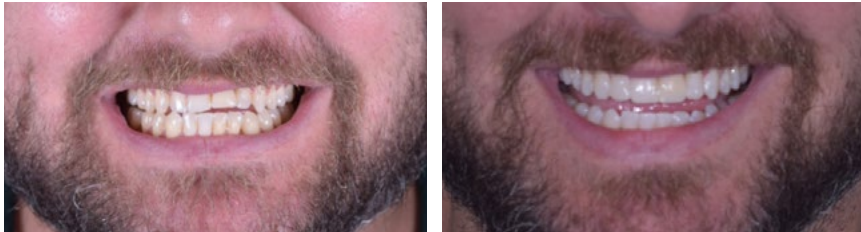
After uploading the data onto the ClearCorrect® platform and virtual set up, 14 aligners were manufactured for the patient.



## 2.7.1 CLEARCORRECT® ALIGNERS AND VENEERS

### PLANNING

After the aligner treatment, another scan was taken for virtual planning and mock up, where 3 laminate-type ceramic restorations were planned on teeth 12, 11 and 22, as well as the implant-supported crown on tooth 21.

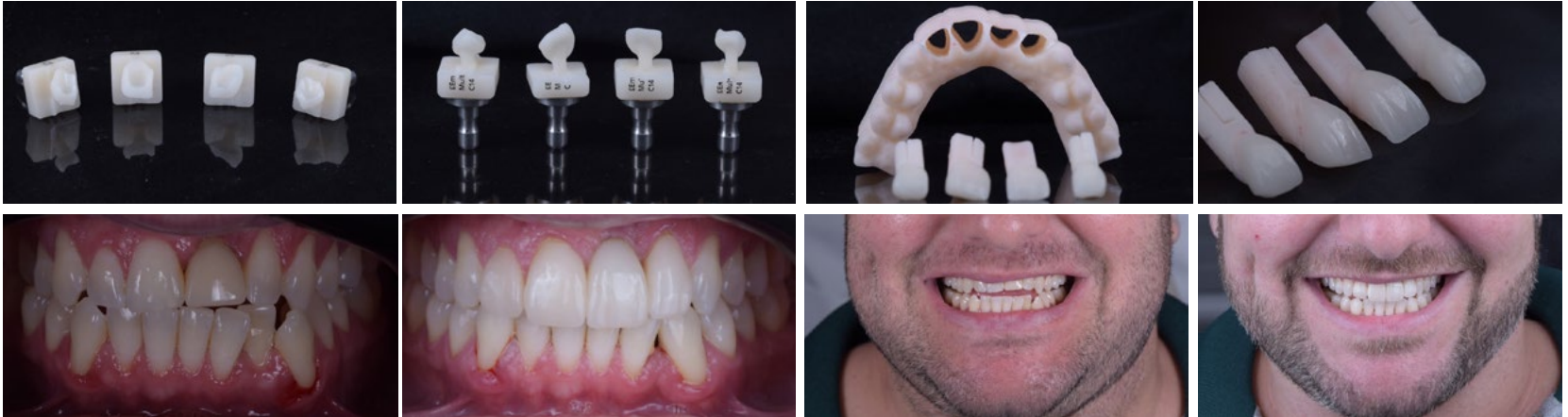

FOLLOW-UP TREATMENT WITH CLEARCORRECT®

MOCK UP

### PROCEDURE

The preparations were scanned with Straumann® Virtuo Vivo™ while the restorations were designed in the Straumann® CARES® Visual software and milled in the Straumann® C series in Empress multiblock A1 (Ivoclar Vivadent). The working models were printed on the Straumann® P20+.





The procedures presented here were performed by experienced dentists who bear full responsibility for the accuracy of the information and the procedures and results reported. Any revision, dissemination, distribution, copy or other use of this information by persons or entities is forbidden without prior written authorization. The material presented may be subject to review without prior notice. No responsibility is accepted for any errors or omissions in the content. It is the exclusive responsibility of the practitioner to assess the patient's health and treatment viability. The reproduction of these clinical cases does not imply the success of the treatment, as this will depend on the ability and expertise of the clinician as well as the health and compliance of the patient during the treatment.