



Straumann® BLX

# QUINTESSENCE Special Issue 2019

 QUINTESSENCE PUBLISHING

EXCELLENCE IN IMMEDIACY

# Straumann® BLX Confidence beyond Immediacy.



## DYNAMIC BONE MANAGEMENT

Makes immediate protocols achievable and predictable in all bone types.



## ESTHETIC EASE CONCEPT

One connection and under-contoured prosthetics to deliver esthetics with ease.



## REAL CONFIDENCE

Straumann solutions you can depend on and that are predictable in all clinical situations.



Contact your local Straumann representative  
or visit: [www.confidence-in-you.com](http://www.confidence-in-you.com)

# EDITORIAL



As is often the case, our editorial team is happy to leave the orders for a special issue of Quintessence to the industry. Since the Sunshine Act, partnerships with industry have often been viewed negatively. No one can deny the importance of regulating the links of interest between health professionals and industrialists. However, it is essential to remember that industry plays a particularly important role in the development of new technologies, which obviously need to be validated upstream by independent studies. In my view, Straumann is one example of the virtuous side of this type of partnership, which when it is concluded with the press generates benefits for practitioners by changing their daily clinical practice for the benefit of their patients.

In this issue, I am pleased to give Straumann the opportunity to present its products and innovations through a selection of articles whose quality of iconography and clinical treatments are in the spirit of Quintessence.

As you have noticed, 2019 is an important year for the Quintessence group: we celebrated our seven decades of experience. For the past seven decades, Quintessence Publishing has brought you cutting-edge dental education journals of the highest quality. Now in time for our 70-year jubilee, we have modernized the layout of our journals. The proven content quality and topicality is unaltered; what is new are the creative covers, easy-to-read and concise layouts, and more brilliant images. In this way we help dentists worldwide to provide their patients with the best possible care.

We are also proud to offer the reader a unique experience through augmented reality. The contribution of videos through this technology is a great asset in dentistry to capture all the subtleties of the treatments presented. I encourage you to download the application and enter this new dimension.

I wish you all a very pleasant reading!

**“ INDUSTRY PLAYS  
A PARTICULARLY IMPORTANT  
ROLE IN THE DEVELOPMENT  
OF NEW TECHNOLOGIES ”**

*Christian W. Haase,*  
CEO of Quintessence Publishing

EXCELLENCE IN IMMEDIACY

Straumann® BLX

Confidence beyond  
Immediacy.



Straumann® BLX, the winning combination of innovative design and surface technology with high-performance material for predictable outcome with results you can trust.



Contact your local Straumann representative  
or visit: [www.confidence-in-you.com](http://www.confidence-in-you.com)



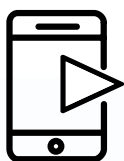# Augmented Reality in this Special Issue !

This issue features augmented reality videos accessible free of charge from your smartphone or tablet. Easy, reliable, fast and offline, discover the videos selected for you by the authors to enrich your reading experience.



## Download

the "*Quintessence special*" application on the Appstore (iOS) or Google Play (Android).

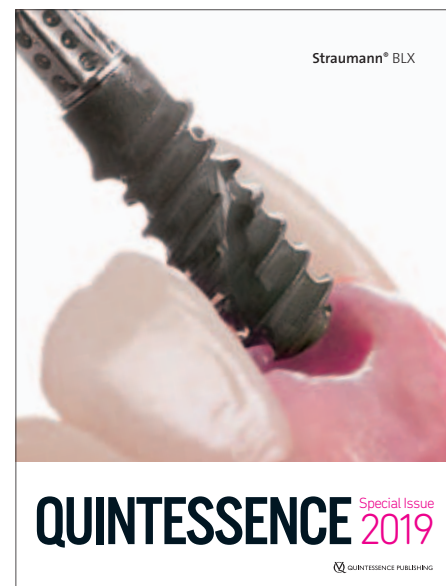

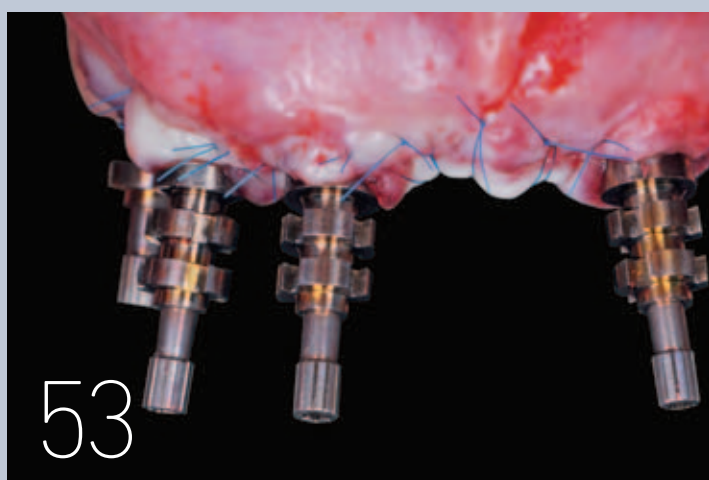
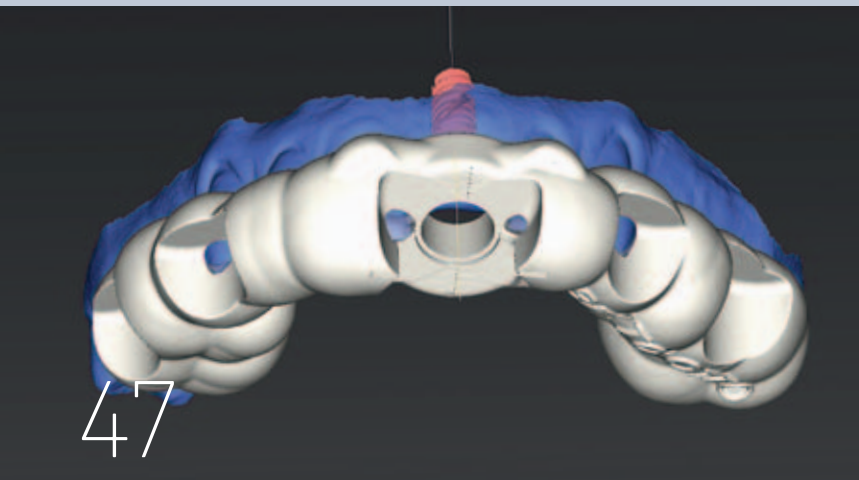
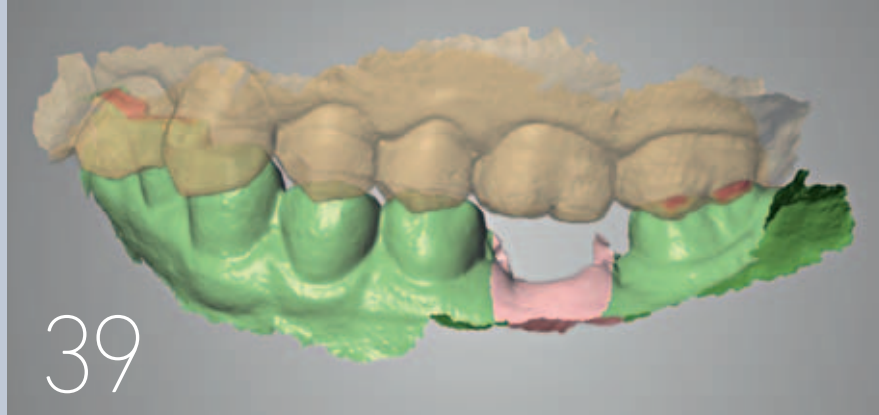
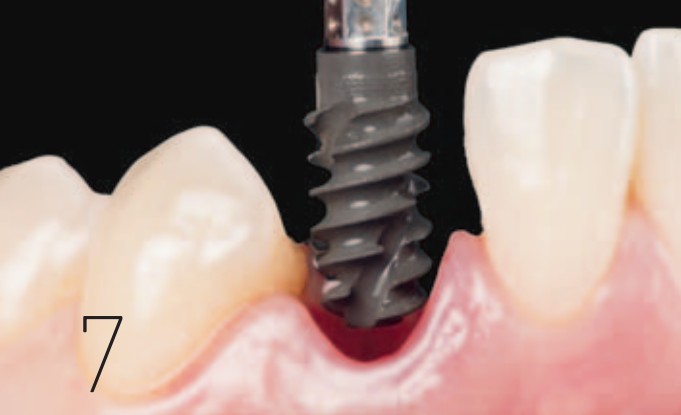## Locate

photographs and advertisements with the augmented reality pictogram.

## Fly over

these images with your smartphone or tablet from the application to play the videos.





## TABLE OF CONTENTS

QUINTESSENCE  
SPECIAL ISSUE 2019

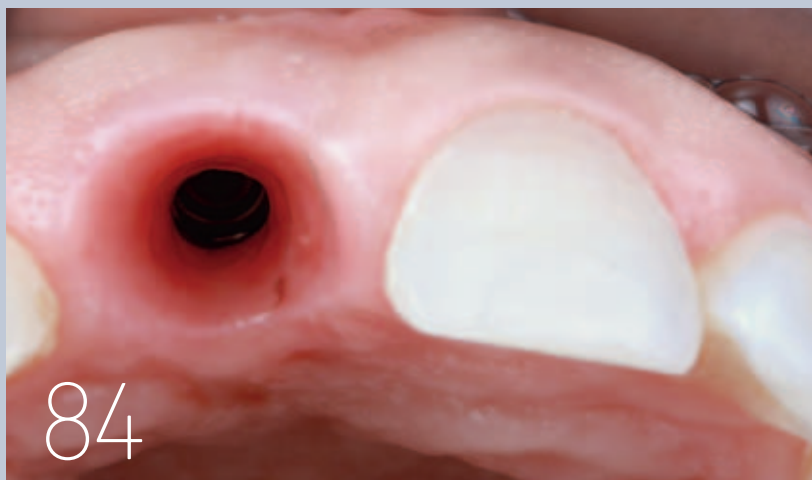
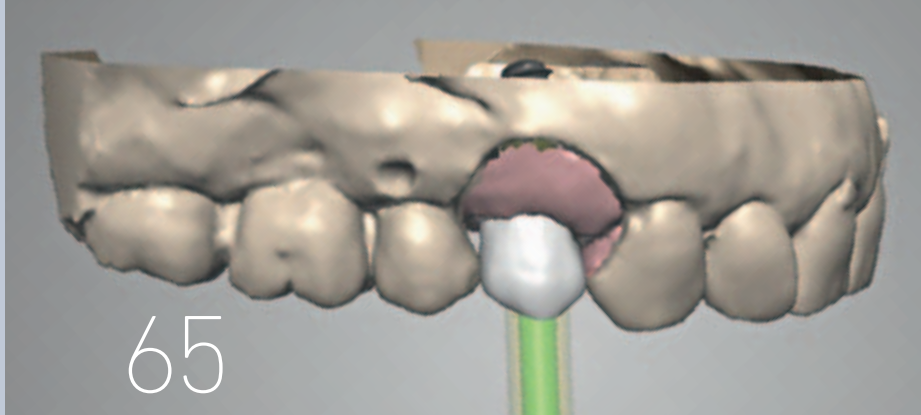
**BLX**  
New generation  
of implants

Cover picture:  
© Léon Parienté

### 1 Editorial

Christian W. Haase

- 7 **BLX / A new generation of self-drilling implants**  
Ophir Fromovich, Karim Dada, Léon Parienté and Marwan Daas
- 39 **BLX / Immediate Loading in Single Crowns Using Straumann BLX and a Digital Workflow**  
One-Tooth One-Time technique description – Clinical case collection  
Louwrens Swart, Paul Van Zyl, Christian Jarry, Diana De Macedo and Hugo Madeira
- 47 **BLX / Replacement of a fractured central incisor with post-extractive BLX implant positioning and immediate prosthesis**  
Sergio Piano
- 53 **BLX / Use of BLX implants for immediate loading protocol in a full arch rehabilitation**  
Antoine Popelut, Jérôme Leclair, Pascal Marseille and Guillaume Reny



10 years of  
**SLActive®**

65 **BLX / Immediate implant placement**  
with immediate loading following extraction  
of natural teeth and cystectomy of adjacent tooth

Alessandro Perucchi, Christian Monti, Serena Pedrazzini and Jessica Dana

72 **SLActive® / 10 years of SLActive®**  
**Meeting with Professor David Cochran**

Interview conducted by Daniela Albu

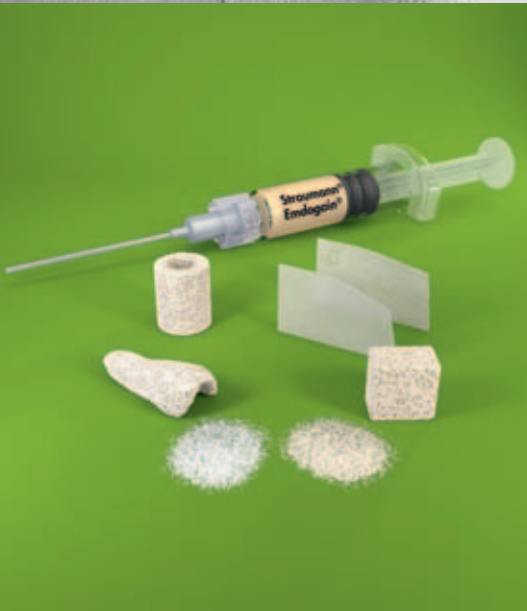74 **SLActive® / Dental implant surfaces**  
**Nanostructures enhance osseointegration**

Michel M. Dard and Raphael S. Wagner

84 **SLActive® / Mastering the emergence profile**  
**At the heart of the image**

Sherif Said

# ESTHETIC DENTISTRY



Straumann® Biomaterials

## Match any challenge.

Decades of experience in dentistry and oral regeneration propelled us to understand and meet the diversity of needs, indications and preferences. The right solution in implantology and periodontology is designed to fit the individual. Straumann offers an exceptional range of biomaterials that meet your expectations and those of your patients.



Contact your local Straumann representative  
or visit: [www.straumann.com](http://www.straumann.com)



# BLX: a new generation of self-drilling implants



## OPHIR FROMOVICH

Private practice, Israel.  
Inventor of many implant systems  
and restorative implant parts.



## KARIM DADA

DDS, Paris Descartes  
University, France.  
Private practice, Paris.

📧 [62ltm@orange.fr](mailto:62ltm@orange.fr)



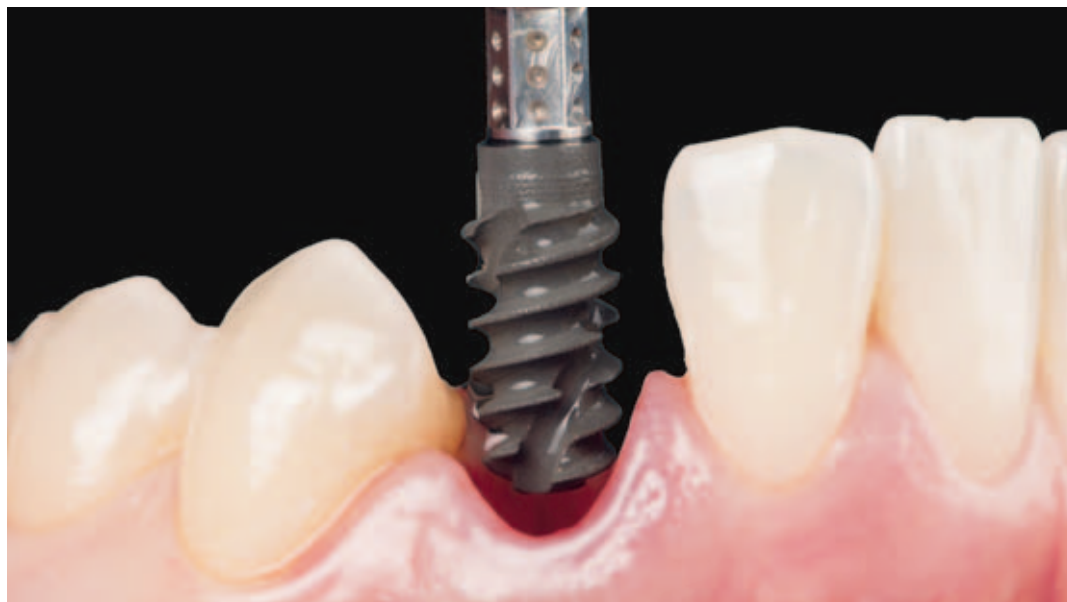## LÉON PARIENTÉ

Advanced Program for  
International Dentists in Implant  
Dentistry at the NY University  
College of Dentistry.  
Private practice, Paris.



## MARWAN DAAS

Lecturer in prosthodontics and  
implant dentistry, Paris Descartes  
University, France.



Osteointegration, as described by the founding fathers of modern implantology in the 1980s, involves a direct and functional connection between the surface of an implant and the living bone. Since the 1980s, two models have been developed. “Bone Level” implants, with external connection and a smooth surface, are intended to be placed in two surgical steps and result from the work of P.I. Branemark; “Tissue Level” implants, developed by Schröder’s team, have a rough surface and are placed in one surgical step.

The formation and maintenance of this osteointegration are crucial to the survival of the implant. Thirty years later, driven by the first results obtained, the success of these implants is defined by ever more precise criteria, from marginal bone loss to the perfect aesthetic integration of the prosthesis.

These requirements of patients and practitioners translate to a healthy daily race forward for research and industry to obtain ever more reliable medical instruments and devices. Technological advances in materials science, nanotechnology, mechanics and biomechanics, as well as advances

in our understanding of biological phenomena, have made it possible in recent years to market dental implants that provide an ever-expanding range of options for the treatment of our patients.

However, today, the success and even the survival of our implants, though previously taken for granted, seem to be called into question by the rise of peri-implantitis.

While the scientific community unanimously agrees on the good long-term performance of “Tissue Level” implants with rough surfaces as defined in Schröder’s original work, there has been an increase in the number of case reports involving peri-implant complications related to the combination of “Bone Level” implants and rough surfaces. This combination is far from the original work of Branemark, which advocated for the use of a smooth surface with this type of implant (or at least for implants with an external connection).

However, “Bone Level” implants are fully justified in all cases with an aesthetic impact, in patients with fine biotypes, and in the maximum use of residual bone in the perisinus region, for example. Finally, a return to a smooth surface

would constitute a significant step backwards in terms of operating protocols, particularly in all cases of immediate implant placement in fresh extraction sockets, immediate loading, or when a bone regeneration technique is to be applied simultaneously with the implant placement.

The nature of the connection and the way in which the biological space is established therefore seem to be decisive factors in protecting the rough implant surface from such complications.

In this context, it is therefore essential to define the conditions for the success of a "Bone Level" implant and to eliminate any combination that could lead to contamination of the implant surface.

The gold standard of the "Bone Level" implant can today be defined as an implant which, when placed in accordance with the data acquired from science, allows for optimal respect of the biological space thanks to its neck and connection. The connection of the prosthetic elements is moved towards the center of the platform: this "platform switching" combined with a sealed Morse taper connection makes it possible to limit the inflammatory zone of the microgap and move it away from the bone.

Around this connection is a smooth surface that is directly exposed to the soft tissue to form the horizontal component of the biological space, and a rough osteoconductive surface that is placed in contact with the bone along the implant. The biomechanical characteristics of the design of the body and apex of the implant must allow for significant primary anchorage, and dynamic bone management in the different density types, as well as optimal evacuation of the stress induced by this design intended to increase the stability of the implant, particularly in cortical areas, which are extremely sensitive to resorption phenomena.

For the "BLX" implant, significant progress has mainly been made in relation to these three points.

The advantages of improved primary stability are not only limited to the aesthetic or immediate loading possibilities. In all indications, from the most extreme to the most common, a direct

correlation between initial implant stability and the phenomenon of osseointegration has been demonstrated. This is especially true for all low bone density sites, where it is often difficult to achieve satisfactory primary stability. These include the posterior sub-sinusal maxillary areas, whether the chosen solution is short implants, angulated implants along the sinus, or a simultaneous approach with a sinus floor elevation procedure, and grafted, regenerated sites, on the day of extraction or after mucosal healing, in the maxilla or mandible.

## THE EVOLUTION OF IMPLANT DESIGNS

In this biomechanical research on increased primary stability, several designs have been proposed:

- a parallel-pitch design, naturally coupled with simple and efficient drilling that has the advantage of being flexible in terms of vertical positioning, but does not allow significant primary stability to be achieved in low-density bones and extraction cavities;
- a completely tapered design, the drilling of which is much more demanding and where the positioning of the implant does not allow for any errors. For this solution, the number of drills required is much higher since one drill is required for each implant length and implant diameter available;
- a hybrid design parallel on the coronal portion of the implant and tapered on the last 5 mm of the apex. This combination has the advantage of benefiting from the design of parallel-pitch implants for flexibility between drilling and implant positioning, as well as that of tapered design implants for their increased primary stability and their ability to be used when one of the implant bed walls is deficient (bone defect, fresh extraction sockets, etc.)
- more recently, a conical design with more aggressive threads with the ability to cut bone has emerged.

These latter "self-drilling" implants have quickly gained the favor of practitioners in the management of certain situations such as the immediate placement of implants in an extraction socket where the ability to obtain primary anchorage is crucial to the success of the procedure. However, due to their aggressive design, these implants have not proven very effective in D1 or D4 bones. In areas of low density, cutting capacities were too high in relation to the compaction effect induced by the conical design of the implant, and this usually led to a total loss of the primary anchorage. In areas of high density, on the other hand, high

stress frequently required a significant increase in the drilling sequence to avoid spontaneous fractures in the buccal cortical bone due to the previously insufficient ability of these implants to dissipate the stress caused by their insertion. The "BLX" implant represents the latest generation of "self-drilling" implants, and the main progress made has been in dynamic bone management and the limitation of stress suffered by the implant's direct environment, allowing the implant to offer greater flexibility for the user while preserving the ability to obtain predictable primary anchorage, even when bone quality varies.

### THE BLX IMPLANT IN DETAIL (Fig 1)

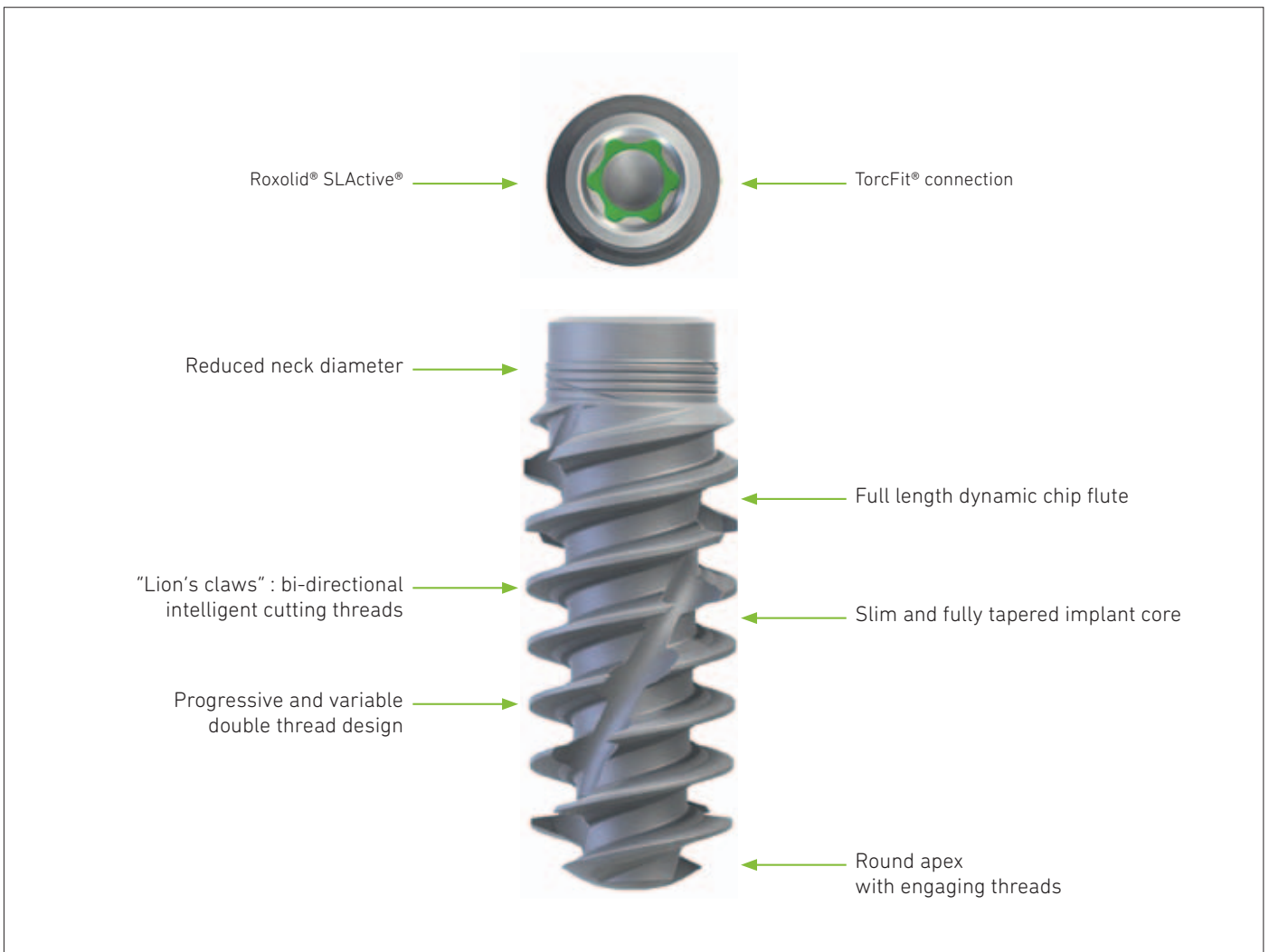



Fig. 1 Features of the BLX implant.



**Fig. 2** Rounded apex of the BLX implant; two sharp and highly engaging threads are located close to each other to facilitate implant insertion.

### Apical portion

The first characteristic of this “self-drilling” implant is its rounded and softened apex, which provides better protection against anatomical obstacles: mandibular nerve, maxillary sinus or converging dental roots. To allow this implant to engage the surrounding bone tissue, the end of the implant is quickly surrounded by wide threads which also give it the property and make it possible for the operator to control the direction of insertion during implant placement (**Fig. 2**).

### Design of implant threads


The BLX implant is set with double threads whose spacing and width vary according to their position on the implant, but also according to the length of the implant itself. This unique design allows for efficient and fast insertion. It also provides ideal primary stability in all types of bone through uniform and controlled compaction and densification of the peri-implant bone. Finally, this design was created to obtain optimized insertion torque values that guarantee ideal primary stability and maximum dissipation of stress from the peri-implant bone (**Fig. 3 and 4**).

### Core portion

The BLX implant has a narrow conical central portion of two different diameters: 3.5 mm for RB implants and 4.5 mm for WB implants. It is precisely this narrow implant body coupled with the progressive design of the threads that limits insertion constraints and the stress delivered to the surrounding bone tissue, even in the case of a relatively small osteotomy (**Fig. 5**).

### Cutting capacity of the threads

It is these secant threads that give the BLX implant its unique capabilities. Of course, their ability to engage bone tissue allows for significant primary stability, but the fact that these threads are sharp in both directions also allows for significant relaxation of the insertion torque when the implant is unscrewed. With this property, the use of a tap is no longer necessary since, in addition to a drilling sequence appropriate to the situation, it is the implant itself that acts as the last instrument in the operating sequence (**Fig. 6**).



**Fig. 3** Detail of the double thread of the BLX implant.



Fig. 4 The BLX implant is available in RB (Regular Base) configuration with a 3.5 mm diameter body and WB (Wide Base) with a 4.5 mm diameter body.

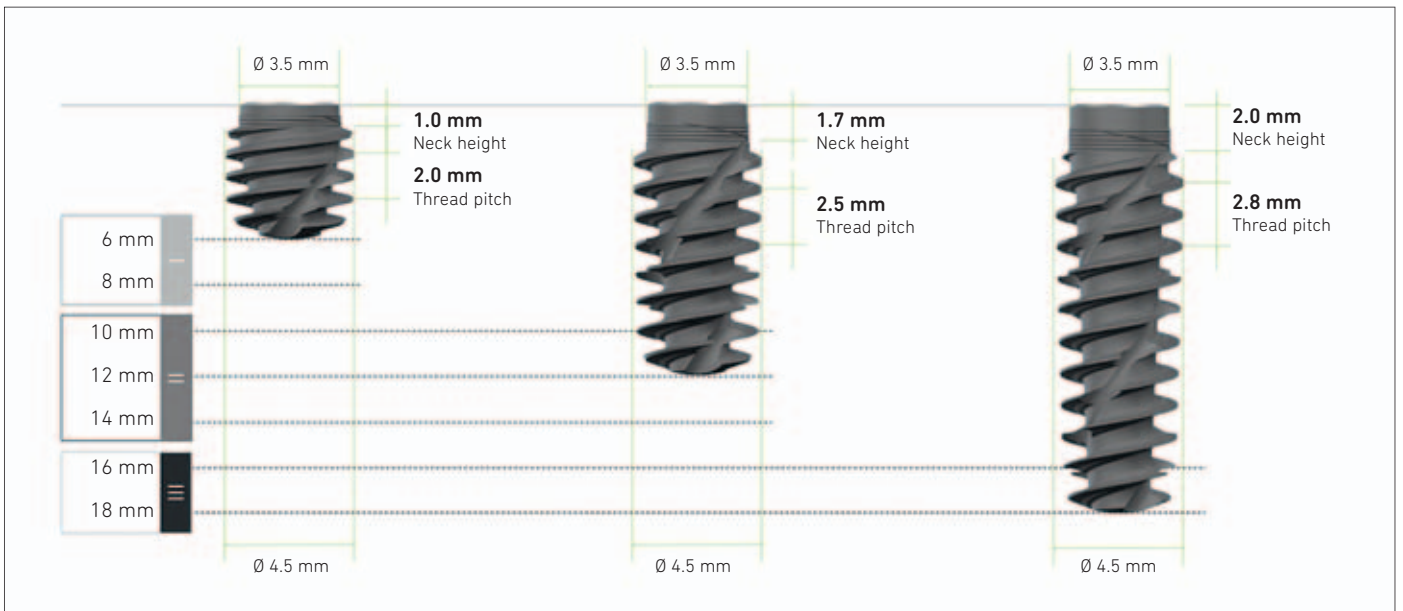


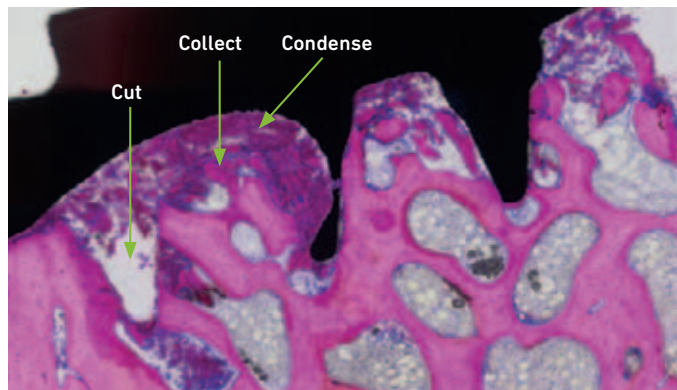
Fig. 5 Difference in implants thread design depending on various diameter and length.



Fig. 6 Detail of the tip of the threads.



**Fig. 7** The presence of bone collection grooves along the implant allows for optimal bone distribution around the implant.




**Fig. 8** Histological section illustrating the capacity of cutting, collecting and condensing the peri-implant bone.

### Full length chip flute

Present along the entire length of the implant, these lateral grooves give it its unique ability to collect the bone chips cut by the implant threads. These grooves allow the bone collected around the implant to be evenly distributed to build a reinforced interface using the compaction capabilities of the implant. This configuration results in optimal bone-to-implant contact all around the implant (**Fig. 7 and 8**).

### Implant neck of reduced diameter

The reduced diameter of the implant neck (**Fig. 9**) minimizes the stress on the cortical bone at the end of insertion. The bone cortex therefore does not need to be adjusted by an additional surgical



**Fig. 9** Detail of the implant neck of reduced diameter; the implant threads act as a "profiled" drill due to their larger size.

instrument and bone resorption is limited to a minimum during the remodeling phase following insertion of the implant, allowing for optimal maintenance of the crestal bone (**Fig. 10**).

### TorcFit® connection

The BLX implant has a single connection regardless of implant diameter (**Fig. 11**). In addition to reducing the surgical and prosthetic components required to use this implant and thus considerably simplifying the daily management of the various instruments, this connection with improved mechanical properties allows prosthetic parts of reduced diameter to be used to draw maximum benefit from the platform switching phenomenon by increasing the volume of soft tissue around the implant neck. In addition, the use of these narrower parts considerably reduces the risk of bone interference when inserting various prosthetic components (**Fig. 12**).

### Roxolid® and SLActive® surface

Finally, the BLX implant is only available with the combination of Roxolid® alloy and SLActive® surface. This allows it to be approved for all indications from 3.75 mm diameter onwards due to the elevated mechanical properties of the Roxolid® alloy. In addition, the excellent behavior of the SLActive® surface allows for shorter osteointegration times, better results in immediate loading protocols, better healing of peri-implant defects in cases of immediate implant placement, and better behavior in specific circumstances (smokers, diabetics, etc.).



**Fig. 10** Histological section illustrating the good behaviour of the crestal bone around the BLX implant even in type I bone.



**Fig. 11** Detail of the Torc Fit® connection: the connection is the same for all implant diameters, its internal configuration allows six positions, an internal Morse tapered angle of 7°, guaranteeing the seal of the connection, and an external bevel, oriented at 22.5°, with a polished surface. Finally, the reduced height of the Torc Fit® connection of 5 mm reduces the minimal implant length to 6 mm.



**Fig. 12** Comparison of BLT and BLX prosthetic parts; the Torc Fit® connection reduces the space requirement of prosthetic parts and thus optimizes the volume of peri-implant soft tissue around the BLX while reducing the risk of bone interference.

## SURGICAL PROTOCOL

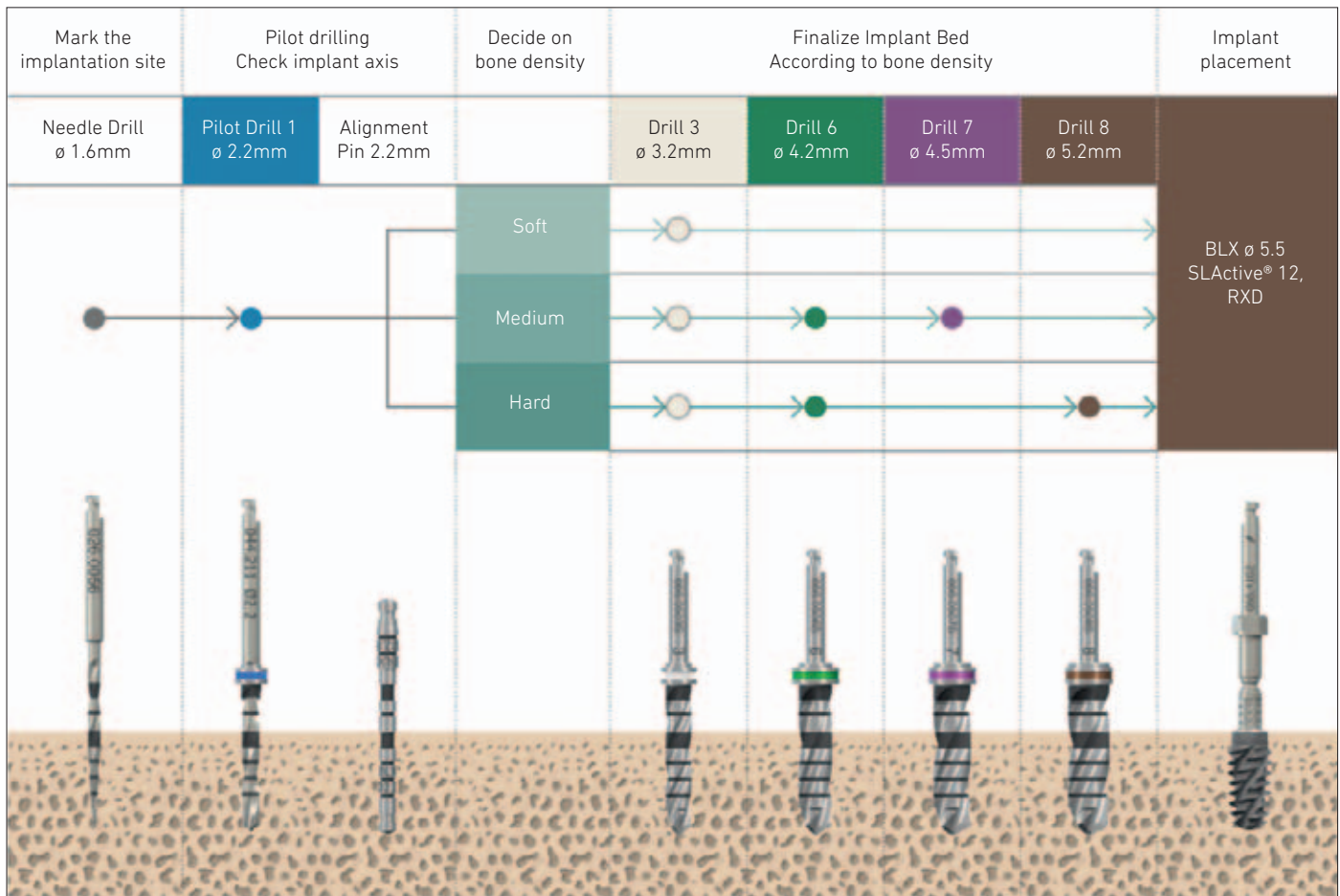


Fig. 13 BLX surgical protocol.

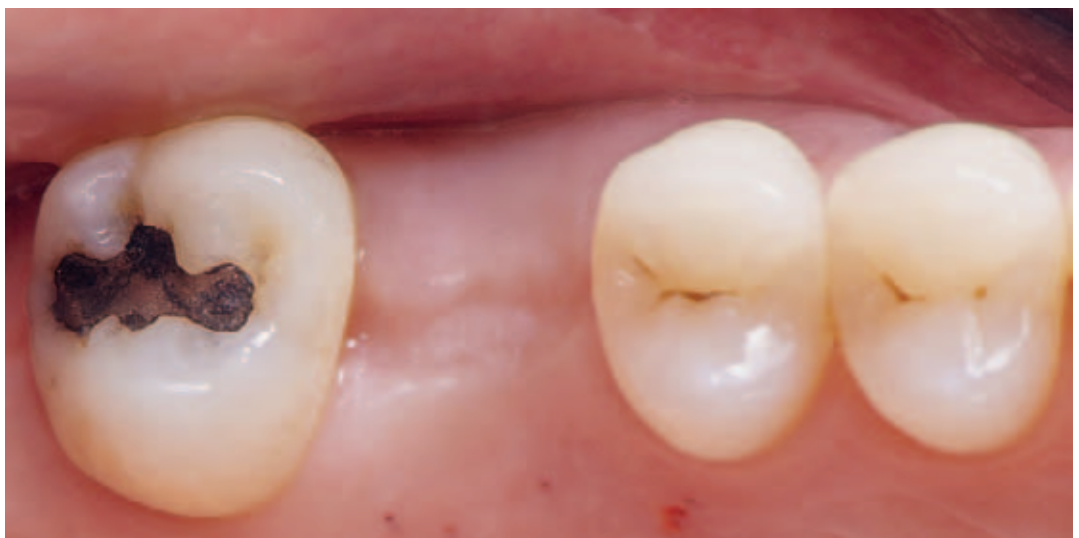

Fig. 14 Preoperative occlusal view.



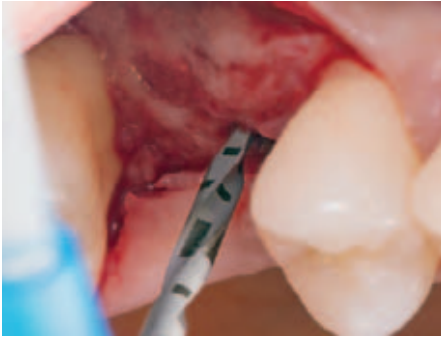

Fig. 15 Passage of the first drill.

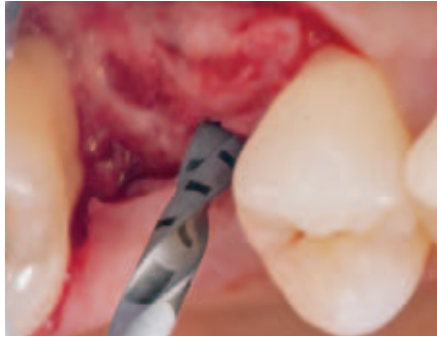

Fig. 16 2.2 mm drill.

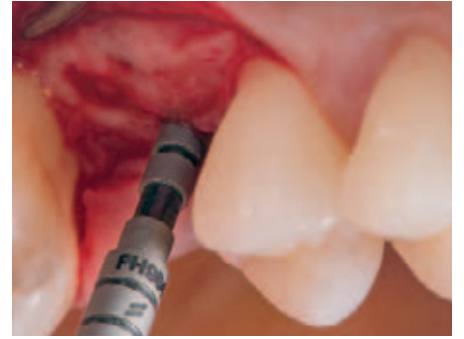

Fig. 17 Verification of the drilling axis.

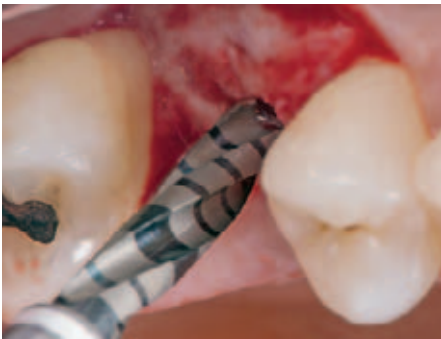

Fig. 18 3.2 mm drill.

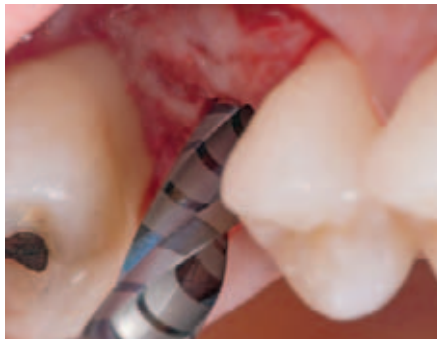

Fig. 19 4.2 mm drill.

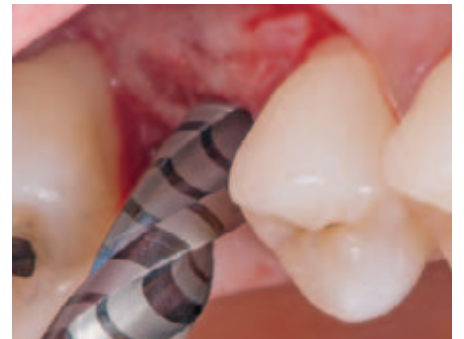

Fig. 20 4.5 mm drill.

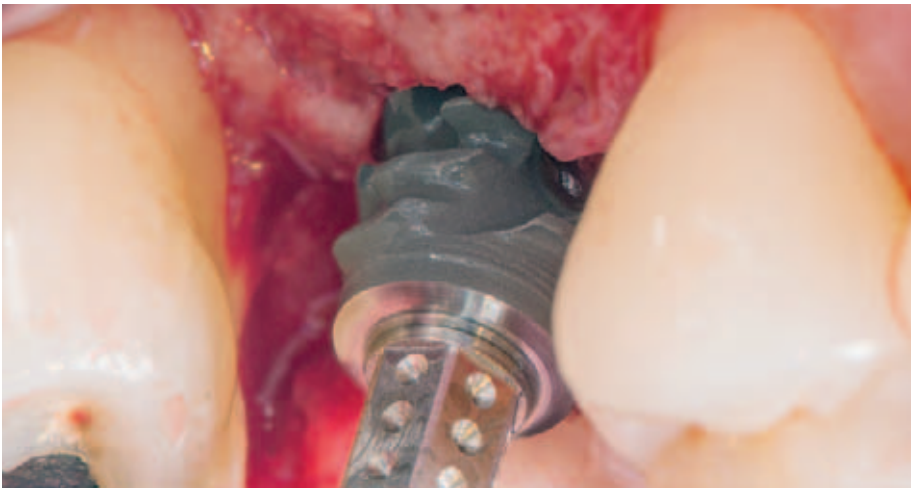

Fig. 21 Insertion of a BLX implant.

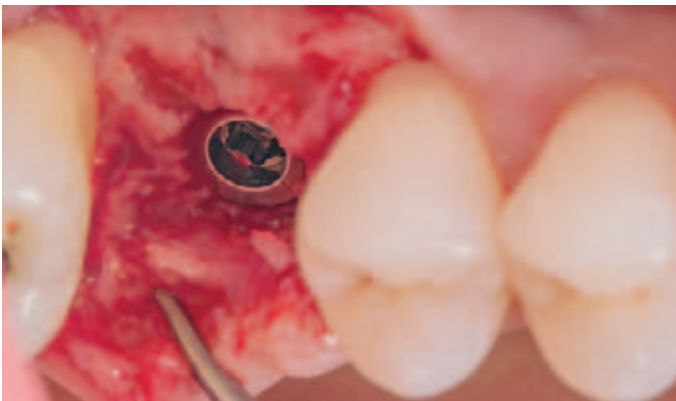

Fig. 22 Occlusal view after implant insertion.

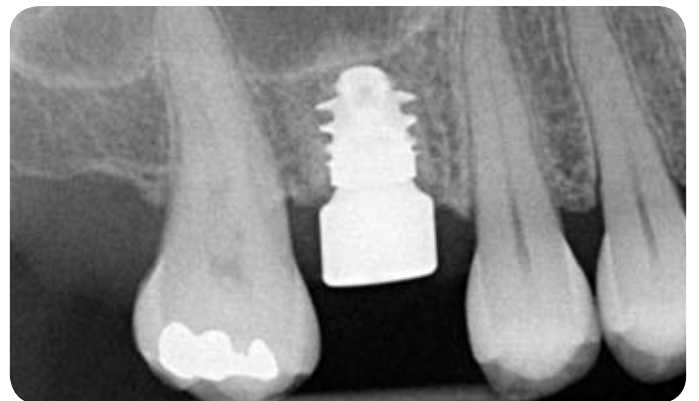


Fig. 23 Post-operative peri-apical X-ray.

## Clinical situation 1

### The management of narrow spaces due to converging roots

The pre-implant analysis systematically includes radiographic analysis. The presence of converging roots is detectable both on well angulated peri-apical X-rays and on CT scan.

The bone volume available for implantation is sometimes reduced by the presence of converging adjacent roots.

Damage to the cementum or dentin caused by drilling or by the implant can trigger an external resorption process, cause a crack or fracture, or even cause necrosis in the tooth in question.

When the residual volume is too small to place an implant without guaranteeing a safe

distance from any anatomical obstacles, it is a local contraindication to the placement of dental implants. It is then necessary to perform pre-implant orthodontic treatment.

Some situations are less clear-cut, and the use of an implant with apical conicity saves space and allows the implant to be placed in the desired position while avoiding the roots of adjacent teeth. The conical design of the BLX implant increases safety when implanting in this type of situation.

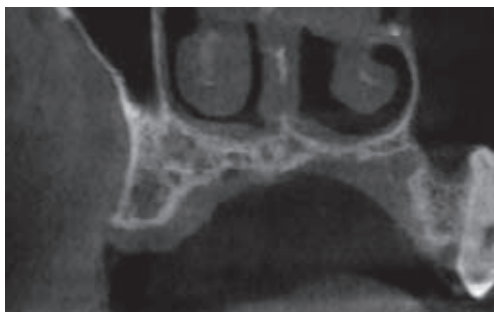
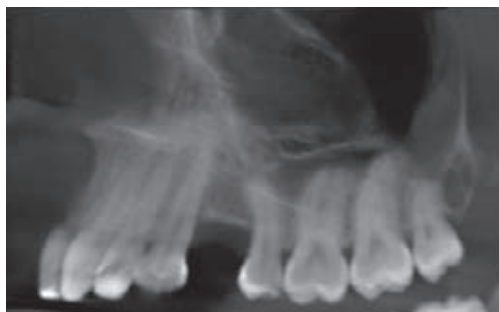

Fig. 1-1 a and b Preoperative CBCT showing the convergence of the 23 and 25 roots.

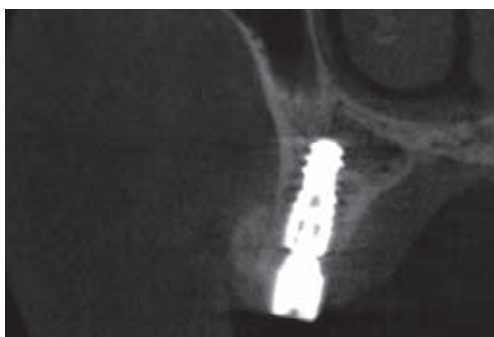
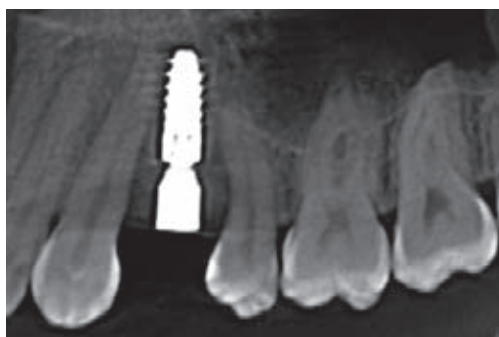


Fig. 1-2 a and b Postoperative CBCT: the use of a conical implant made it possible to overcome the surgical challenge.

## Clinical situation 2

### Immediate implant placement in the posterior area

Since an early publication in 1989, the placement of implants immediately after the extraction of single-rooted teeth has become a regularly proposed procedure.

The application of this protocol has since been successfully extended to multirooted teeth. In the literature, there are indeed cumulative survival rates for implants placed immediately after the extraction of molars, similarly to those placed in healed posterior sites. On the conditions of this success, the authors are

unanimous: the essential factor for the success of immediate implant placement is the initial stability of the implant thanks to the apical and/or lateral bone. However, at a molar extraction site, it may be difficult to achieve this primary stability due to the size of the socket, poor bone quality, or anatomical limitations such as the maxillary sinus or mandibular canal. The specific design of the BLX implant allows satisfactory primary stability to be obtained, even in a very reduced septum.

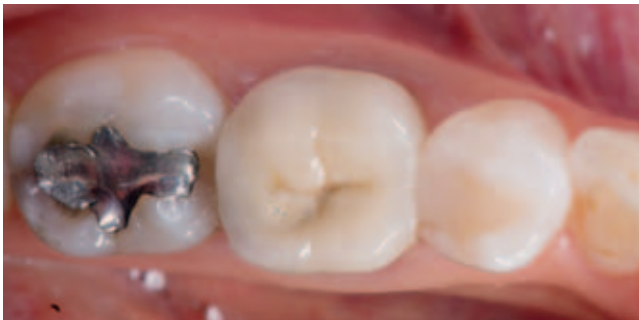

Fig. 21 Preoperative occlusal view before extraction of tooth 36.

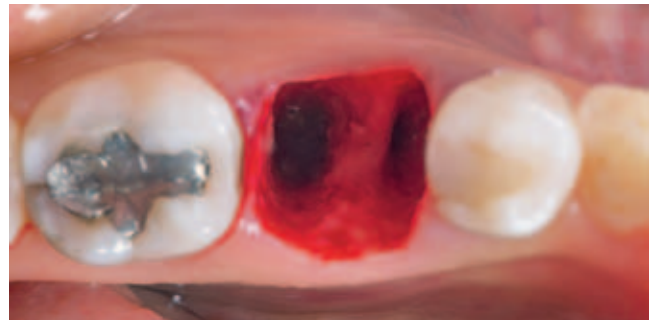

Fig. 22 Atraumatic extraction of tooth 36.

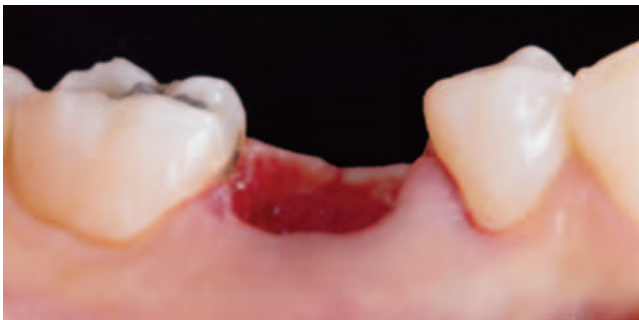

Fig. 23 Buccal view after extraction.

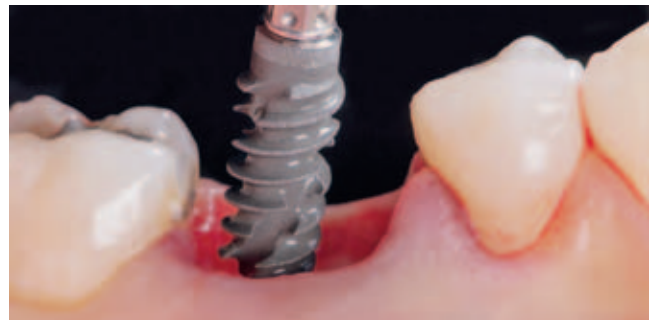

Fig. 24 Insertion of a BLX implant.

## Clinical situation 2

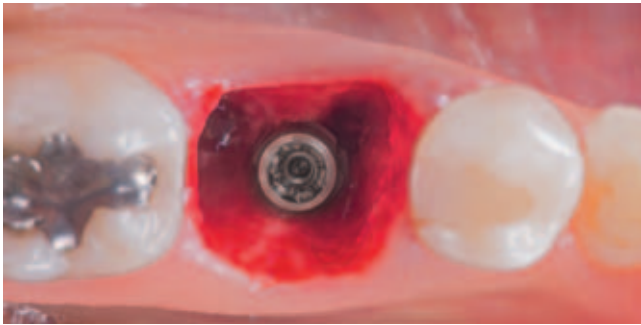


Fig. 2.5 Occlusal view after insertion of a BLX implant.

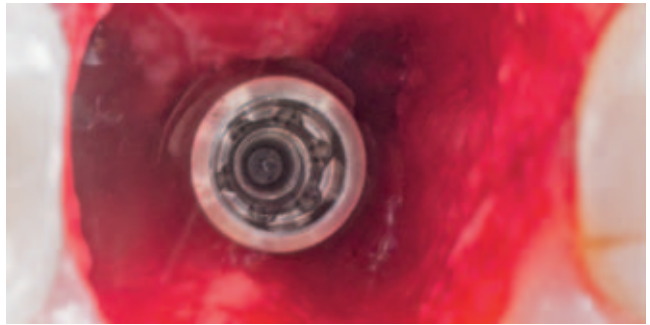


Fig. 2.6 The engagement of the threads in the septum provides sufficient primary stability.

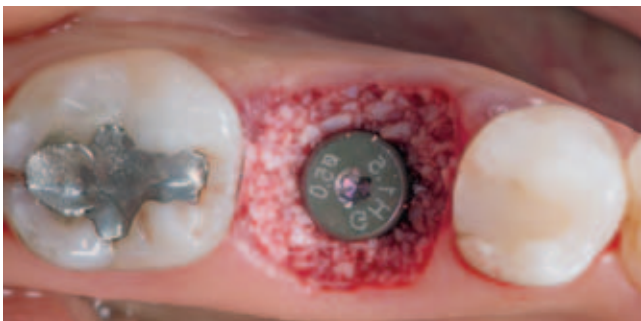

Fig. 2.7 A xenograft is used to fill the gap.

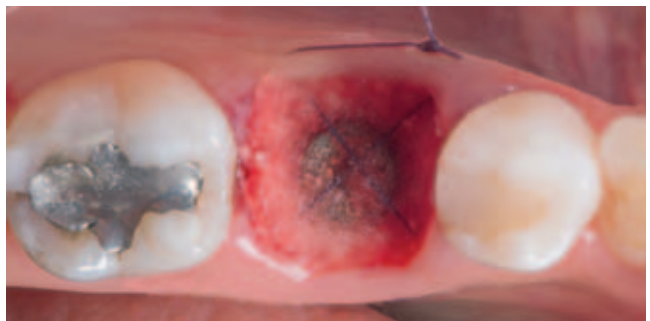

Fig. 2.8 A collagen sponge is placed to protect the surgical site.

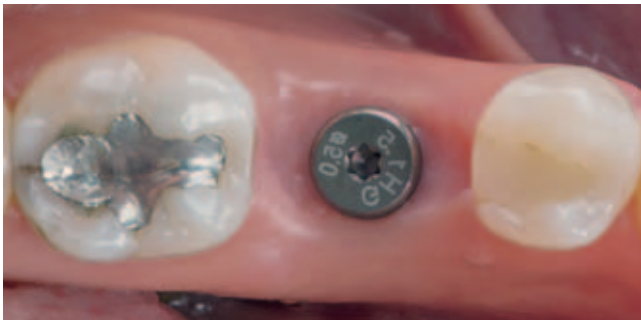

Fig. 2.9 Occlusal view after three months of healing.

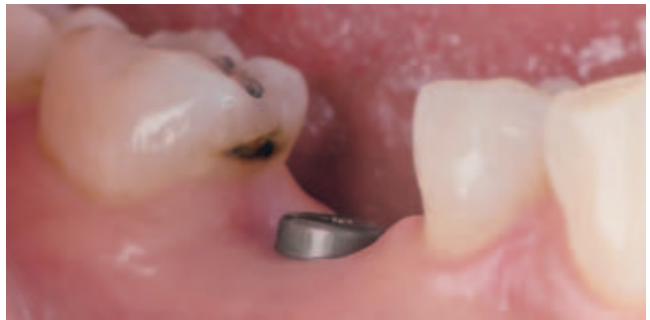

Fig. 2.10 Buccal view after three months of healing.

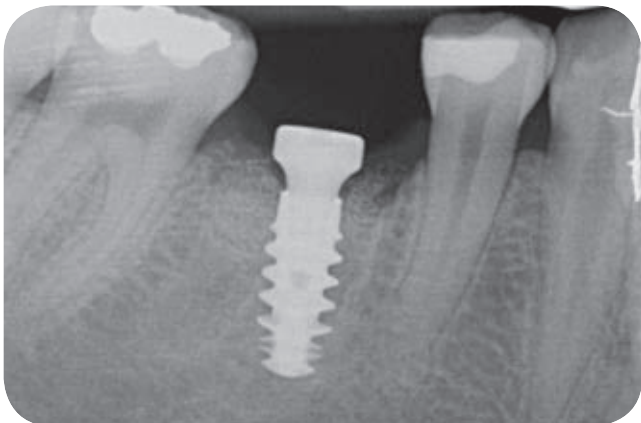

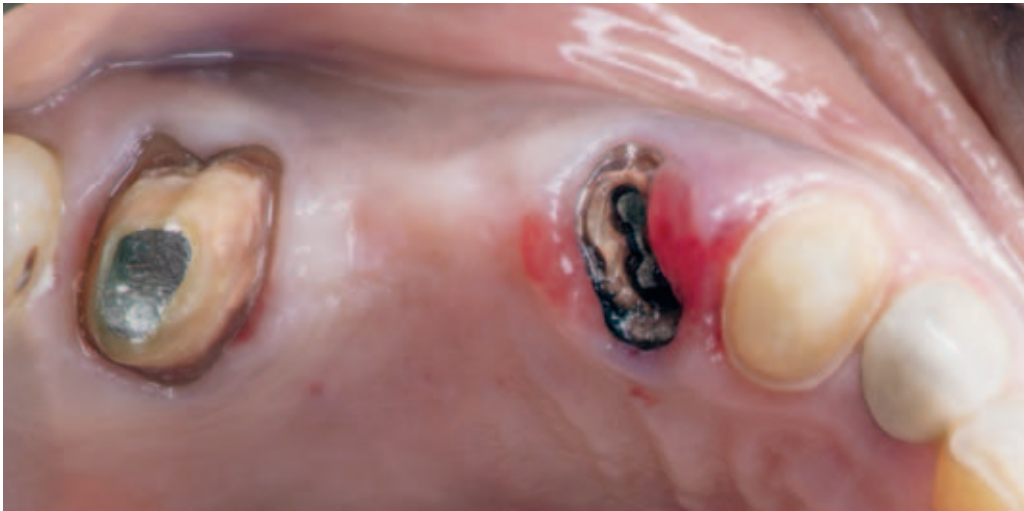Fig. 2.11 Peri-apical X-ray 3 months after surgery.

### Clinical situation 3

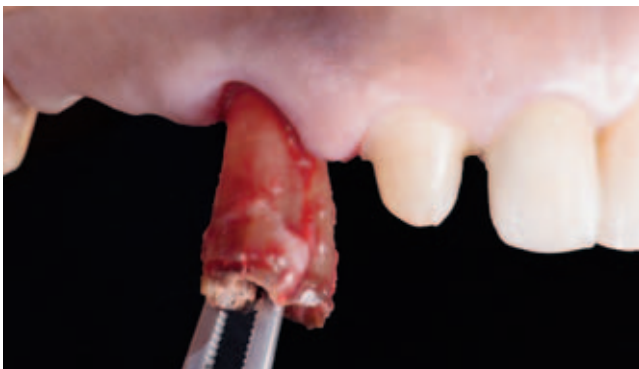#### Immediate treatment of a lateral sector

In cases of multiple missing teeth, the management of temporization can be challenging. Provided that sufficient primary implant stability is achieved, it may be possible, in some situations, to immediately load the implants. The use of SRA (Screw Retained Abutment) on

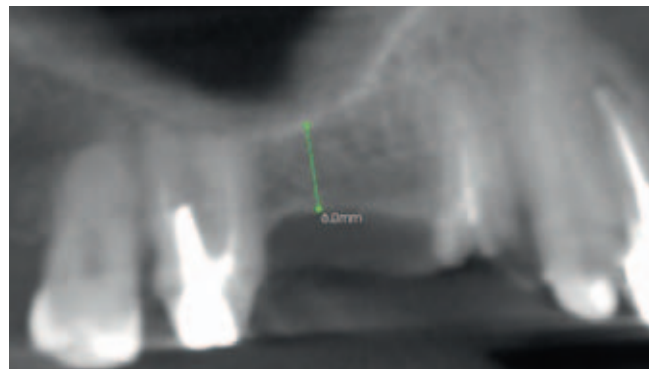
Bone Level implants compensates for implant axis deviations while maintaining the seal of the implant connection at bone level. A temporary bridge can simply be made in the same session as the surgery to allow for fixed implant-supported temporization.



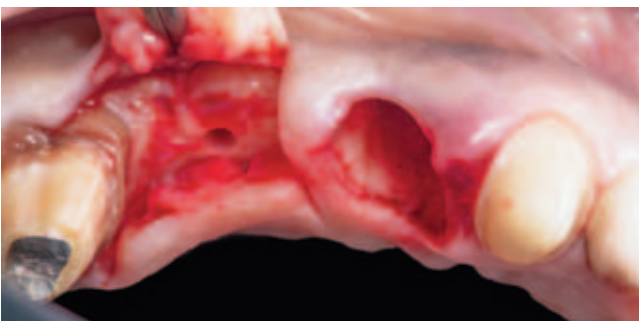**Fig. 3-1** Preoperative occlusal view: tooth 14 is hopeless.



**Fig. 3-2** Atraumatic extraction of tooth 14.



**Fig. 3-3** The pre-operative CBCT shows a bone height of 6 mm at 16 site and sufficient bone volume for immediate implant placement after extraction of tooth 14.



**Fig. 3-4** A flap is raised at the implant site of 16.

### Clinical situation 3

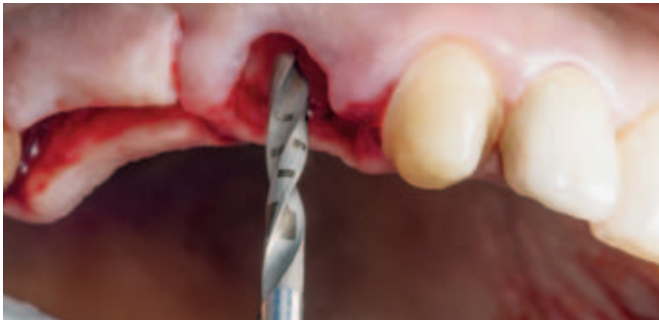

Fig. 3-5 2.2 mm drill at implant site of 14.

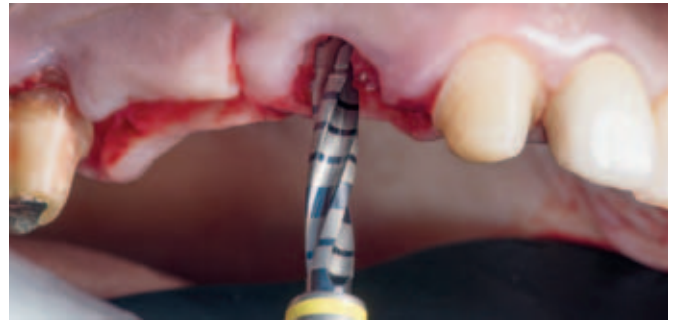

Fig. 3-6 2.8 mm drill at implant site of 14.

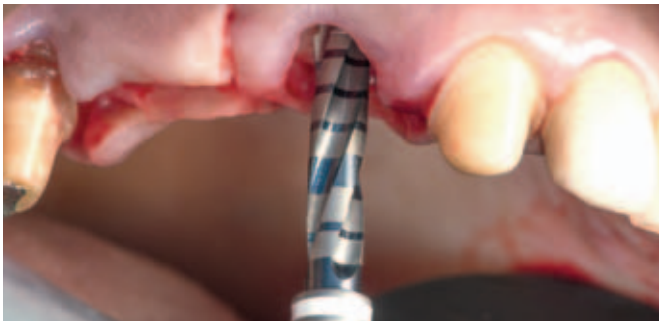

Fig. 3-7 3.2 mm drill at implant site of 14.

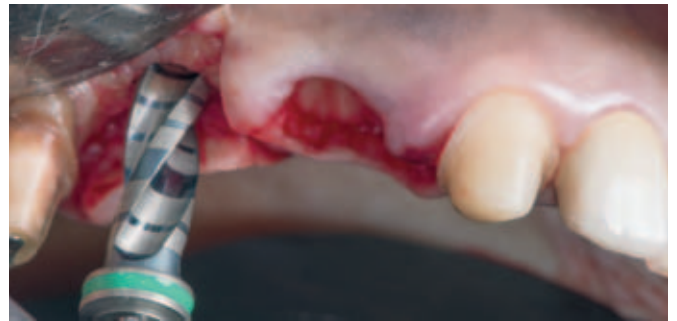

Fig. 3-8 4.2 mm drill at implant site of 14.

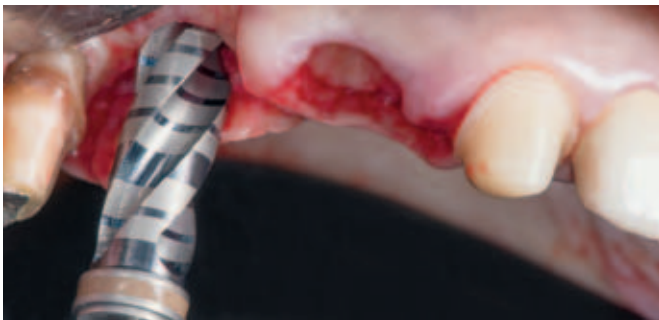


Fig. 3-9 5.2 mm drill at implant site of 14.

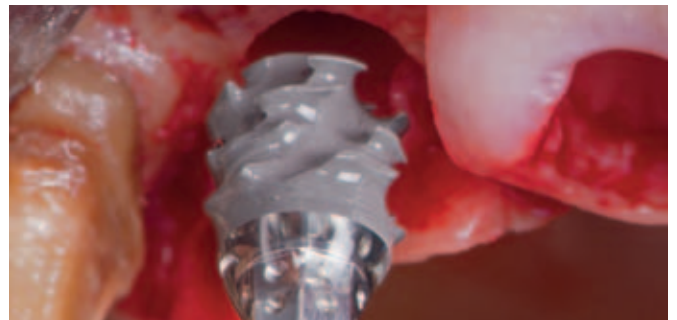

Fig. 3-10 Insertion of a BLX implant in place of tooth 16.

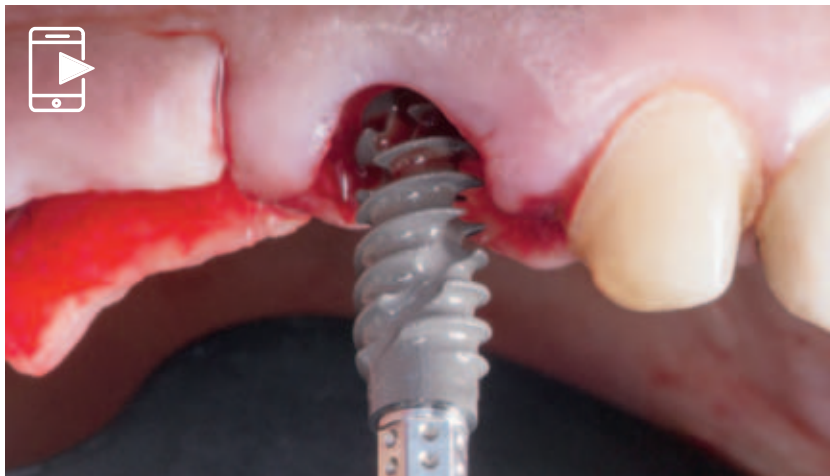

Fig. 3-11 Insertion of a BLX implant in place of tooth 14.

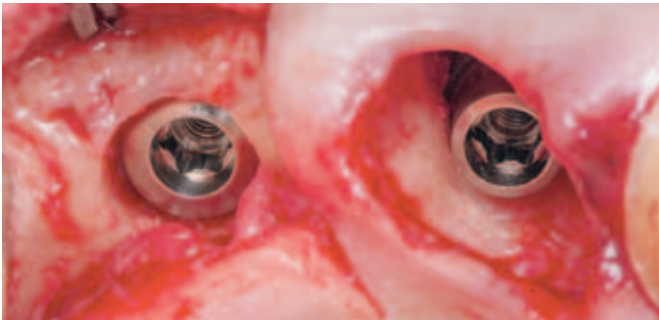


Fig. 3-12 Occlusal view after implant insertion.

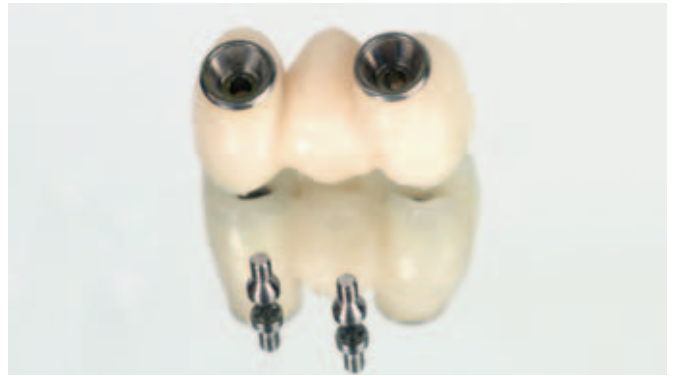

Fig. 3-13 Fabrication of an immediate provisional bridge on SRA abutments.

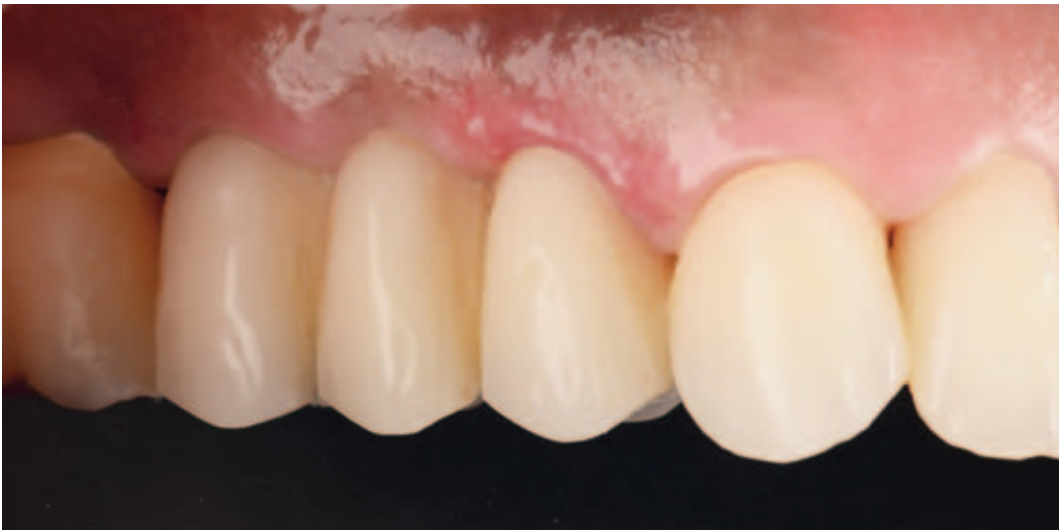

Fig. 3-14 Buccal view of healing 3 months after surgery.

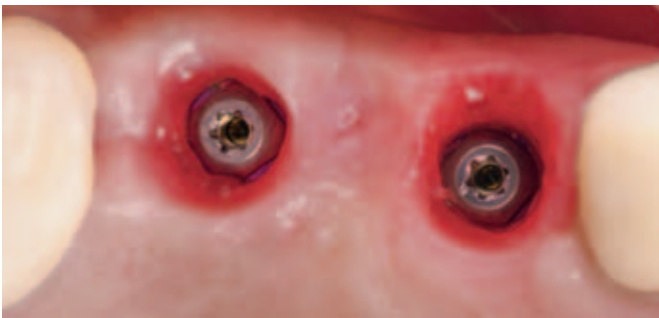


Fig. 3-15 Occlusal view of the SRA abutments, three months after immediate loading: the final restoration can be made.

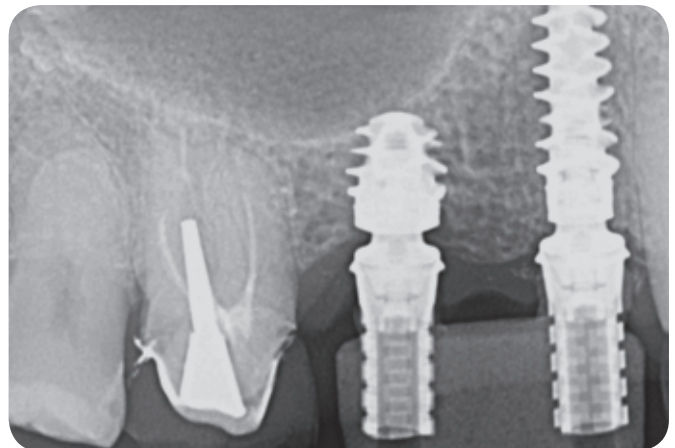


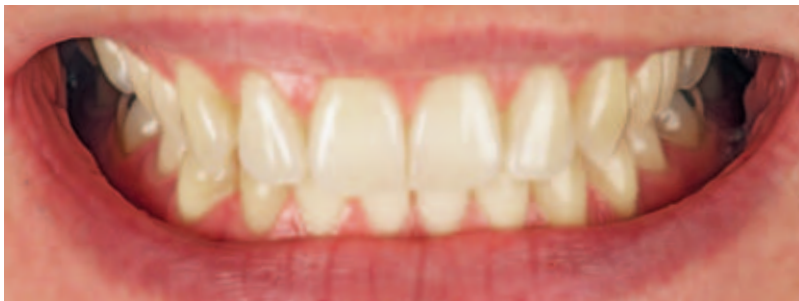Fig. 3-16 Post-operative radiograph 3 months after surgery.

## Clinical situation 4

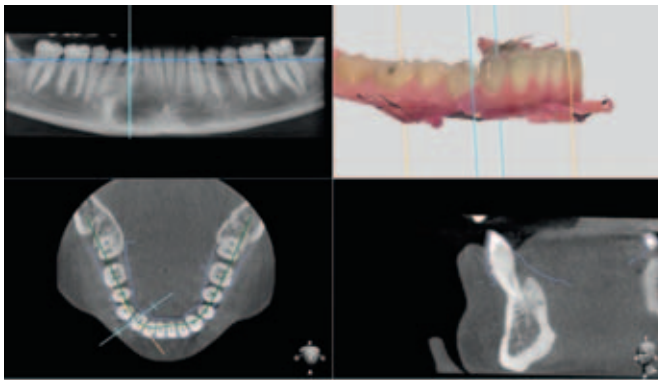
### Immediate implant placement in a mandibular canine site

The placement of implants immediately after the extraction of single-rooted teeth has become a commonly-used procedure even if its supposed benefits in terms of preserving bone capital have proved to be less significant than initially assumed. Adding an immediate esthetic procedure using an implant-supported temporary crown also allows the pre-existing tissue architecture (gingival contour and interdental

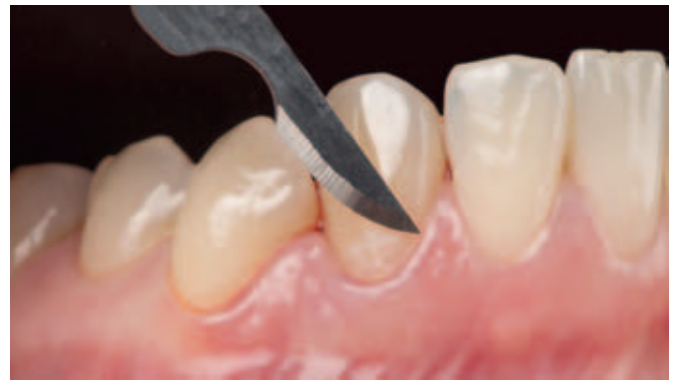papillae) to be maintained. In the following clinical case, the patient presented with a lower right canine that was deemed hopeless after the patient suffered an iatrogenic germectomy in this area. The decision was made to perform an extraction-implantation procedure with immediate provisionalization to preserve the soft tissue architecture.



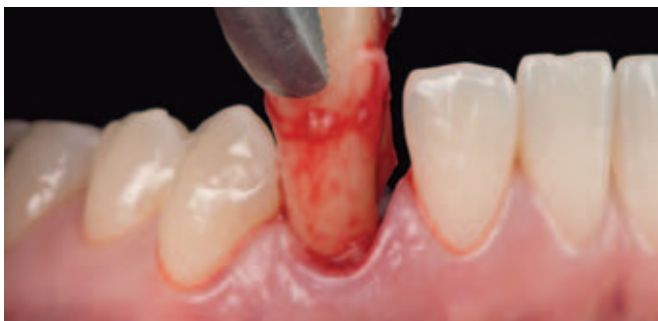**Fig. 4.1** Preoperative view, tooth 43 is visible when smiling. It presented a iatrogenic root lesion and was considered as hopeless.



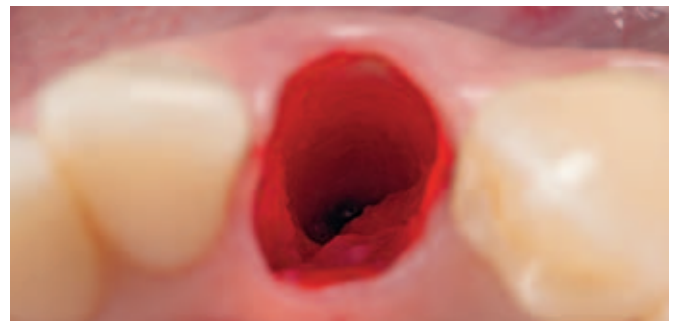
**Fig. 4.2** The STL files of the intra-oral impression are merged with the patient's DICOM obtained from the CBCT. A tooth-supported surgical guide is obtained.



**Fig. 4.3** Intrasulcular incision for the atraumatic extraction of tooth 43.



**Fig. 4.4** Atraumatic extraction of tooth 43.



**Fig. 4.5** Occlusal view showing an intact buccal cortical. The extraction did not damage the adjacent hard and soft tissues.



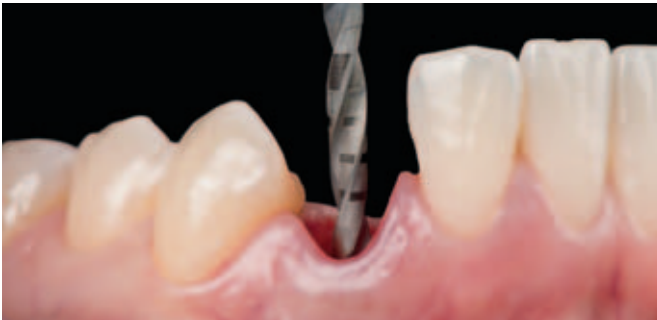

Fig. 4-6 2.2 mm drill.

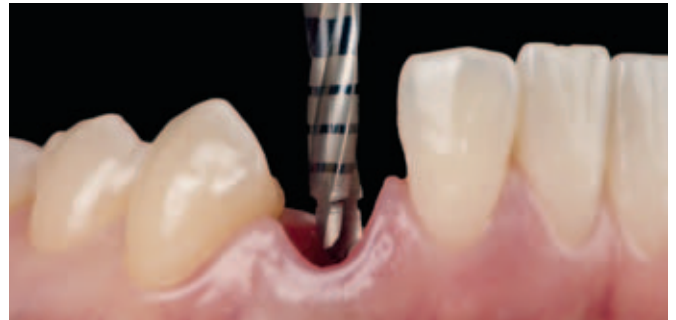

Fig. 4-7 2.8 mm drill.

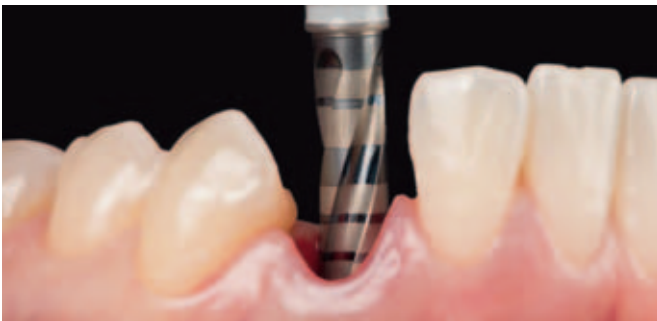


Fig. 4-8 3.2 mm drill.

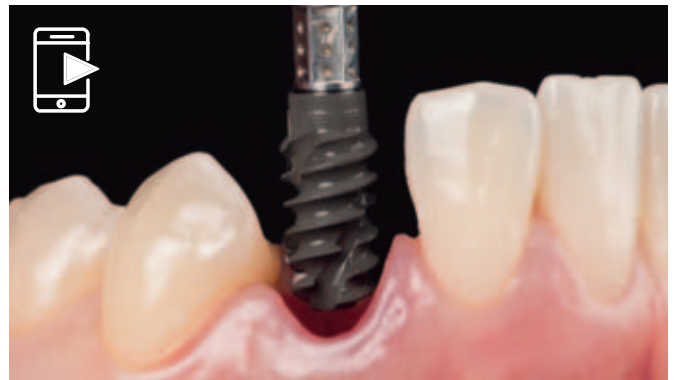

Fig. 4-9 Insertion of a BLX implant.

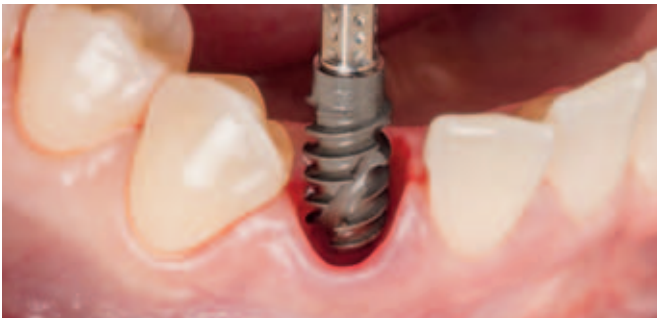

Fig. 4-10 Occlusal view of the insertion of the implant.

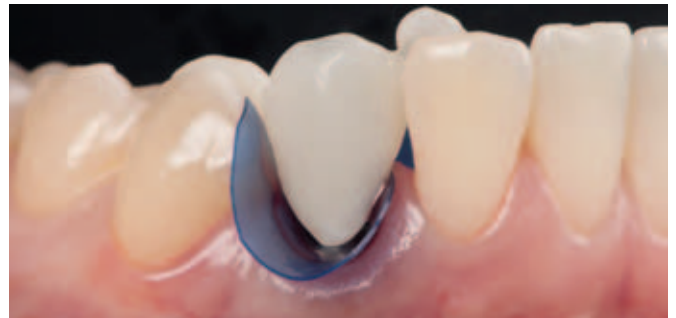

Fig. 4-11 Placement of a temporary shell with wings that will be soldered to the temporary abutment (*Lab work Julien Montenero*).

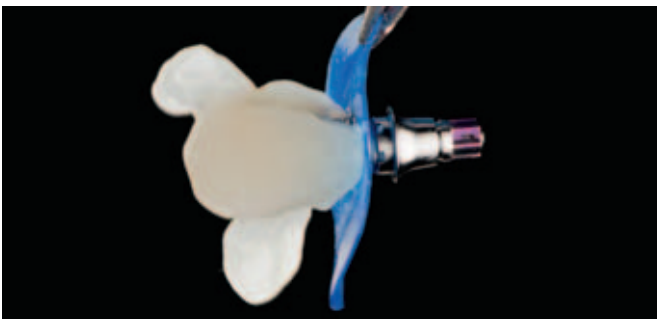

Fig. 4-12 The temporary abutment is attached to the provisional shell.

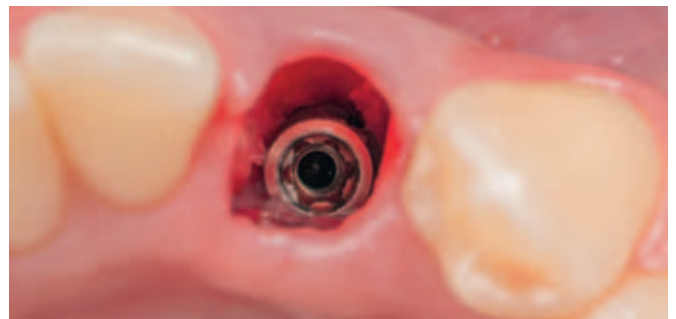
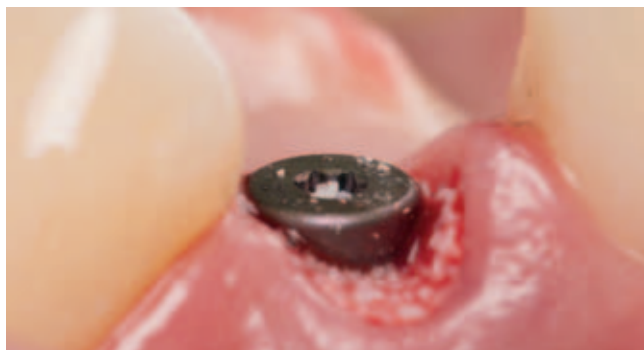
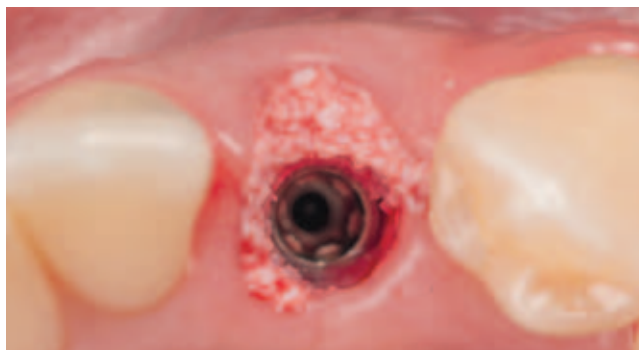

Fig. 4-13 Occlusal view after implant placement.

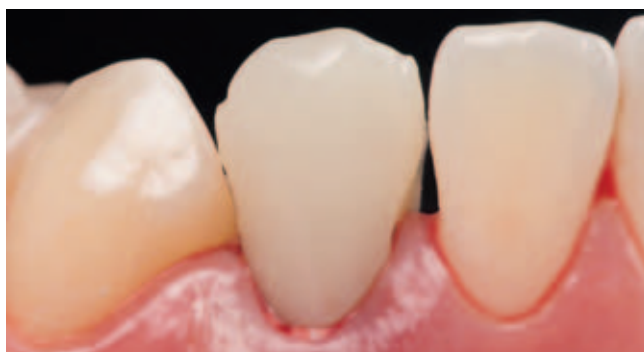## Clinical situation 4



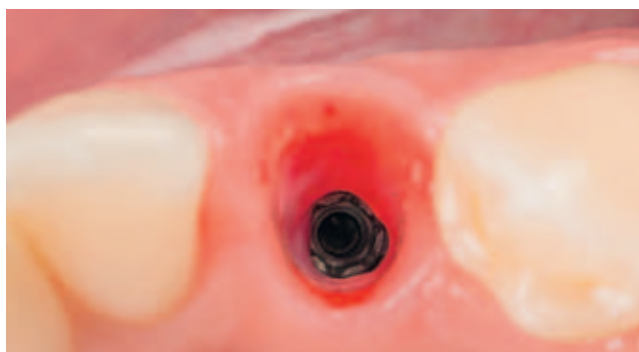**Fig. 4-14** The filling material is added up to the gingival margin according to the "dual-zone" technique principle.



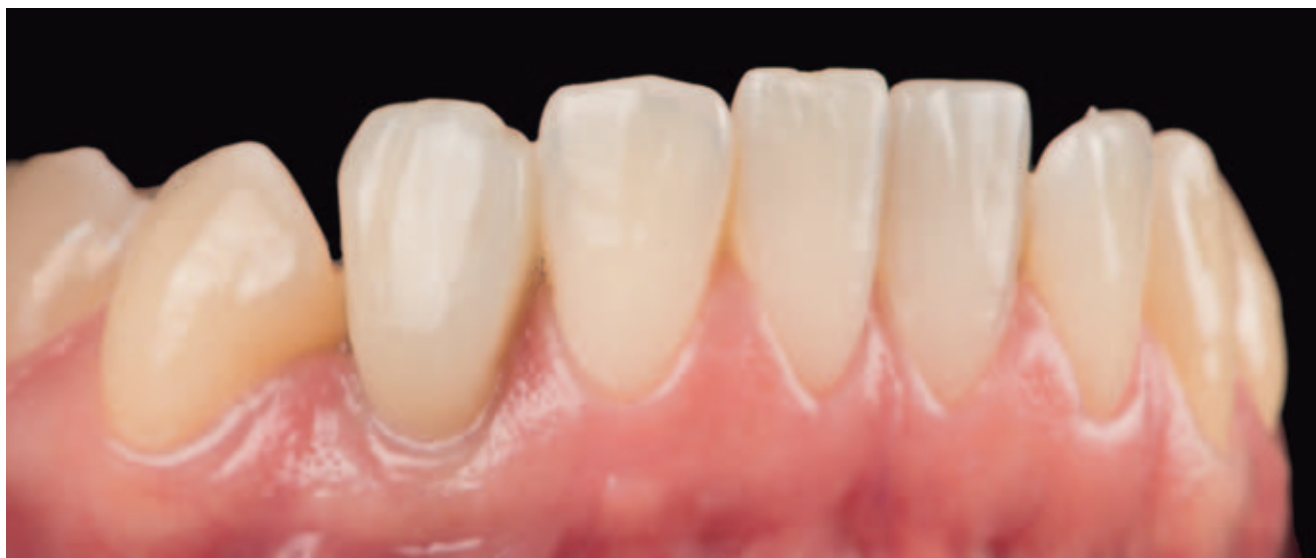**Fig. 4-15** The healing abutment is unscrewed.



**Fig. 4-16** The temporary screw-retained crown is placed.



**Fig. 4-17** View of the site after three months of healing.



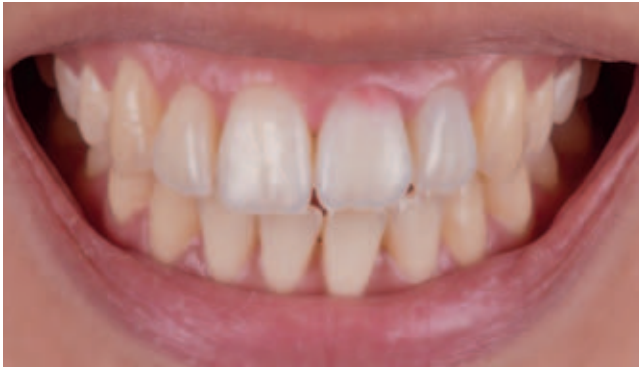**Fig. 4-18** Buccal view after three months of healing (*Lab work Julien Montenero*).

## Clinical situation 5

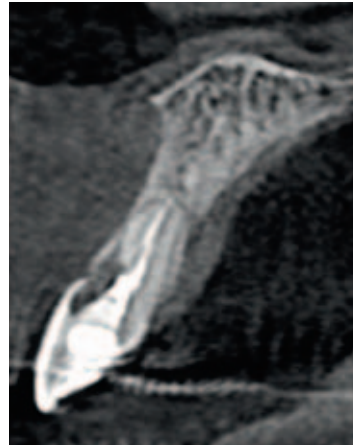### Immediate implant placement in a central incisor site with a focus on the process of making of a temporary implant-supported crown chairside

The immediate implant-supported temporary crown is of paramount importance for healing and shaping the surrounding tissues. Its manufacture and characteristics must not be neglected because they contribute to the success or failure of the whole procedure. The use of a surgical guide must be systematized to allow for optimal three-dimensional placement. However, in cases of immediate implant placement, placing the implant through the guide, in the aim of placing a temporary crown that has been fully prepared upstream, is rarely

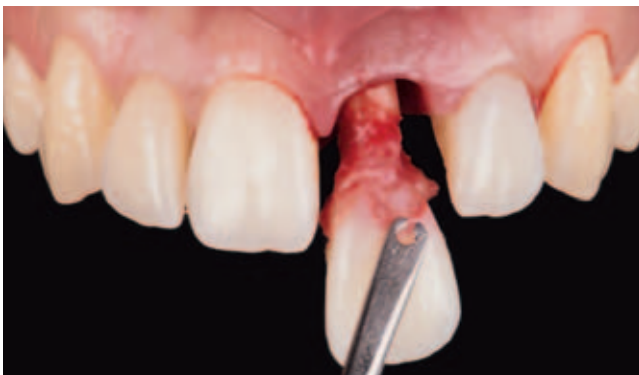satisfactory. Indeed, the constraints of the palatal cortex during insertion are significant and can lead to deviations despite the use of the guide, preventing the temporary crown from being placed in the planned position. It may be necessary to master a simple prosthetic protocol to be able to make a temporary crown in a few minutes chairside by bonding a temporary prosthetic abutment to a digitally designed hollow crown. A emergence profile that is concave in the buccal area and straight or slightly convex in the proximal areas is then produced.



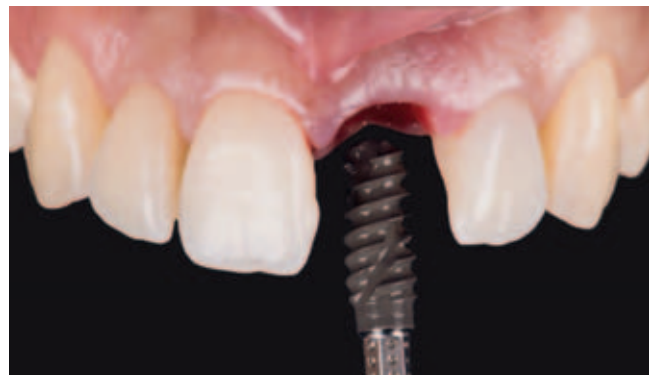**Fig. 5-1** Smile view: tooth 21 showed an external root resorption, was considered as hopeless.



**Fig. 5-2** An immediate implant placement procedure was indicated.

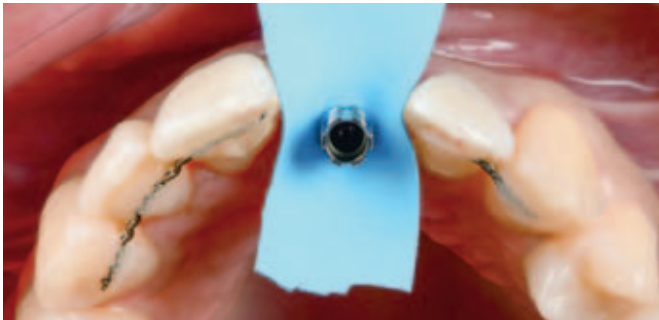


**Fig. 5-3** Atraumatic extraction of tooth 21.

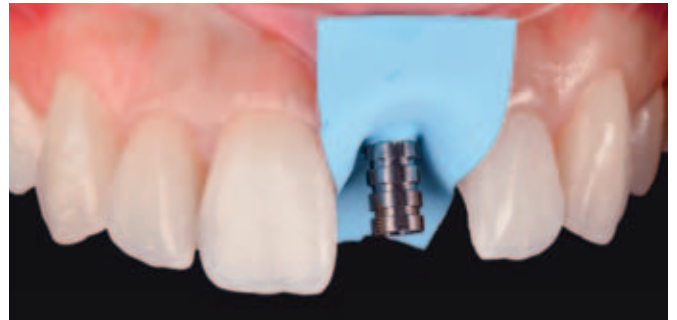

**Fig. 5-4** Immediate placement of a BLX implant.

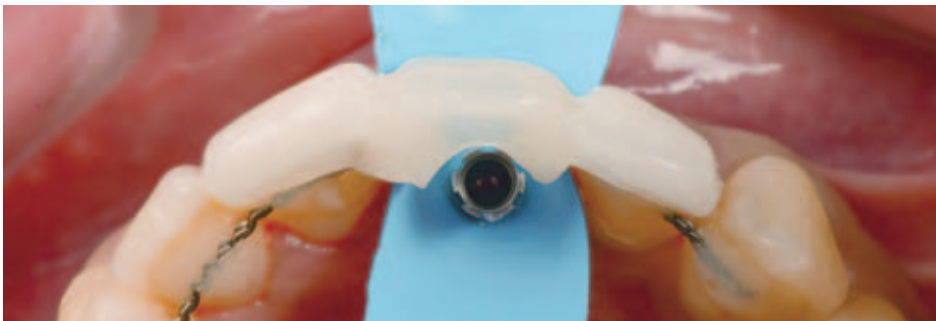## Clinical situation 5



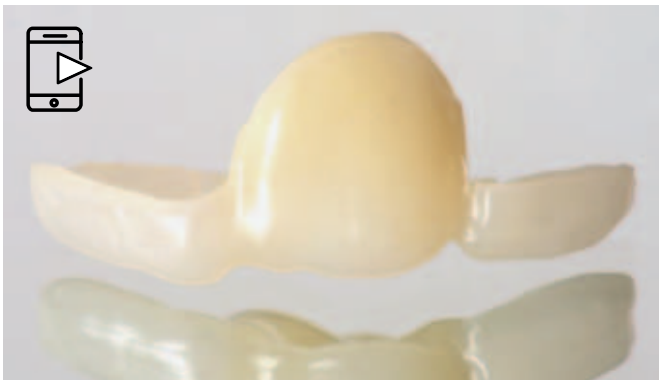**Fig. 5-5** A temporary abutment is screwed in, and a piece of rubber dam is placed to protect the surgical site.



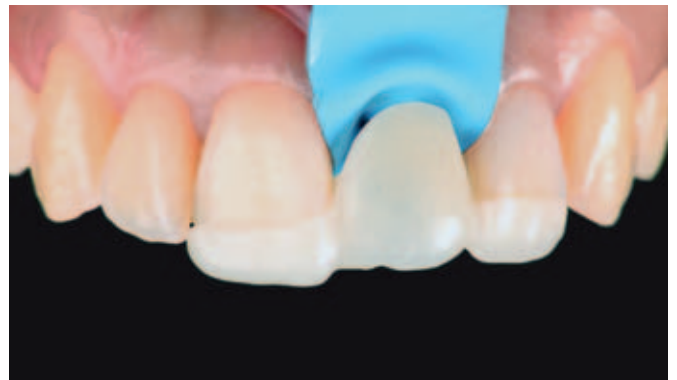**Fig. 5-6** Buccal view before connecting a temporary shell.



**Fig. 5-7** Occlusal view showing the temporary shell supported by two wings.



**Fig. 5-8** Detail of the provisional restoration obtained by CAD/CAM; the proximal wings allow an ideal positioning of the future restoration (Lab work Julien Montenero).



**Fig. 5-9** Buccal view when connecting the temporary abutment to the provisional shell with resin.



**Fig. 5-10** Once the connection is made, the abutment is unscrewed and the provisional crown is finished outside of the patient's mouth.



**Fig. 5-11** The emergence profile must be fully adjusted at this stage.



Fig. 5-12 The wings are removed.



Fig. 5-13 The provisional crown is connected to an implant replica to facilitate the procedure.



Fig. 5-14 Resin is added with small increments.



Fig. 5-15 The ideal emergence profile is obtained.

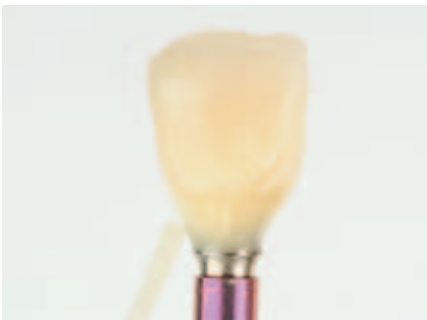

Fig. 5-16 The buccal contour of the emergence profile must be completely concave.




Fig. 5-17 Frontal view.



Fig. 5-18 Sagittal view.

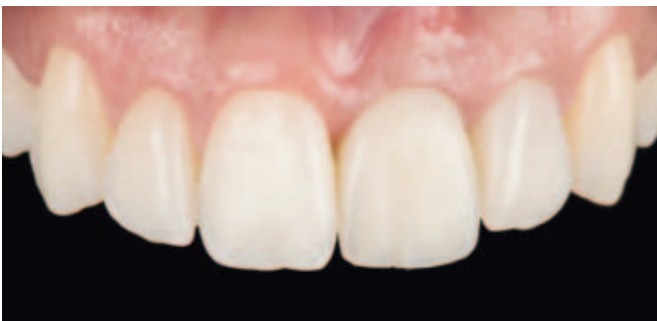

Fig. 5-19 View after three months of healing.

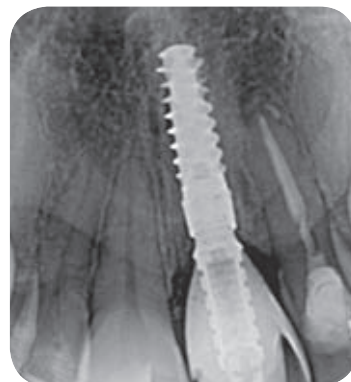

Fig. 5-20 Post-operative radiograph 4 months after implant placement.

## Clinical situation 6

### Immediate implant placement in a maxillary canine site

The question of gap management between the implant and cortical bone during an immediate implant procedure is one of the most debated topics in implantology. Many solutions have been proposed to try to preserve or regenerate an optimal gingival and bone contour around the implants. These solutions include filling with a xenograft using the "dual zone" technique, partial extraction of the root leaving the buccal fragment in place so as not to damage the ligament and vestibular bone to which it is attached, or the use of a connective tissue graft.

The latter technique was used in the case presented below. Indeed, to recreate aesthetically essential gingival volume in the canine area and to compensate for a slight loss of integrity of the vestibular cortex, it may be advisable to perform a connective tissue graft in combination with immediate implant placement. In this case the graft was taken from the tuberosity area which, when available, offers very dense connective tissue that remains particularly stable over time.

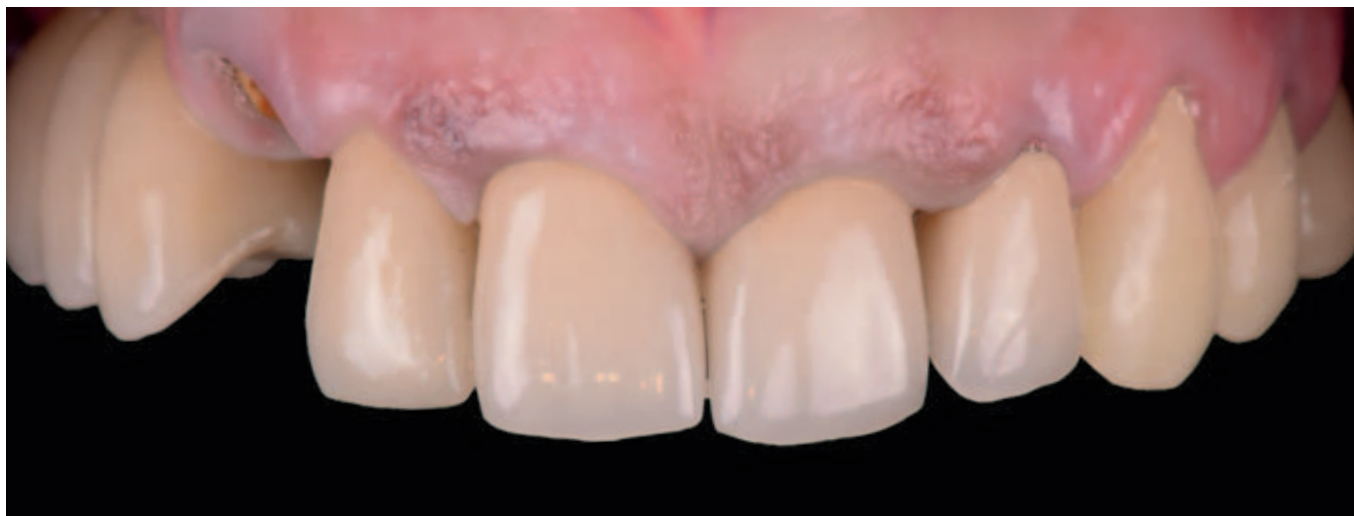

Fig. 6-1 Preoperative intraoral view: tooth 13 must be extracted.

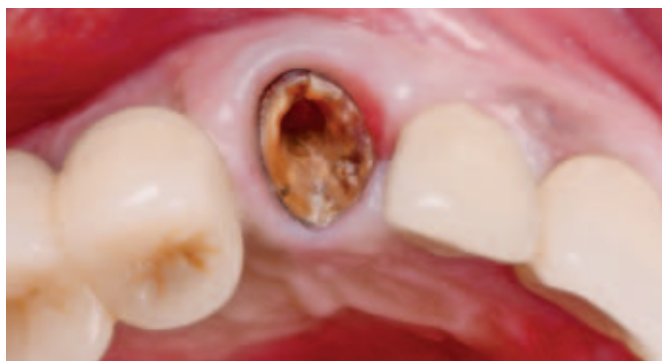

Fig. 6-2 The occlusal view makes it possible to see a bucco-lingual fracture. A particularly pronounced canine bulge is present.

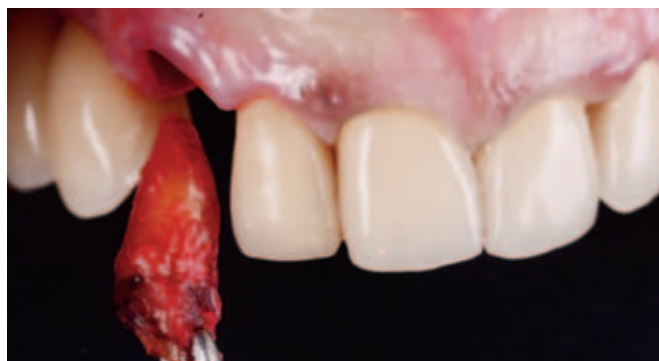
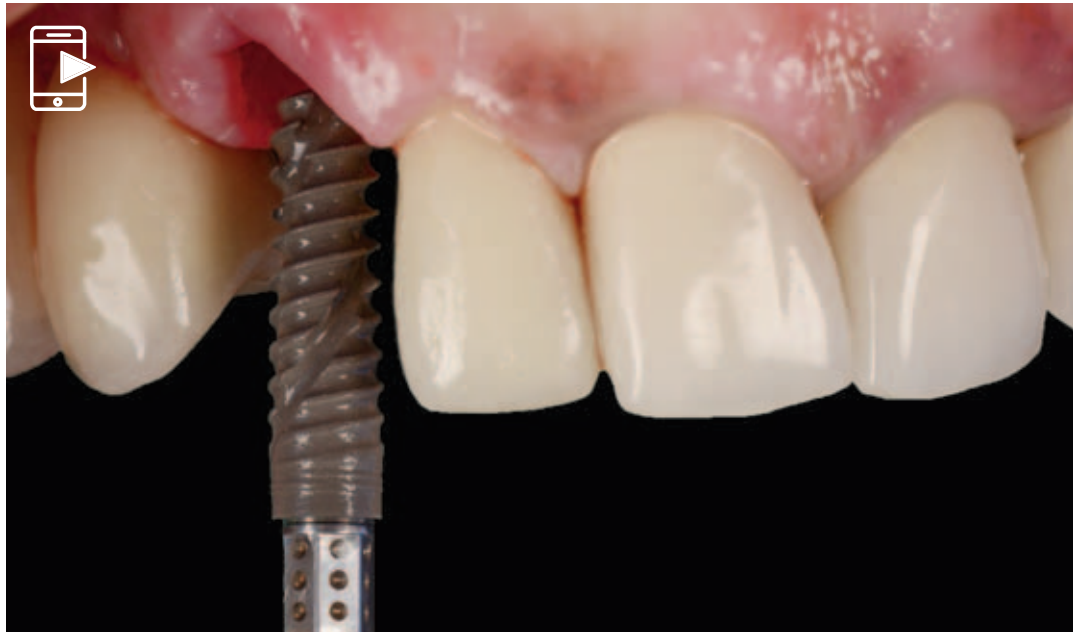
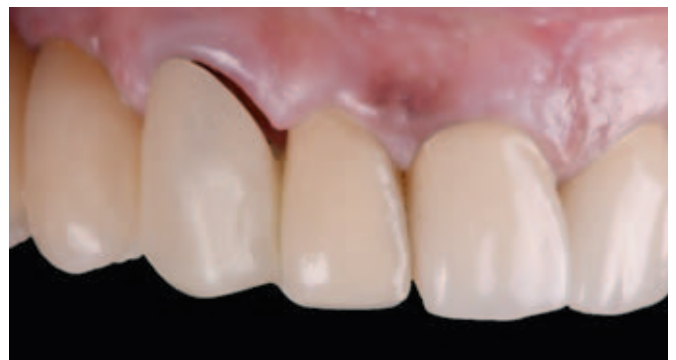Fig. 6-3 The tooth is extracted atraumatically.



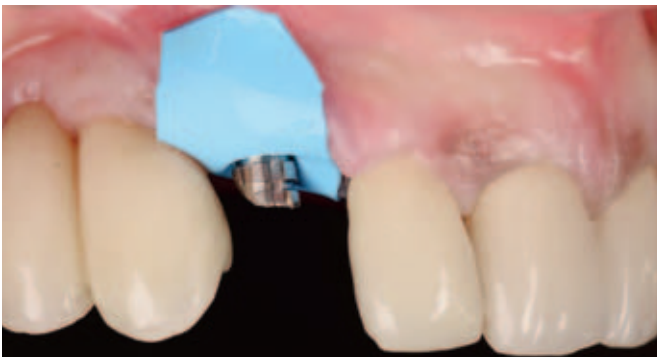**Fig. 6-4** After following the drilling sequence indicated by the manufacturer, a Straumann BLX implant can be inserted with a primary stability greater than 45 Ncm.



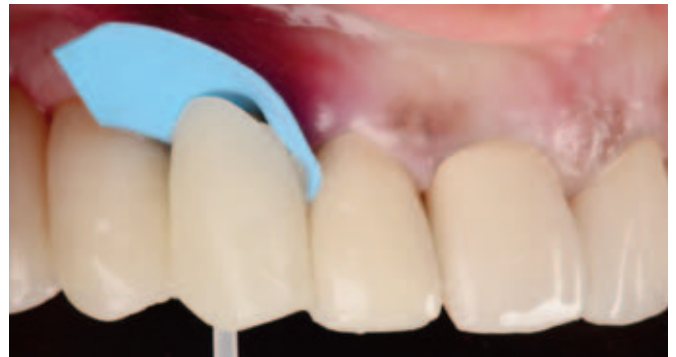**Fig. 6-5** A temporary shell, designed by computer and milled, was made beforehand in the laboratory (*Lab work Julien Montenero*).



**Fig. 6-6** The adaptation of wings to the adjacent teeth is correct.

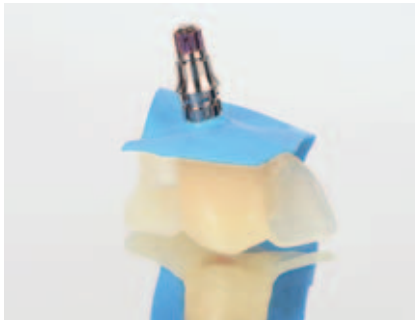

**Fig. 6-7** A temporary abutment is inserted. A piece of rubber dam is used to protect the surgical site.



**Fig. 6-8** The temporary shell is connected to the temporary abutment.

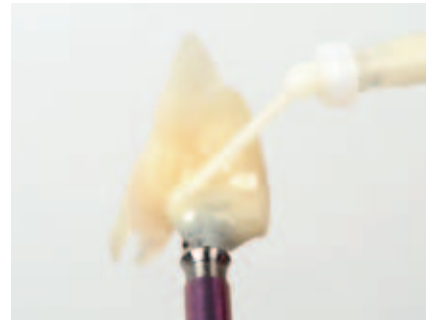## Clinical situation 6




**Fig. 6-9** Once the connection has been made with a composite resin, the abutment is unscrewed.




**Fig. 6-10** The emergence profile was adjusted outside the patient's mouth.



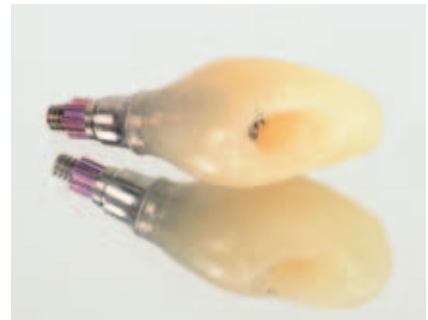
**Fig. 6-11** The temporary crown was finished by adding composite resin.



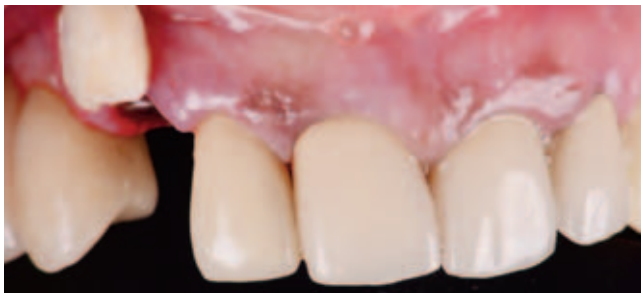**Fig. 6-12** A concave emergence profile was made buccally to avoid compressing the tissues.



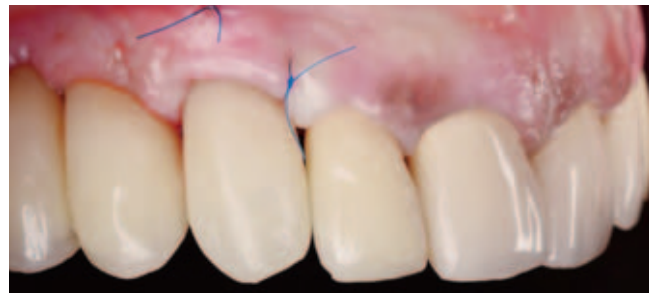**Fig. 6-13** A straight or slightly convex emergence profile was made in the proximal areas to support the interdental papillae.



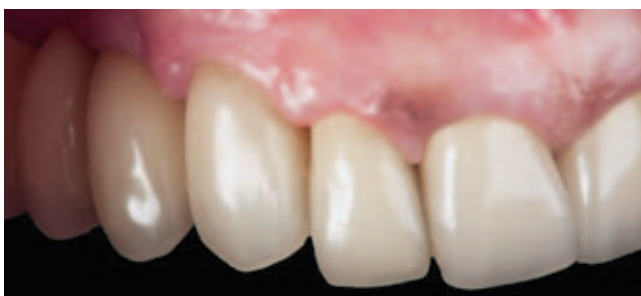**Fig. 6-14** Once polished the screw-retained temporary crown is ready to be inserted.



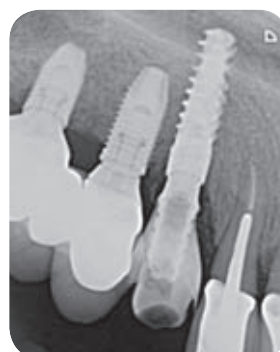**Fig. 6-15** A connective tissue graft is harvested from the tuberosity. It is placed over the surgical site to adjust its size and anticipate its positioning.



**Fig. 6-16** The connective tissue graft is sutured to support the gingival margin and preserve soft tissue volume. The temporary crown is placed to support the tissues in their ideal position.



**Fig. 6-17** View 4 months after the surgery.



**Fig. 6-18** Control radiograph at 4 months.



## Clinical situation 7

### The concept of strategic extractions

The transition to complete or multiple widespread missing teeth are often situations in which stabilizing a surgical guide is complicated. Tooth-supported guides obtained by merging data from a digital model and a CT scan are more reliable in their positioning than guides with bone or mucosal support. In the situation presented here, the patient presents with many teeth still in the mouth, but none of them are

salvageable. Precise planning makes it possible to select certain strategic teeth that are not located in the implant sites and that will be kept during surgery for the sole purpose of stabilizing the surgical guide. This makes it possible to stabilize a guide with a purely dental support and therefore to benefit from guided surgery of high precision.

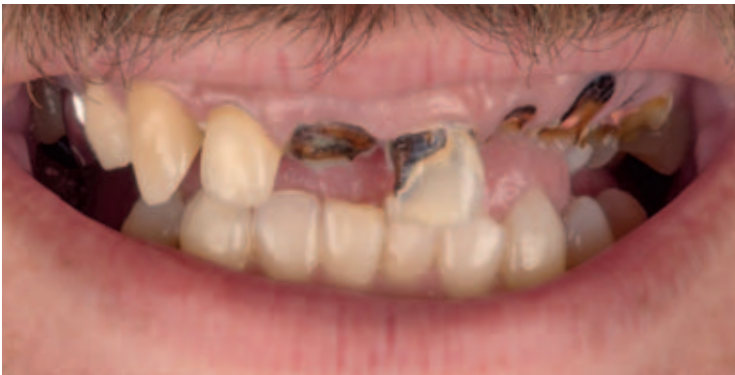

Fig. 7-1 Initial view of the smile.

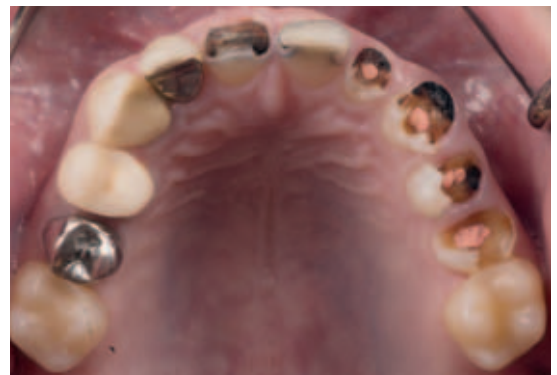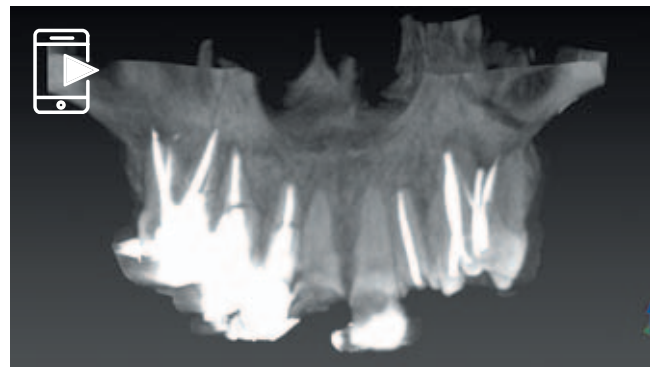


Fig. 7-2 Preoperative occlusal view.

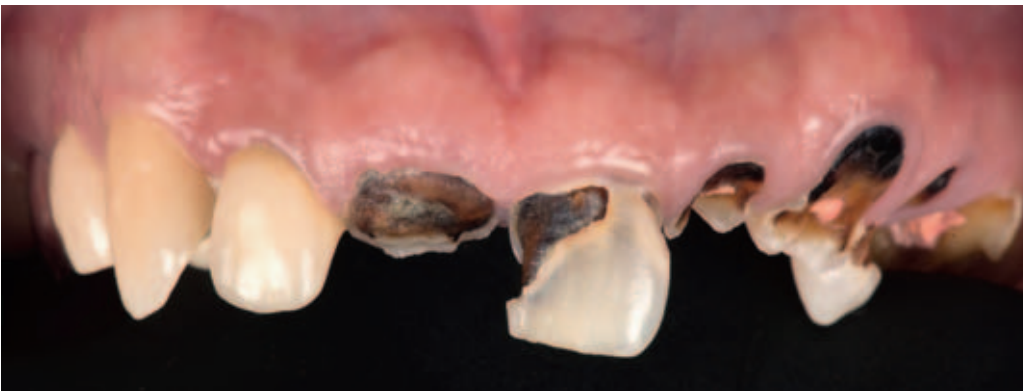

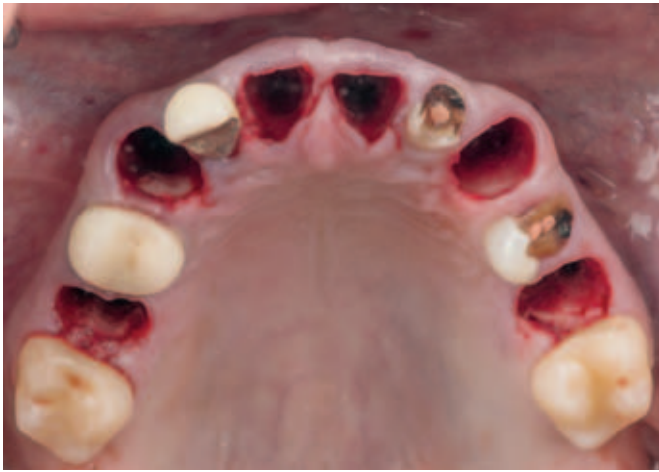Fig. 7-3 Initial intra-oral view.

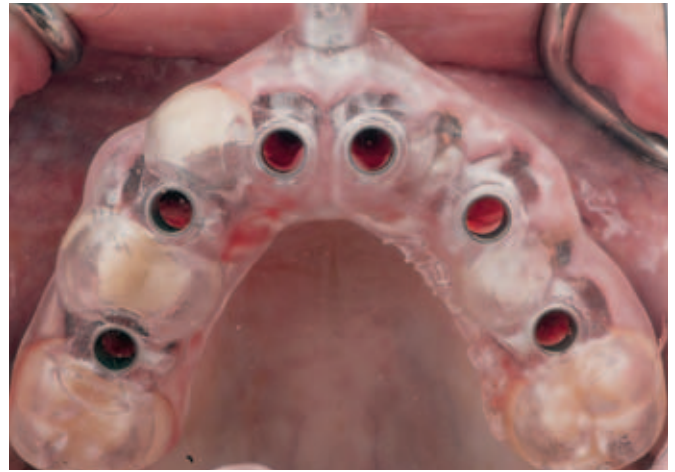**Fig. 7-4** Planning for strategic extractions: the initial model is prepared so as to leave the teeth supporting the future surgical guide in place; all teeth located at the implant sites are removed. Planning can then be carried out in a conventional way.



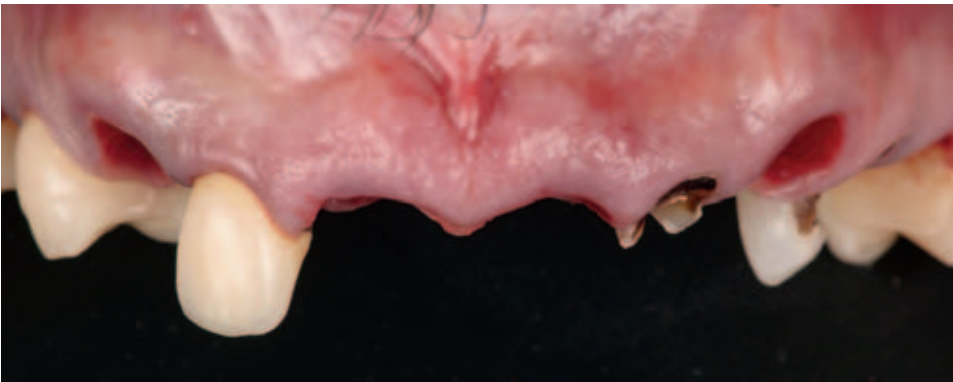
## Clinical situation 7



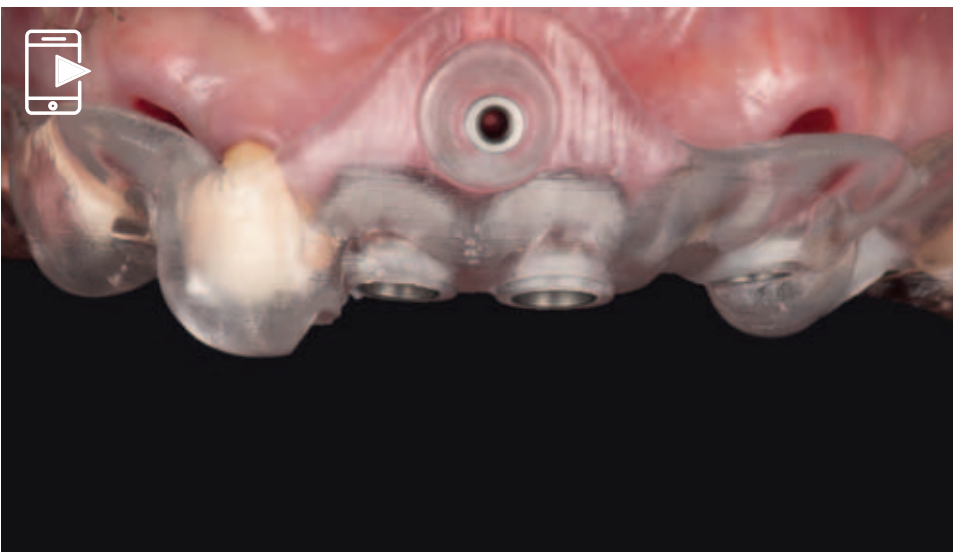
**Fig. 7-5** Extraction of teeth located in the implant sites. The remaining teeth will stabilize the surgical guide.



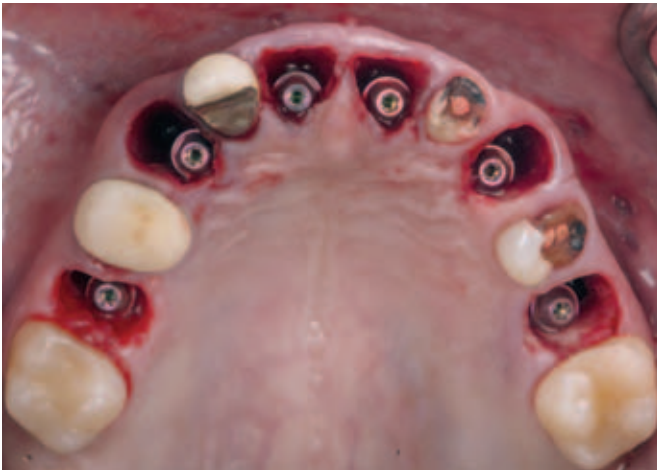**Fig. 7-6** Occlusal view of the tooth-supported surgical guide.



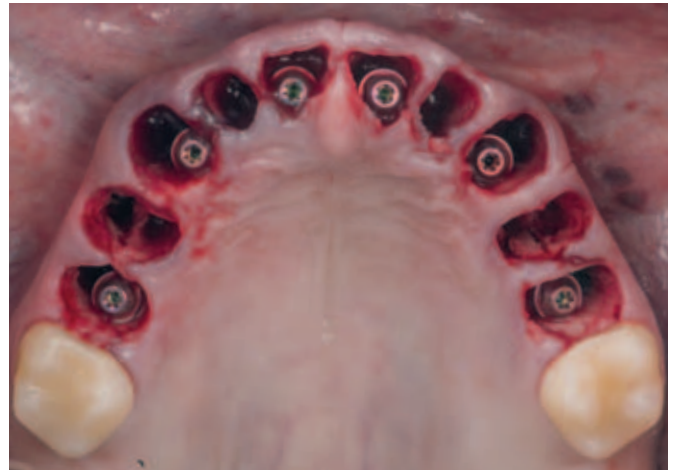**Fig. 7-7** Buccal view after extraction of the teeth located in the implant sites.



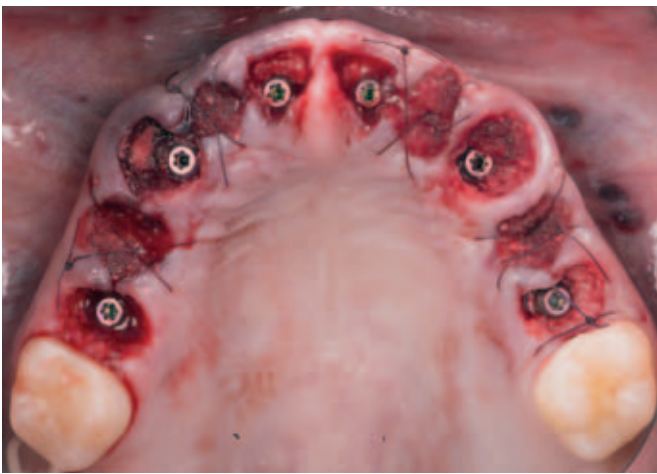**Fig. 7-8** Buccal view of the tooth-supported surgical guide.



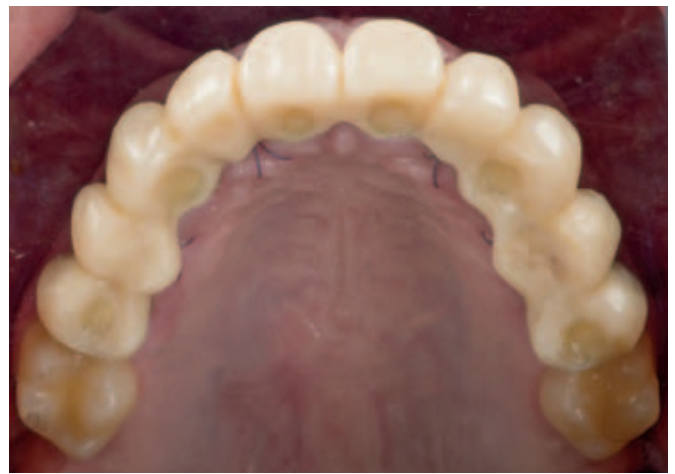**Fig. 7-9** Occlusal view after insertion of the implants and placement of the SRA abutments.



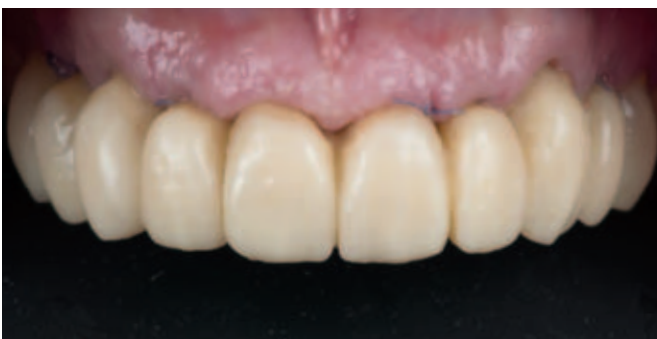**Fig. 7-10** The hopeless teeth are extracted at the end of the surgery.



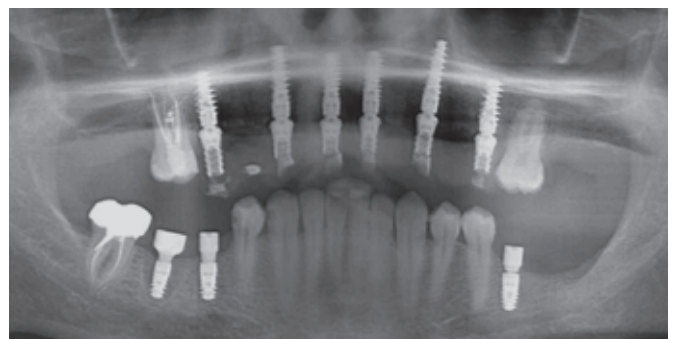
**Fig. 7-11** Occlusal view at the end of the surgery, after adding filler material in the sockets.



**Fig. 7-12** Occlusal view of the temporary bridge immediately placed a few hours after the surgery.



**Fig. 7-13** Buccal view of the temporary bridge immediately on the day of surgery (*Prosthetic work: Dr Louis Toussaint, laboratory: Julien Montenero*).



**Fig. 7-14** Post-operative radiograph showing the correct placement of the bridge.

## Clinical situation 8

### Treatment of a maxillary full arch with immediate loaded implants

The healing of Bone Level implants under a complete removable denture is not an ideal situation because it can lead to bone resorption around the implants, exposure of the cover screws, or even implant failure. Immediate loading is a protocol that, in addition to the comfort provided to

the patient, helps to make the treatment more reliable. The success of this type of procedure depends on obtaining sufficient primary stability as well as an accurate and efficient protocol for taking the impression and making the immediate temporary bridge.

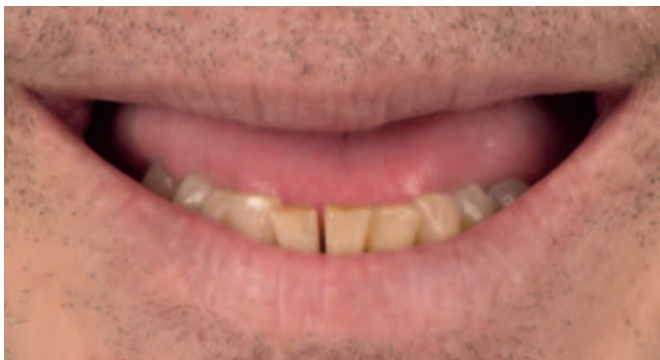

Fig. 8-1 Initial clinical situation.

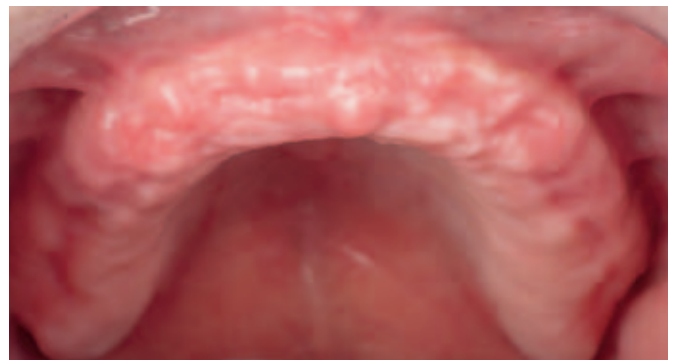

Fig. 8-2 Preoperative condition.

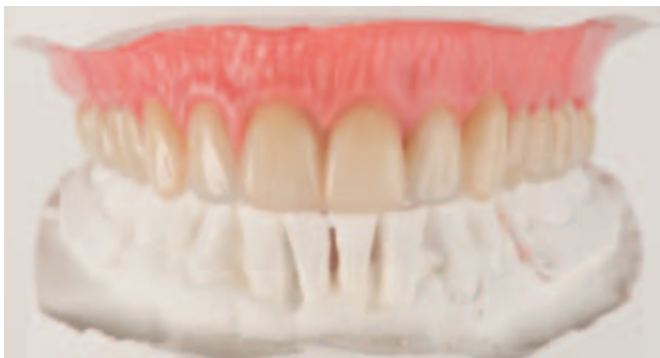

Fig. 8-3 Prior to the implant treatment a new set up is done and validated with the patient.

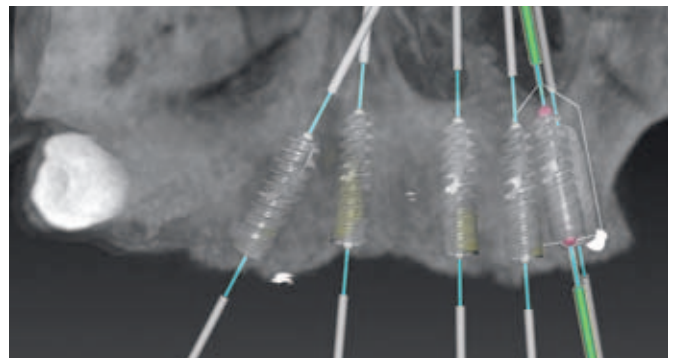


Fig. 8-4 Preoperative implant planning: two implants are angulated along the anterior sinus wall to avoid a sinus lift procedure.

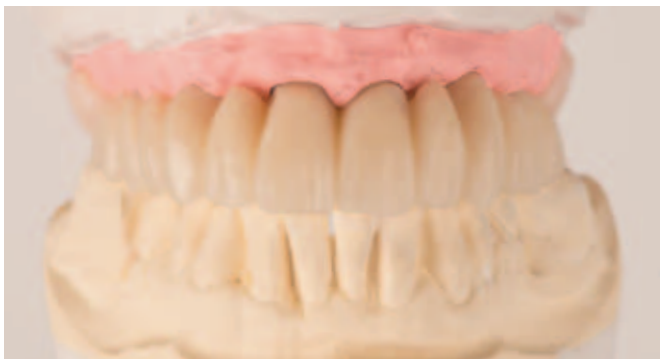

Fig. 8-5 A CAD/CAM temporary restoration is designed and milled.

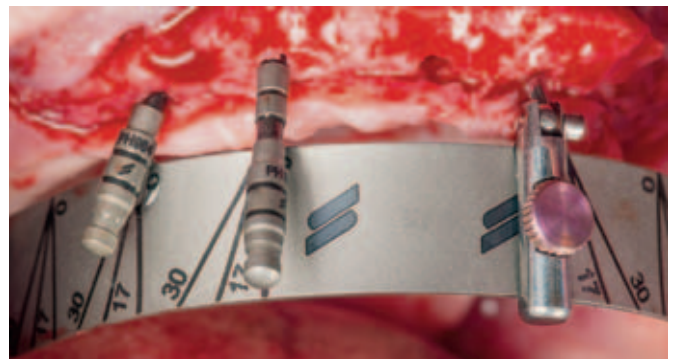
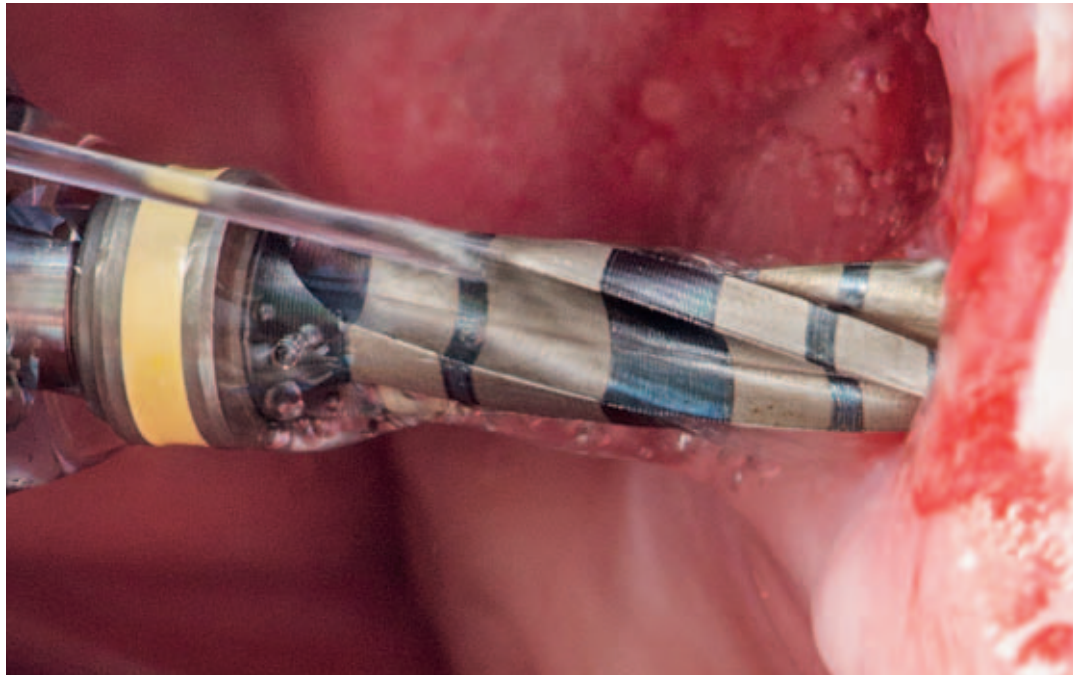
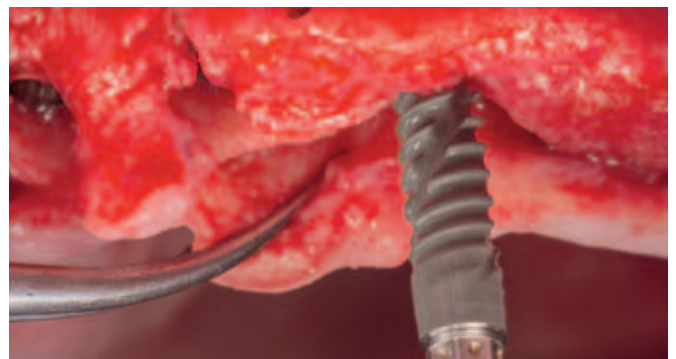
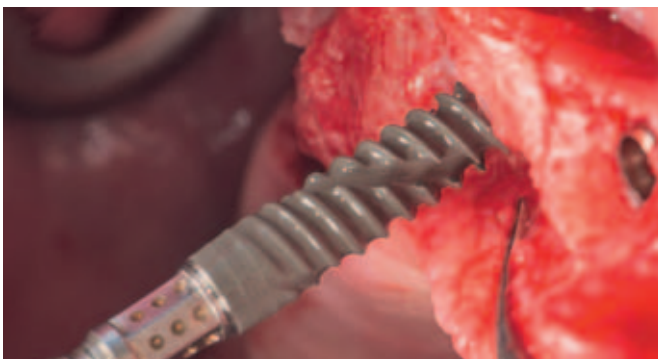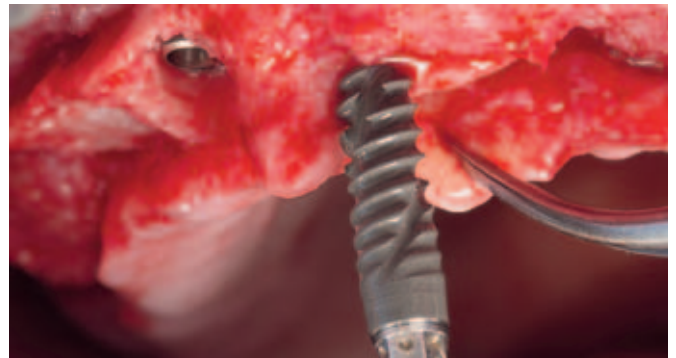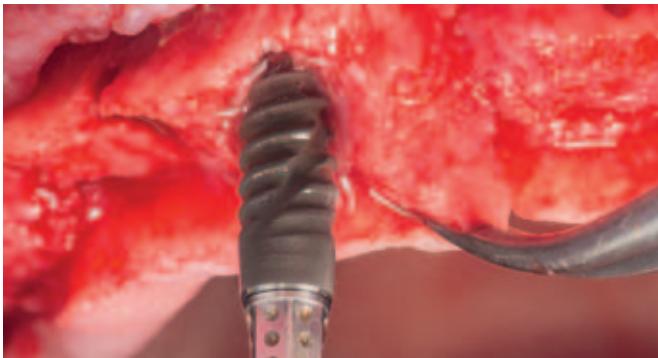Fig. 8-6 The angulation of distal implants is checked using the direction indicators and the Proarch Guide®.

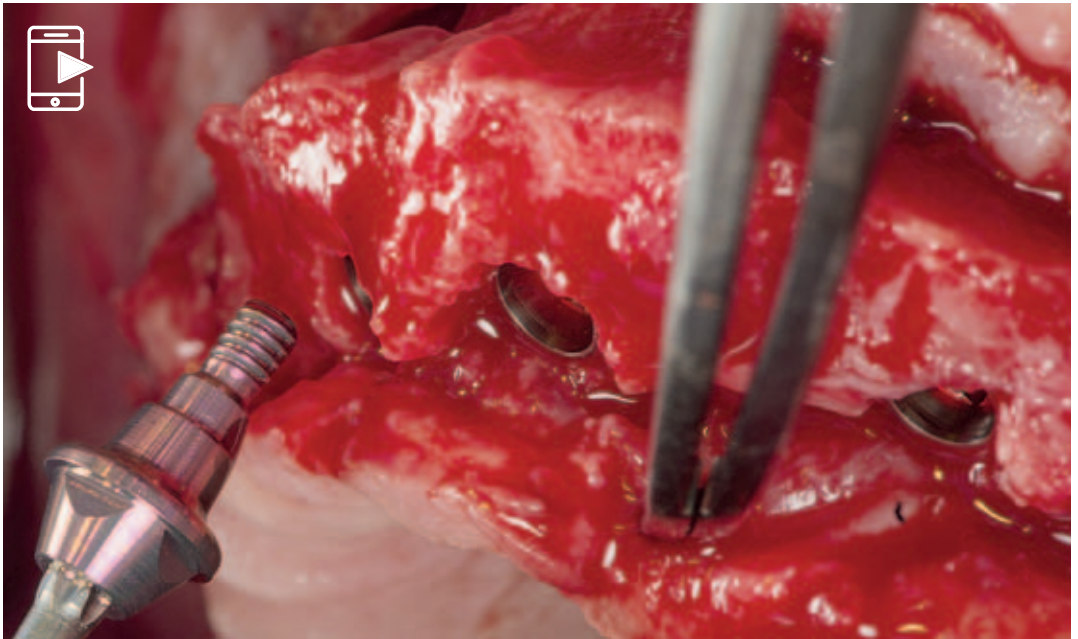


**Fig. 8-7** Osteotomy with BLX® Drill No.2 (ø2.8 mm).

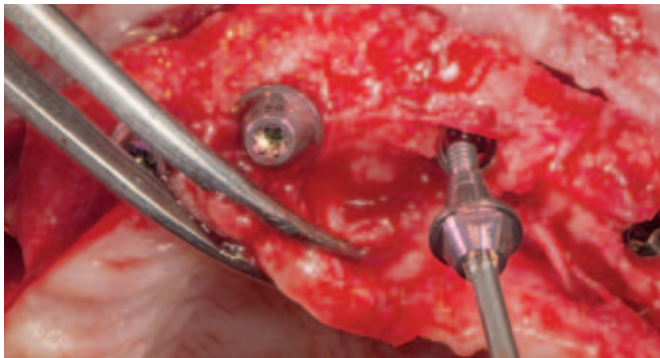

**Fig. 8-8 to 8-11** BLX implants placement with insertion torque value between 35 and 45 Ncm.

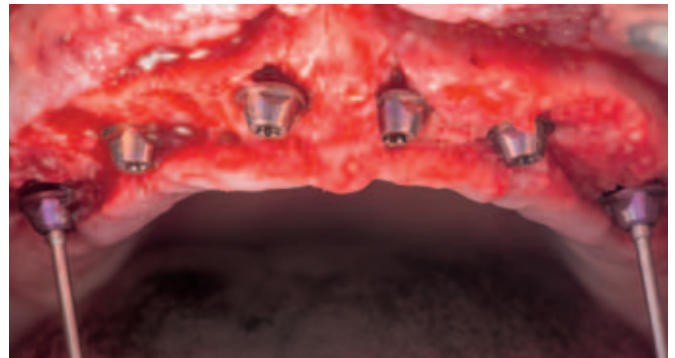
Clinical situation 8



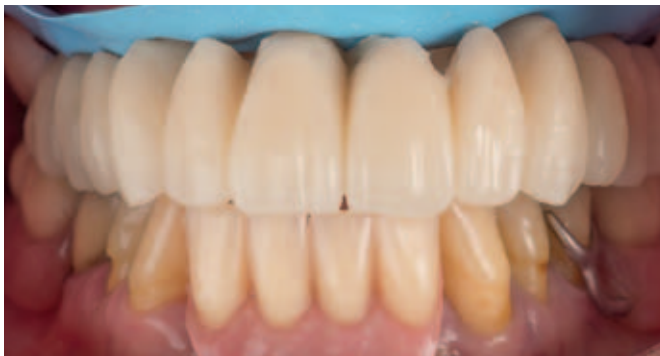**Fig. 8-12** SRA abutments are placed to correct axial discrepancies between implants and maintain a perfectly sealed connection at bone level.



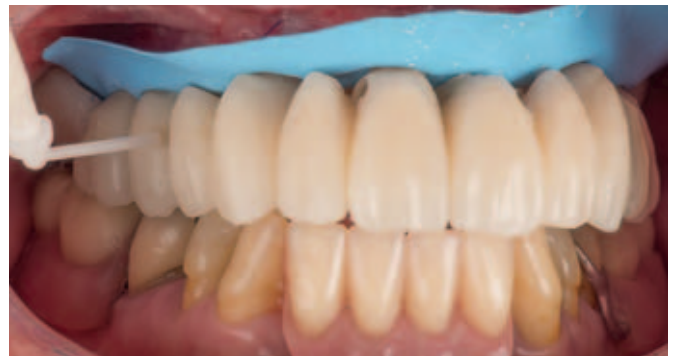**Fig. 8-13** It is important to verify the absence of bone interference when placing the SRA abutments.



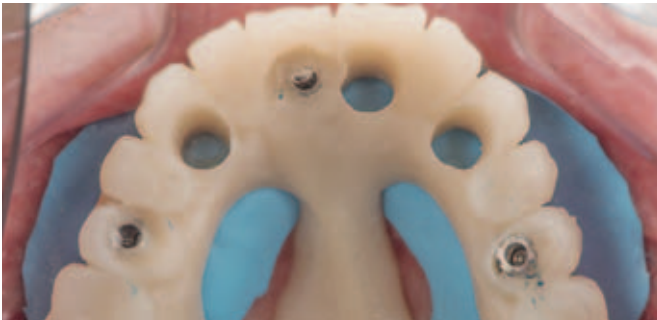**Fig. 8-14** Occlusal view with all SRA abutments correctly seated.



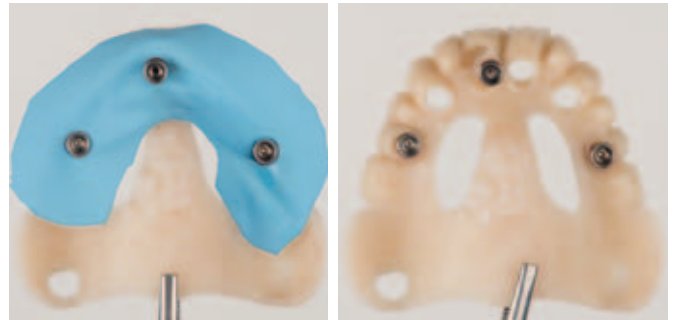
**Fig. 8-15** The CAD/CAM temporary restoration is positioned...



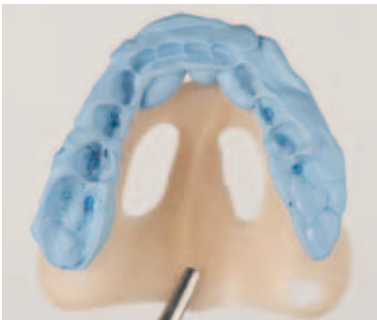**Fig. 8-16** and connected to 3 implants to avoid any displacement during occlusion adjustment and registration.



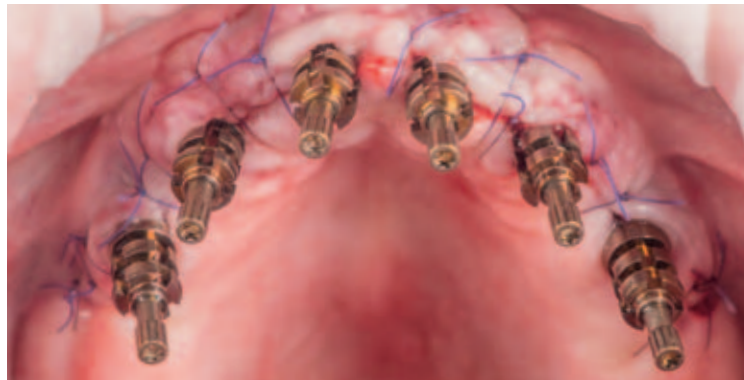**Fig. 8-17** Connection of the CAD/CAM temporary restoration and occlusal adjustments.



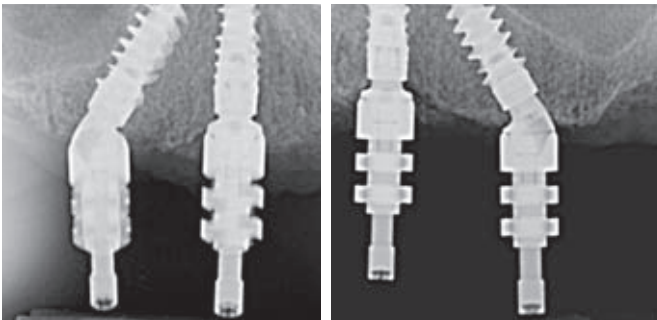
**Fig. 8-18 and 8-19** After the registration of the occlusion the CAD-CAM temporary restoration is sent to the lab.



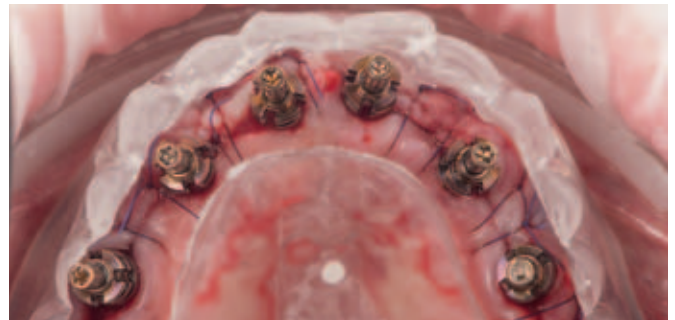**Fig. 8-20** The occlusion is registered with a silicone.



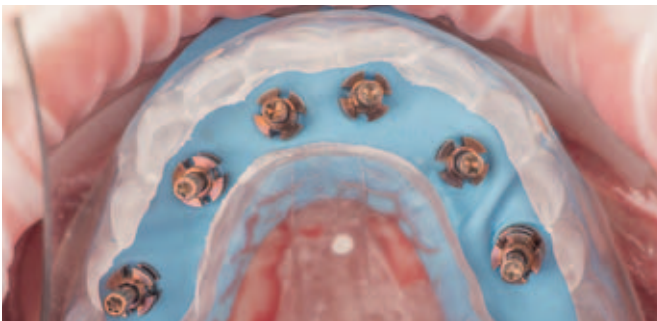**Fig. 8-21** Positioning of impression copings on SRA.



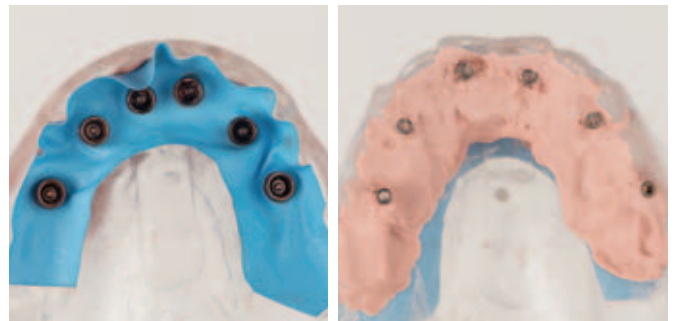
**Fig. 8-22 and 8-23** On these 2 x-rays, the benefits of using slim and under-contoured SRA abutments is obvious to avoid any bony interferences. This is a specificity of the BLX implant system.



**Fig. 8-24** A customized tray (duplicate of the complete denture) is hollowed out at the implants sites to register the position of the implants.



**Fig. 8-25** A piece of rubber dam is used to isolate the surgical wound.



**Fig. 8-26 and 8-27** Views of the inner side and of the outer side of the tray after impression with plaster.

## Clinical situation 8

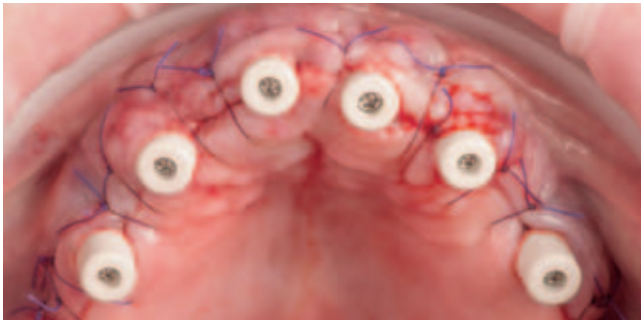


Fig. 8-28 Direct postoperative condition.

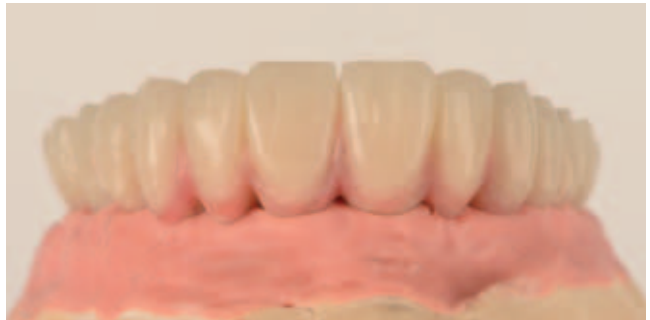

Fig. 8-29 The CAD/CAM temporary restoration is connected to all the implants by the technician.

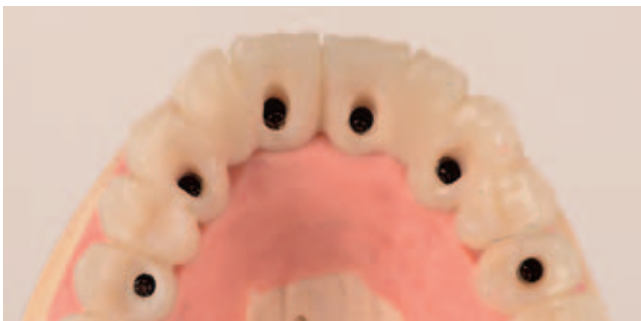


Fig. 8-30 and 8-31 Close-up of the CAD/CAM temporary restoration (Dental Technician: Julien Montenero).

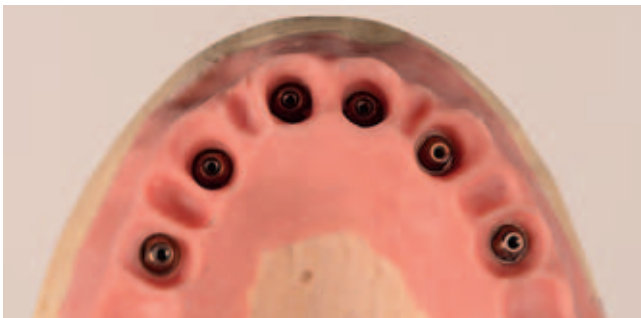
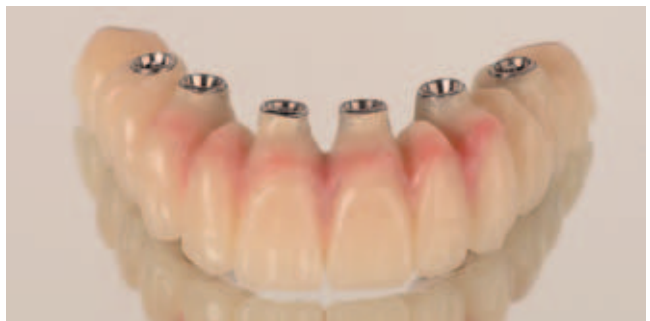
Fig. 8-32 Emergence profiles have been set-up on the master-model.

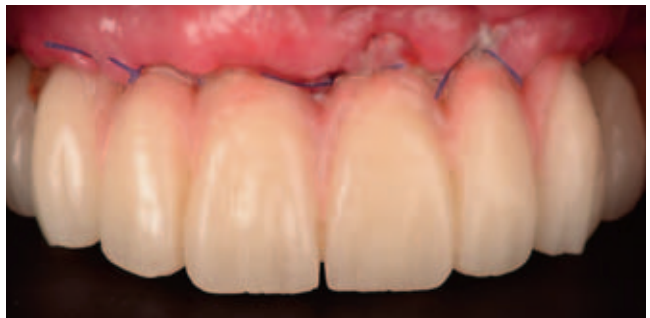

Fig. 8-33 Postoperative condition with the CAD/CAM temporary restoration fully seated.

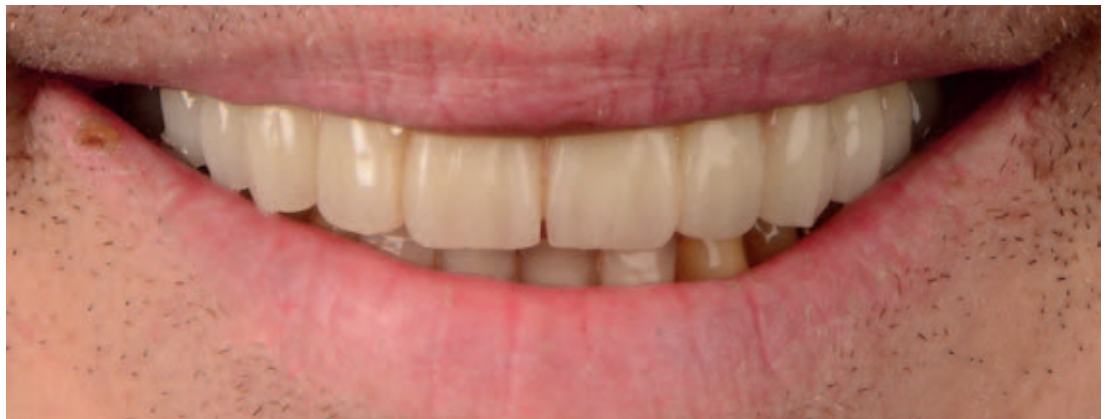

Fig. 8-34 Postoperative clinical situation.



# Immediate Loading in Single Crowns Using Straumann BLX and a Digital Workflow

One-Tooth One-Time technique description – Clinical case collection



## LOUWRENS SWART

BChD, MChD (MFOS), Private practice, Cape Town, South Africa.

@lcswart@mweb.co.za



## PAUL VAN ZYL

BChD, MChD (Prost), Private practice, Cape Town, South Africa.



## CHRISTIAN JARRY

DDS, MS, PhD, Oral Surgeon, Periodontist, Faculdade São Leopoldo Mandic, Brazil.



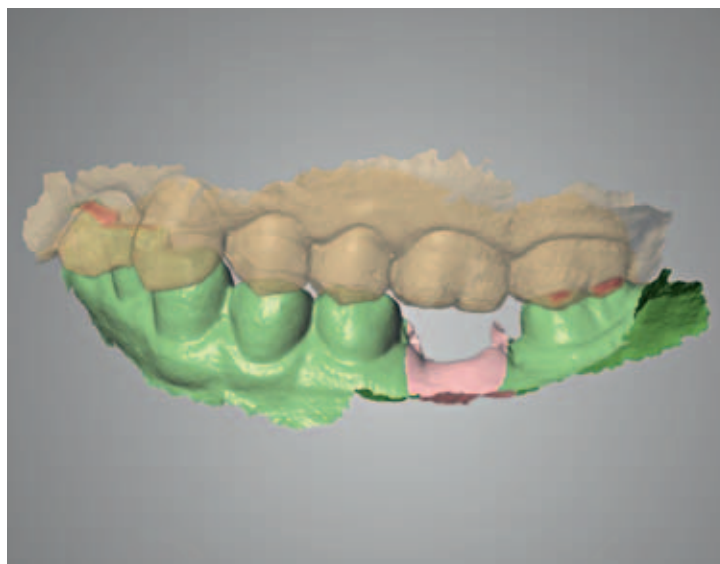
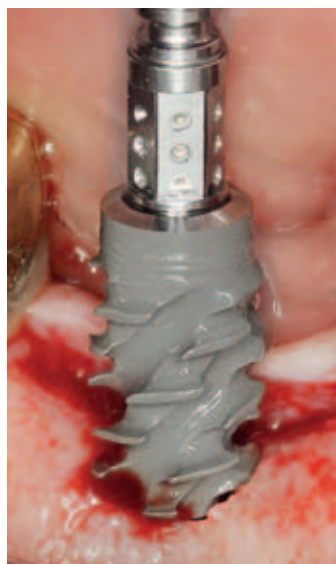## DIANA DE MACEDO

DDS, General Dentist, Oral Rehabilitation. Esthetic and Advanced Implantology Clinic, Lisbon.



## HUGO MADEIRA

DDS, Oral Surgeon, Implantologist. Esthetic and Advanced Implantology Clinic, Lisbon.



## INTRODUCTION

The immediate implant placement and loading of a prosthesis in an edentulous jaw is an accepted treatment modality in modern dental practice<sup>1-3</sup>. Historically, the accepted norm for the replacement of single tooth with an implant is to leave the implant either undisturbed and submerged under the mucosa or protruding through the mucosa with a healing cap for a period of eight weeks or longer<sup>4</sup>.

This approach is still the common surgical approach when primary stability cannot be achieved during surgery. Reduced treatment time is an attractive option for both the treating implantologist and the patient; thus, a single-stage surgical procedure and new loading protocols have been explored<sup>5</sup>. Important device-related factors that influence immediate loading and may contribute to achieving primary stability include the implant's overall design, the implant material, and implant surface modification<sup>6</sup>. All of these factors, as well as patient anatomy and bone quality, are prerequisites for loading<sup>7</sup>. The primary stability

of an implant that could be considered a subject for an immediate loading protocol, defined as a minimum of 35 Ncm torque and an ISQ of 60, can be achieved in soft bone by under-preparing the bone during osteotomy if a lateral compressive threaded implant is used. The medullary bone is thus compressed to deliver a greater bone-to-implant contact surface<sup>8</sup>. The bone's physiological response to trauma, the lateral forces and occlusal overload forces influence the immediately-loaded implant's stability, particularly in the first six weeks<sup>8</sup>. Furthermore, surface modification may lead to a shorter healing period, and therefore better stability<sup>9</sup>.

Immediate loading on single implants has been demonstrated as a valid treatment modality. However, most studies on single-implant immediate loading assess immediate provisionalization without occlusal or eccentric contact<sup>4</sup>. These implants are typically limited to the esthetic zone for patient convenience, as it eliminates the need to wear a removable prosthesis and negates the possible detrimental effects of pressure from the removable prosthesis on the soft tissue<sup>10</sup>.

Advanced technologies, such as 3D imaging, implant planning software, CAD/CAM technology and computer-guided and navigated implant surgery, have created new opportunities and identified possible risk factors, such as anatomical anomalies and bone density, making implant treatment outcomes much more predictable. Moreover, scanning and milling techniques have opened up a new landscape for implant dentistry, enabling implant prosthetic dentistry to take a major step forward. Digital workflows are increasingly used, particularly for single-unit restorations, and they allow for straightforward and cost-effective protocols that improve patient satisfaction. In 2016, Lambert and Mainjot proposed a chairside workflow for performing intraoral scanning (IOS) of implants immediately after surgery and for the manufacture of a single-unit resilient crown that would allow for the delivery of a final tooth on the same day and 15 days post surgery. One-year follow-up showed promising results, and the technique is described as One Tooth One Time (1T1T), a straightforward approach for the replacement of missing teeth in the posterior region<sup>11</sup>.

This article brings a collection of cases treated with One-Tooth One-Time (1T1T) technique using the new Straumann® BLX Implant system and digital workflow.

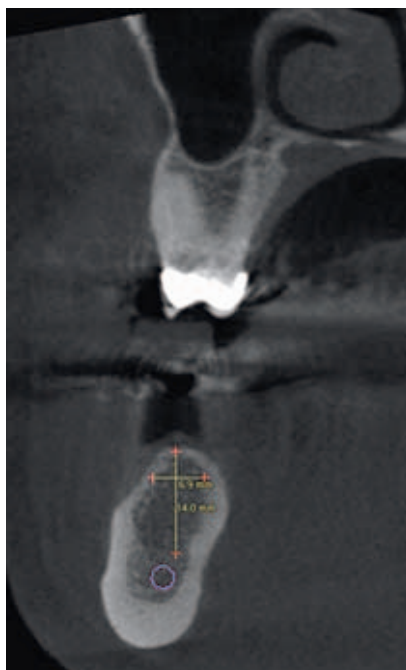
## TECHNIQUE GUIDELINES

This case collection gathered cases from a maxillofacial and oral surgeon's private office in Cape Town, South Africa, and in a second center in Lisbon, Portugal who already performs the technique routinely. The eight patients per center who were shown in this case collection sought routine treatment for the replacement of a missing mandibular molar with a dental implant. The patients had to meet the following inclusion criteria: 1) they had to have a single missing mandibular first molar tooth with opposing, as well as adjacent, natural teeth present; 2) presence of a balanced occlusion with no posterior interferences, with lateral excursions, with teeth on the opposing side to counteract an unbalanced occlusion; 3) they had to be in good overall health; 4) they had to have no obvious risk factors that could compromise healing, such as excessive tobacco use, diabetes or other debilitating diseases. Receiving and being aware of different treatment options all patients chose 1T1T and sign the respective treatment consent form.

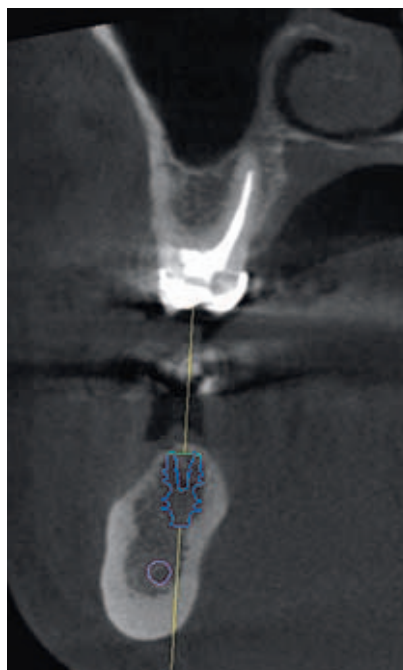
## PLANNING PHASE

It has been only collected cases of patients who presented an absent mandibular first molar tooth that could be restored with a dental implant. The implant had to have neighboring protective teeth in the anteroposterior relationship, and the immediate prosthesis would be placed in functional occlusion to the opposing dentition with the same principles of a final restoration placed on a single osseointegrated implant. A CBCT scan was taken pre-operatively to confirm a minimum of 10 mm of vertical bone between the inferior alveolar nerve and the coronal cortical margin of the mandible, as well as a minimum bone width of 6 mm (Fig. 1 and 2). Any pathology or abnormal anatomic variations making implant placement difficult or impossible were eliminated.

Alternative treatment options were discussed with each patient, including the delayed placement of the final prosthesis with either submerged or non-submerged healing. All patients included in this sample opted for the treatment plan, which consisted of placing a dental implant in the first mandibular molar area followed by immediate loading with the definitive prosthesis. If soft bone



**Fig. 1** CBCT scan image to assess anatomical availability.



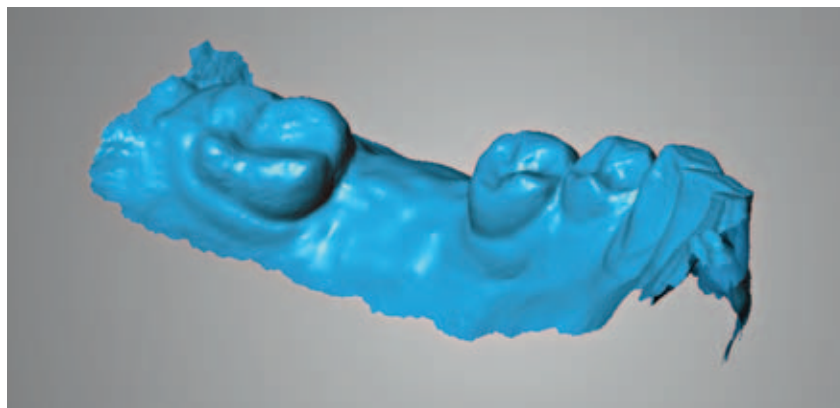
**Fig. 2** CBCT scan image with implant selected in planning phase.

was suspected from the CBCT and then confirmed clinically during surgery, the surgeon's skill level ensured primary stability by means of under preparation of the osteotomy.

The same surgeon performed all the surgical procedures per implant center and used the same prosthodontic practice for the final prostheses. Furthermore, the same dental technician performed all the laboratory work per implant center. A pre-operative digital scan was performed to capture the occlusion and to shorten post-operative chair time (Fig. 3). The digital scan further facilitated pre-op preparation by eliminating any possible complications that could be expected at the time of prosthesis placement, such as overeruption of the opposing teeth or any obstacles in the placement path of the final prosthesis.

## SURGICAL PHASE

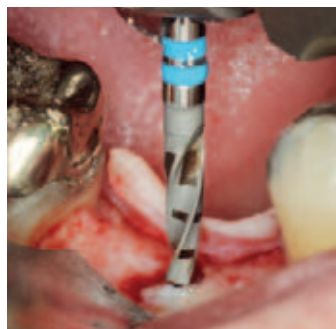As common procedure in both offices, the patients were treated under conscious sedation with local anesthetic, and routine sterile surgical procedures were followed. A flap was raised to expose the alveolar bone in the surgical area (Fig. 4). The ideal position for the implant was selected with



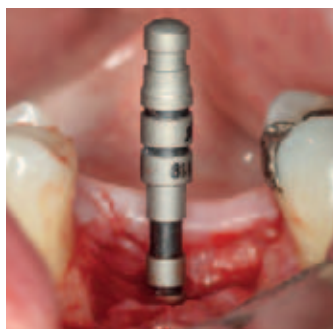**Fig. 3** Pre-operative digital model.

careful determination of the best 3D position via clinical assessment (Fig. 5 and 6). A pilot hole (2 mm) was drilled to determine the bone density (Fig. 7). A periapical X-ray was taken with the drill guide to confirm the ideal 3D position and the preparation depth (Fig. 8).

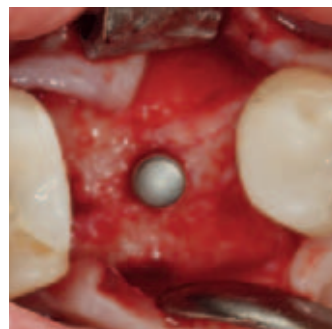
The width of the osteotomy was defined following clinical evaluation of bone density. This ranged from only the 2 mm drill with widening of the cortical bone margin, in very soft bone (Fig. 9) to full preparation—determined by implant diameter (Fig. 10 to 12)—in very hard bone. The latter protocol was only indicated in a single case.



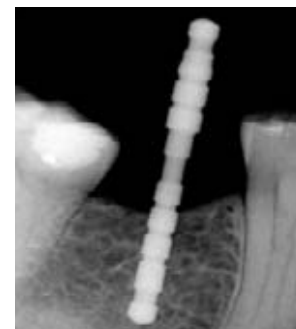**Fig. 4** Osteotomy with pilot drill – ( $\varnothing$ 2.2 mm).



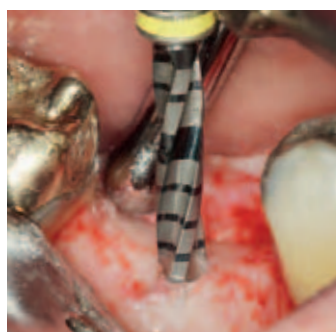
**Fig. 5** Tridimensional evaluation with alignment pin.



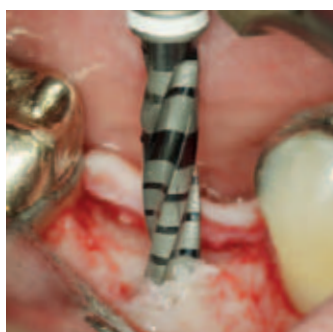**Fig. 6** Tridimensional evaluation with alignment pin – occlusal view.



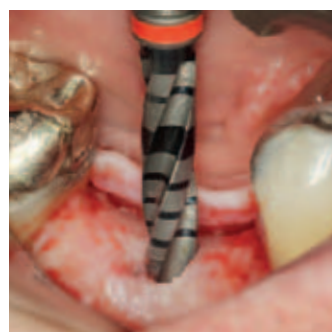**Fig. 7** Peri apical X-ray with alignment pin to confirm depth.



**Fig. 8** Osteotomy with BLX® Drill No.2 ( $\varnothing$ 2.8 mm).



**Fig. 9** Osteotomy with BLX® Drill No.3 ( $\varnothing$ 3.2 mm).



**Fig. 10** Osteotomy with BLX® Drill No.4 ( $\varnothing$ 3.5 mm).

The implant (BLX – Institut Straumann AG, Basel, Switzerland; Fig. 13) was then placed with a predetermined minimum insertion torque of 35 Ncm, however, all implants reached torque values between 40 Ncm and 60 Ncm. This implant has a very engaging tapered design and is manufactured from a titanium-zirconium alloy material (Roxolid®) with a hydrophilic surface (SLActive®).

The primary stability was further evaluated using the Implant Stability Quotient (ISQ) level (Osstell; Integration Diagnostics, Gothenburg, Sweden). A minimum measurement of 60 ISQ

was necessary for the implant to be sufficiently stable for immediate definitive loading. The healing abutment, with a diameter of 6.5 mm, was placed, and the initial neck height, either 1.5 or 2.5 mm, was individually determined by the coronal bone anatomy (Fig. 14).

A-PRF membranes were placed on the buccal surface of all implants to aid soft tissue healing (Fig. 15). Sutures were placed to create a soft tissue seal around the implant (Fig. 16). The patient was then transferred to the private office of the prosthodontic practice.

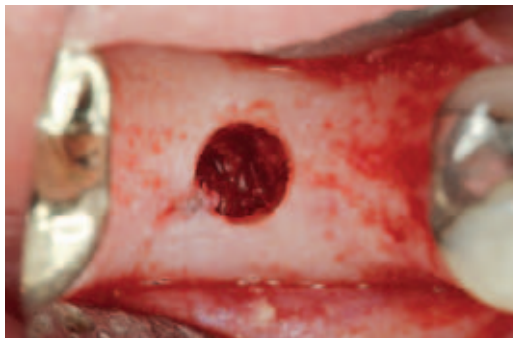


Fig. 11 Soft bone type visible below the crestal bone.

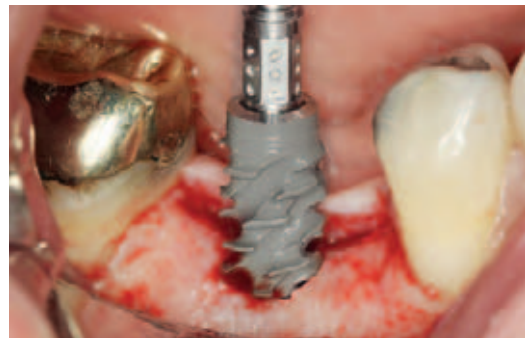


Fig. 12 BLX implant in position for placement.

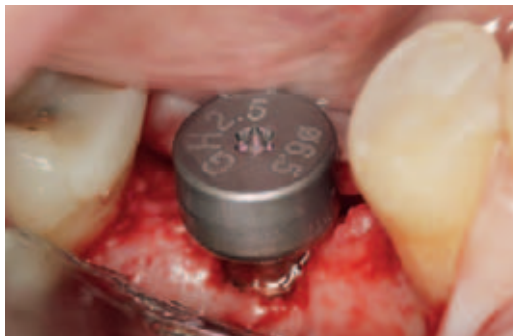

Fig. 13  $\varnothing$ 6.5 mm BLX Healing abutment in position.

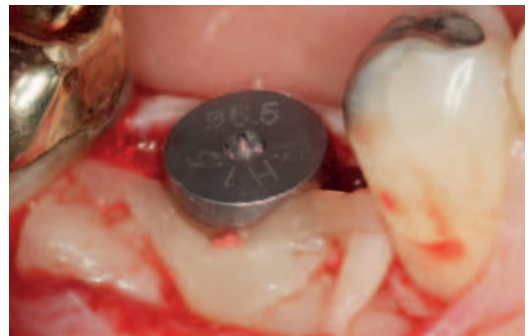


Fig. 14 L-PRF membrane placement.

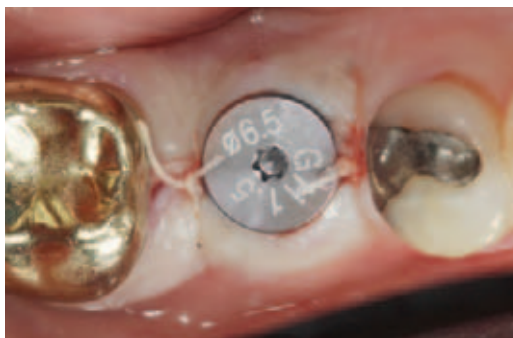

Fig. 15 Surgical site sutured.

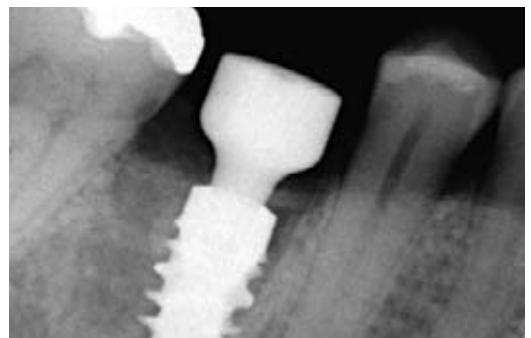


Fig. 16 X-Ray confirming no interference of the bone towards the Healing abutment seating.

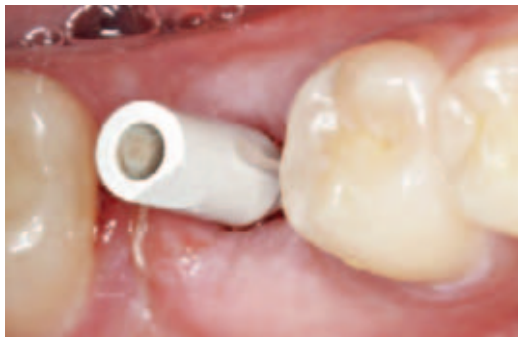

Fig. 17 RB/WB Mono Scanbody in position.

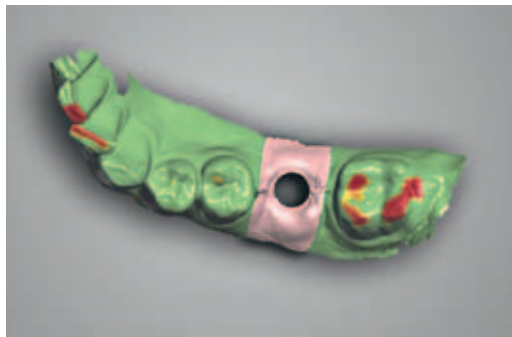


Fig. 18 Partial Digital model – Occusal view.

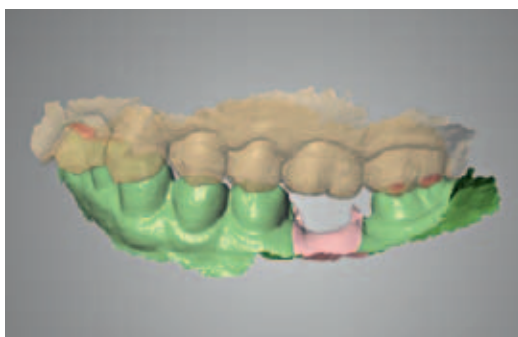

Fig. 19 Partial superior and inferior digital model in occlusion.



Fig. 20 Variobase® RB/WB preparation for cementation.

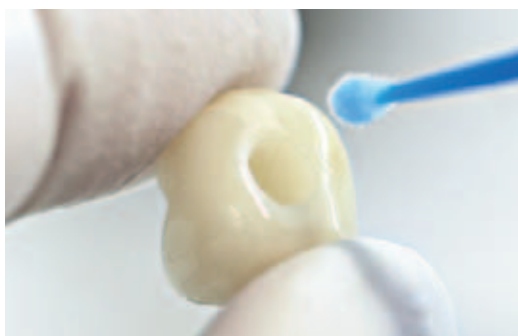

Fig. 21 Milled Crown over a Straumann® N!ce™ block.



Fig. 22 Self Curing cement applied on a Variobase® RB/WB.

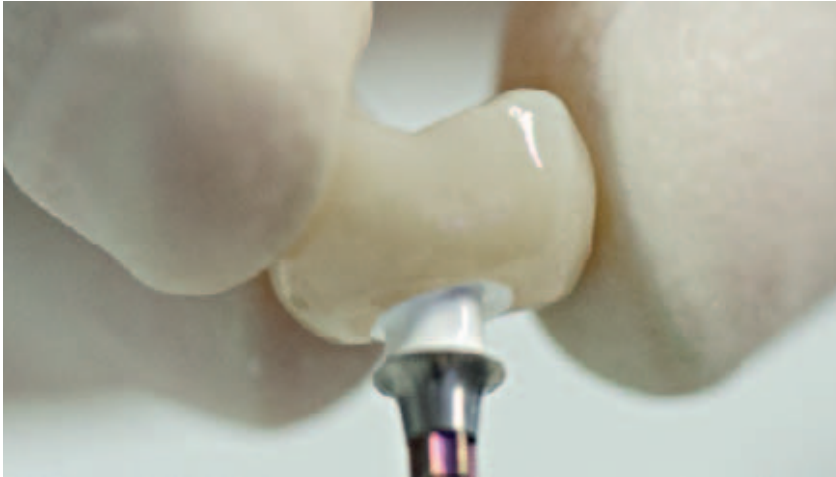## PROSTHETIC PHASE

The prosthodontic and technical work followed a digitized approach that included a DW intraoral scanner (IOS; TRIOS Pod, 3Shape, Copenhagen, Denmark) and CAD/CAM processing using Straumann CARES® Digital Solutions (Dental Wings®, Montreal, Canada) and a prefabricated titanium abutment (Variobase, Institut Straumann AG, Basel, Switzerland).

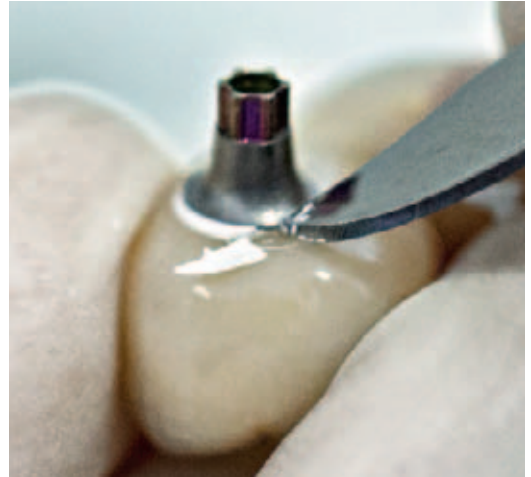The IOS captured the peri-implant mucosal architecture, including the neighboring teeth, in a quadrant-like approach. Then, a monotype scanbody was screwed into the implant (Fig. 17), and

the 3D implant position was determined (Fig. 18). The corresponding opposite arch was scanned in the same way. Finally, the bite recording was also digitally transferred (Fig. 19).

The final implant crown was planned as a screw-retained monolithic restoration, either from a lithiumdisilicate (LS2) CAD/CAM-blank (N!ce™ CAD, Institut Straumann AG, Basel, Switzerland) (Fig. 20) or a dental hybrid ceramic (Vita Enamic IS-16L, Vita Zahnfabrik, Bad Säckingen, Germany) (Fig. 21) and bonded with Ivoclar composite luting cement to a pre-fabricated titanium abutment (BLX Variobase, Institut Straumann AG, Basel, Switzerland) (Fig. 22).



**Fig. 23** Crown cementation on a Variobase® RB/WB.



**Fig. 24** Removal of cement excess after final curing.



**Fig. 25** Steam cleaning.

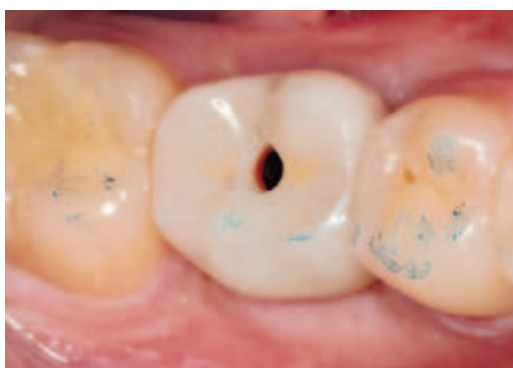Based on the .STL file from the IOS, the anatomically full-contoured shape of the crown was designed and produced digitally without any physical models or casting. Interproximal and occlusal contacts were defined virtually according to the threshold settings of the dental design software for chairside solutions (CARES® C-Series, Institut Straumann AG, Basel, Switzerland; **Fig. 23**).

The virtual crown design was processed and produced with 4-axis wet milling and grinding equipment (CARES® C-Series, Institut Straumann

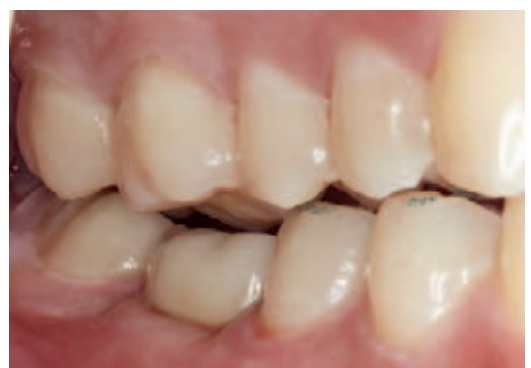AG, Basel, Switzerland) for in-house manufacturing out of a monolithic LS2 CAD/CAM-blank (N!ce™ CAD, Institut Straumann AG, Basel, Switzerland) or a dental hybrid ceramic (Vita Enamic IS-16L, Vita Zahnfabrik, Bad Säckingen, Germany).

After the monolithic LS2 or dental hybrid ceramic crowns were milled, the restoration was cleaned with 95% ethanol and, after further post-processing, polished and individually characterized. Then, the prepared LS2 or dental hybrid ceramic crown was directly bonded to the prefabricated titanium abutment (BLX Variobase, Institut Straumann AG, Basel, Switzerland) extra-orally (Multilink Implant, Ivoclar, Vivadent, Schaan, Liechtenstein; **Fig. 24**).

First the interproximal fit, and then the marginal integrity of the restoration, were clinically assessed (**Fig. 25**). Identical continuity with dental floss was separately checked for the mesial and distal contact surfaces. Next, the occlusal scheme was checked statically and dynamically with Shimstock foil, achieving light occlusal contacts



**Fig. 26** Final crown in position – Occlusal view.



**Fig. 27** Final crown in position – Lateral view no occlusion.

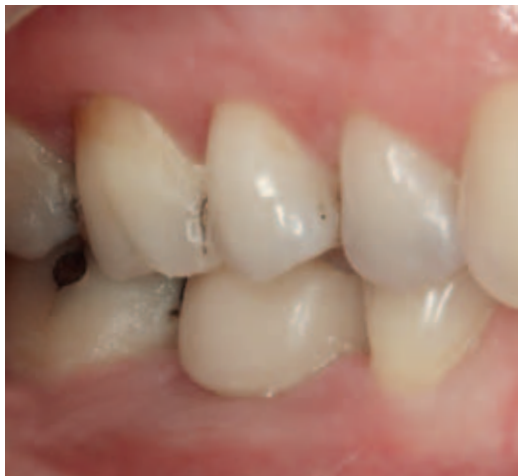

Fig. 28 Final crown in position – Lateral view in occlusion.

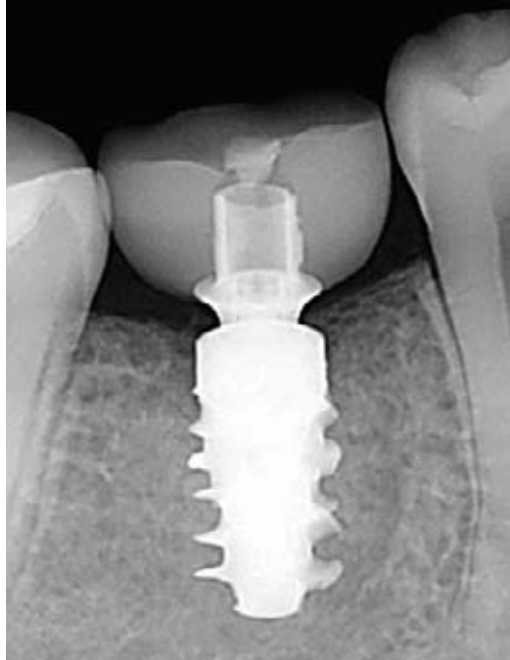

Fig. 29 X-ray with final crown in position.

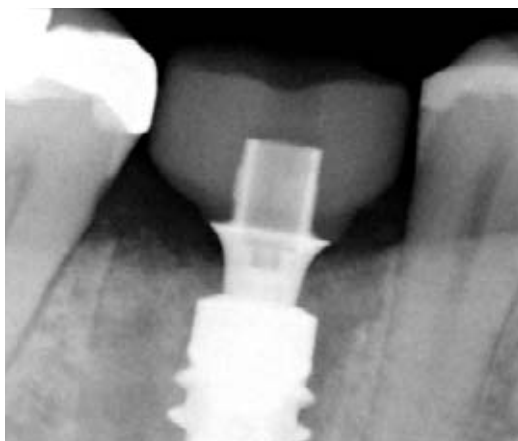

Fig. 30 One month follow up X-ray.

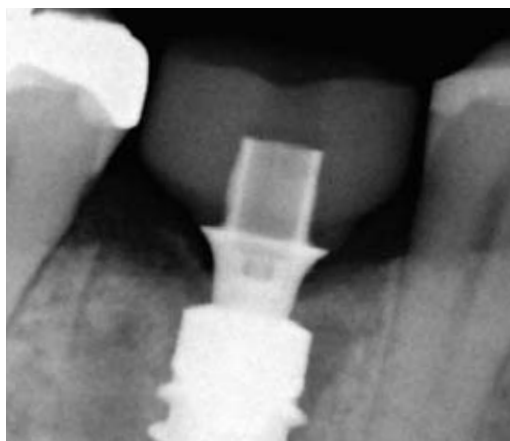


Fig. 31 Three months follow up X-ray.

without dynamic interactions (Fig. 26 and 27). The monolithic LS2 or dental hybrid ceramic restoration was screwed with a controlled torque of 35 Ncm, according to the implant provider's recommendations. The screw access hole was sealed with Teflon tape and composite restoration (Fig. 28). Periapical radiographs were used to check the position of the implants after the procedure (Fig. 29) and the prosthetic fit, upon placement and where possible within five hours; in some cases when surgery was planned for the afternoon, the placement was performed the following day (Fig. 30). The patients received follow-up examinations six weeks into the healing period to verify osseointegration (Fig. 31). Intraoral radiographs were standardized using a paralleling technique with Rinn holders. The radiographs used had to show clear implant threads without obvious distortion and display evenly-spaced and parallel threads.

## CONCLUSION

This case collection of posterior single molars brings light to the One-Tooth One-Time technique with the use of Straumann® BLX implants, designed for increased primary stability, to immediately place a definitive restoration on an implant in the molar region. The first requirement is that the implant should achieve primary stability, and thereafter a crown can be manufactured with full digital flow. This has the added advantage of no impression material ever coming into contact with the surgical wounds.

To place a definitive restoration on a primary stable implant using this technique, it is critical to select an implant design that will ensure primary stability and enhanced bone-to-implant contact. Fully tapered implants favor this outcome. The experience of the surgeon is also extremely

important in making the clinical decision of when to underprepare an osteotomy without causing the bone necrosis that might be expected due to excessive torque.

Digital implant dentistry will soon have an enormous impact on daily dental practice because of its precision in replicating the structures in the mouth. Analogue methods using traditional impressions often encounter inaccuracies. This new standard, as with all newly acquired knowledge, requires experience and familiarity with the products used. Even with these limitations, all crowns placed in this study could be torqued to 35 Ncm. While some adjustments to the occlusal and interproximal contacts were needed, this need will lessen over time with more experience.

This digital implant dentistry protocol could lead to more predictable results and a more efficient workflow, which will help control costs and

save time for both the patient and the dental team. Digital planning and processing will also make the dental implant treatment option much less burdensome and easier to deliver for the dental implant team and patient, thus improving global acceptability and utilization. As the digital dental age continues to evolve, it is predicted that dental implants will become the most common replacement option for missing teeth.

The 1T1T technique performed on the cases collected from the 2 centers treated 16 patients, each presenting a missing lower first molar treated with implants and restored with the definitive crown a few hours after the surgical procedure. This technique which has been demonstrated predictable in 2016 using a different implant system appears to be applicable in daily practice with Straumann® BLX system and its respective digital workflow.

## REFERENCES

1. Grunder U. Immediate functional loading of immediate implants in edentulous arches: Two-year results. *Int J Periodontics Restorative Dent* 2001; 21:545–51.
2. Windael S, Vervaeke S, Wijnen L, Jacquet W, De Bruyn H, Collaert B. Ten-year follow-up of dental implants used for immediate loading in the edentulous mandible: A prospective clinical study. *Clin Implant Dent Relat Res*. 2018 Aug;20(4):515–521. doi:10.1111/cid.12612. Epub 2018 May 23.
3. Swart LC, Dreyer WP, van Zyl PP, Blignaut RJ. Early loading of mandibular implants placed immediately after extraction: a 10-year prospective study of eight patients. *Int J Oral Maxillofac Implants*. 2014 Nov-Dec;29(6):1388–96. doi:10.11607/jomi.3670.
4. Kan JY, Rungcharassaeng K, Lozada. Immediate placement and provisionalization of maxillary anterior single implants: 1-year prospective study. *Int J Oral Maxillofac Implants*. 2003;18:31.
5. Swart LC, van Niekerk DJ. Simplifying the implant treatment for an unrestorable premolar with a one-piece implant: A clinical report. *J Prosthet Dent*. 2008 Aug;100(2):81–5. doi:10.1016/S0022-3913(08)00098-X.
6. Schrott A, Riggi-Heiniger M, Maruo K, Gallucci GO. Implant loading protocols for partially edentulous patients with extended edentulous sites—a systematic review and meta-analysis. *Int J Oral Maxillofac Implants*. 2014;29(Suppl):239–255. <https://doi.org/10.11607/jomi.2014suppl.g4.2>
7. Neugebauer J, Traini T, Thams U, Piattelli A, Zoller JE. Peri-implant bone organization under immediate loading state. Circularly polarized light analyses: A minipig study. *J Periodontology*. 2006;77(2):152–160.
8. Degidi M, Daprile G, Piattelli A. Influence of underpreparation on primary stability of implants inserted in poor quality bone sites: an in vitro study. *J Oral Maxillofac Surg*. 2015 Jun;73(6):1084–8.
9. Lang NP, Salvi GE, Huynh-Ba G, Ivanovski S, Donos N, Bosshardt DD. Early osseointegration to hydrophilic and hydrophobic implant surfaces in humans. *Clin Oral Implants Res*. 2011 Apr;22(4):349–56.
10. Chaushu G, Chaushu S, Tzohar A, et al. Immediate loading of single-tooth implants: Immediate vs. non-immediate implantation. A clinical report. *Int J Oral Maxillofac Implants*. 2001;16:267.
11. Lambert F, Mainjot A. One-Tooth One-Time (1T1T): A straightforward approach to replace missing teeth in the posterior region. *J Oral Implantol*. 2017 Oct;43(5):371–377.



# Replacement of a fractured central incisor with post-extractive BLX implant positioning and immediate prosthesis



## SERGIO PIANO

Visiting Assistant at the University of Geneva (Switzerland), in the Departments of Fixed Prosthodontics, Periodontology and Oral Surgery in 1991-92

ITI Fellow

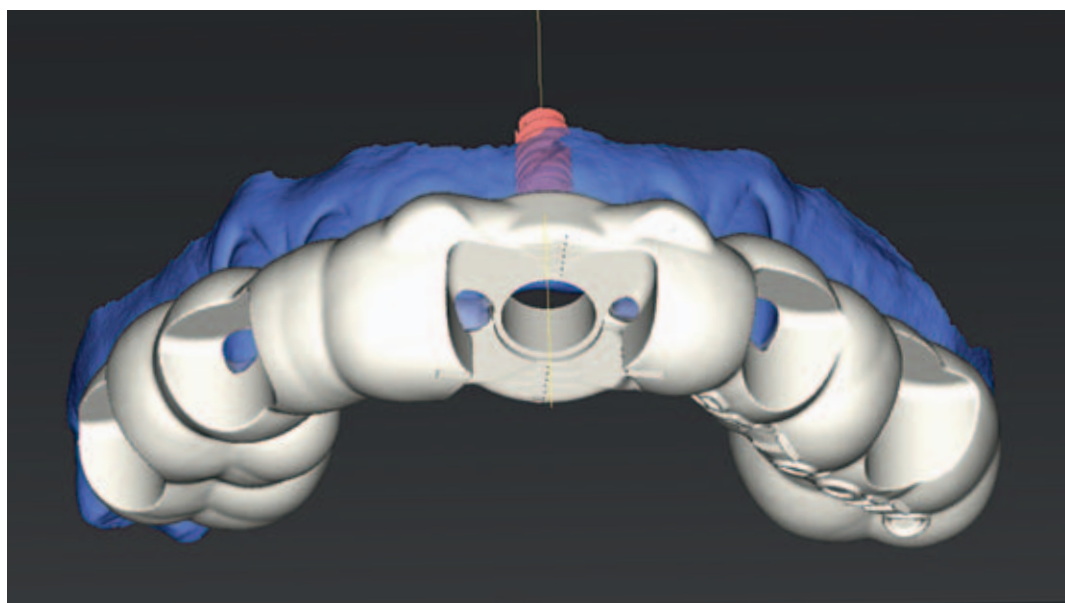
ITI Study Club Coordinator for the ITI Italian Section

Private Practitioner in Genoa, Italy

Dr. Piano is the author of several papers written in the area of Implantology.

He regularly lectures in Italy and abroad on surgical and prosthetic topics in Implantology

@ sergio.piano@tiscali.it



## INTRODUCTION

A 46-year-old suffered a trauma to her left upper central incisor while swimming. The tooth was fractured under the crestal bone and it was no longer possible to restore it (Fig. 1 and 2).

As the tooth had an aesthetic impact, our goal was to investigate possibility of placing an immediate post-extraction implant with an immediate

prosthesis to ensure, in every phase of the treatment, the presence of a fixed and aesthetically-satisfactory rehabilitation.

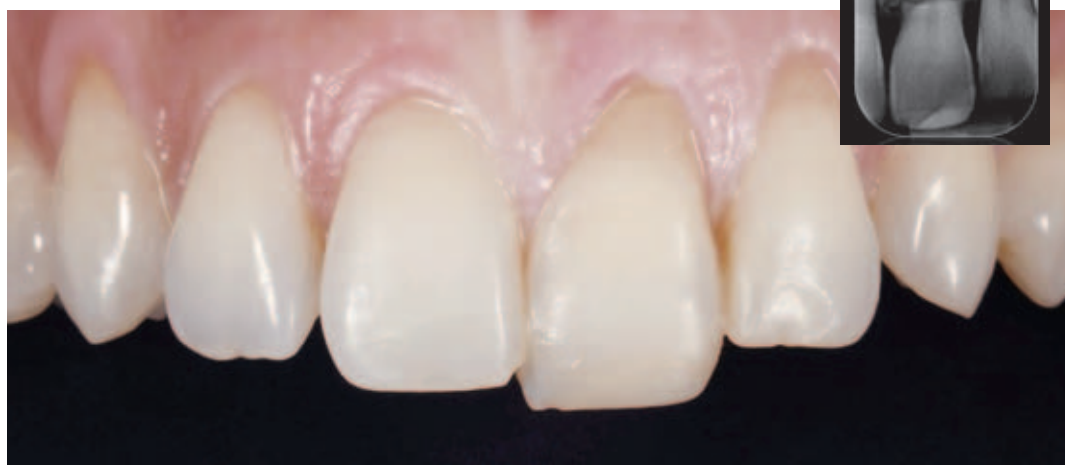

Fig. 2 The fractured 21 tooth due to trauma.

Fig. 1 Fracture line is clearly visible in the x-ray.

## DIGITAL PLANNING

To this end, a CBCT exam was requested to evaluate the bone anatomy around the teeth 21. The Dicom files were imported in coDiagnostiX planning software (Fig. 3); at the same time, an optical impression was taken with the DentalWings intraoral scanner and the Stl file was also imported in coDiagnostiX (Fig. 4). These files were aligned to visualize and analyze the case (Fig. 5).

The data showed (Fig. 6) significantly reduced bone volume at the apical side of the tooth, making the necessary implant stability very difficult to

achieve. In addition, there was a thin bone plate at the vestibular side of the tooth.

For this specific case, the use of a BLX implant was perfectly indicated, as it is possible to obtain a high level of primary stability with this type of implant, even in areas with reduced bone availability.

After accurate digital planning of the implant position from both the surgical and the prosthetic point of view (Fig. 7), a surgical stent was created (Fig. 8) for computer-guided implant positioning, outlining a partially-driven implant placement. The stent was then printed along with a

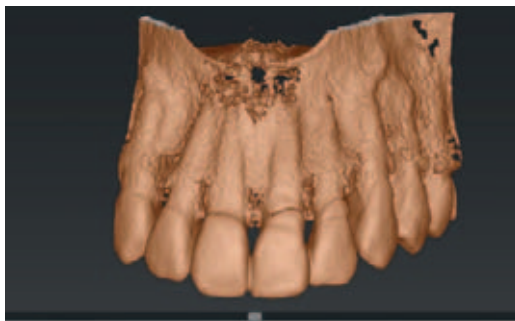

Fig. 3 CBCT exam done immediately after the trauma.

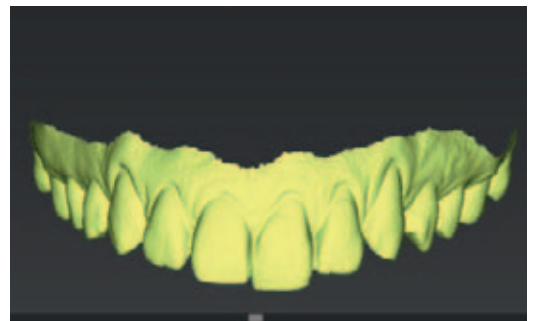


Fig. 4 Optical impression of the upper arch taken with Dental Wings® intraoral scanner.

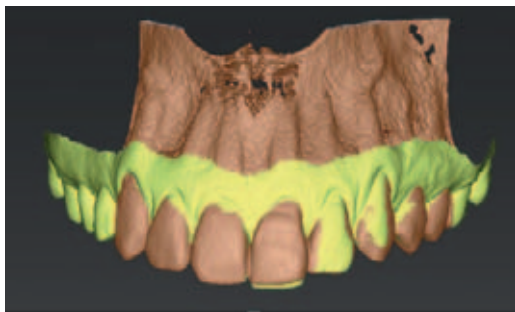


Fig. 5 Matching of the data in CoDiagnostiX planning software.

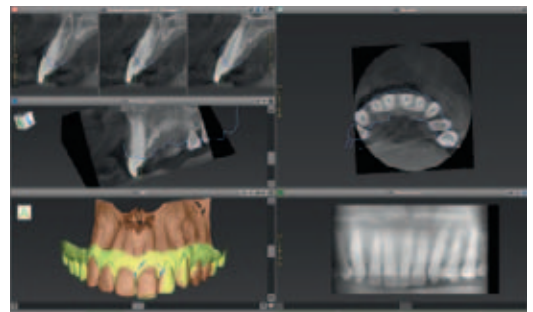


Fig. 6 Digital analysis of the case and choice of the correct implant position.

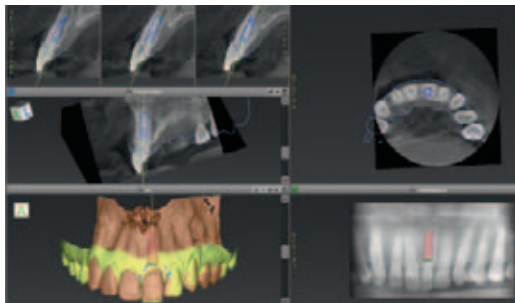


Fig. 7 Planning of the BLX implant placement in 21 post-extractive site.

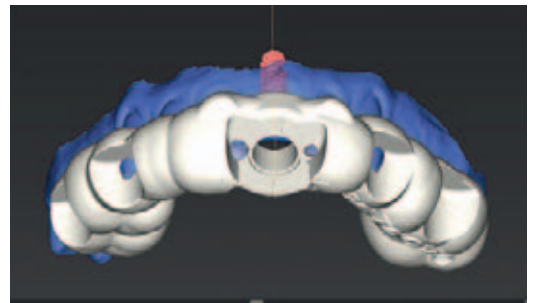
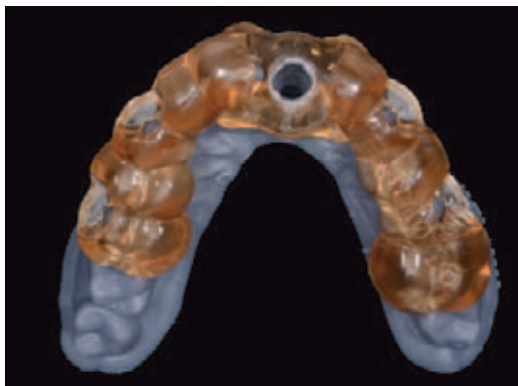
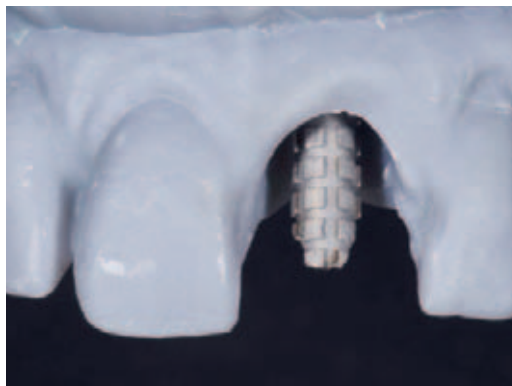


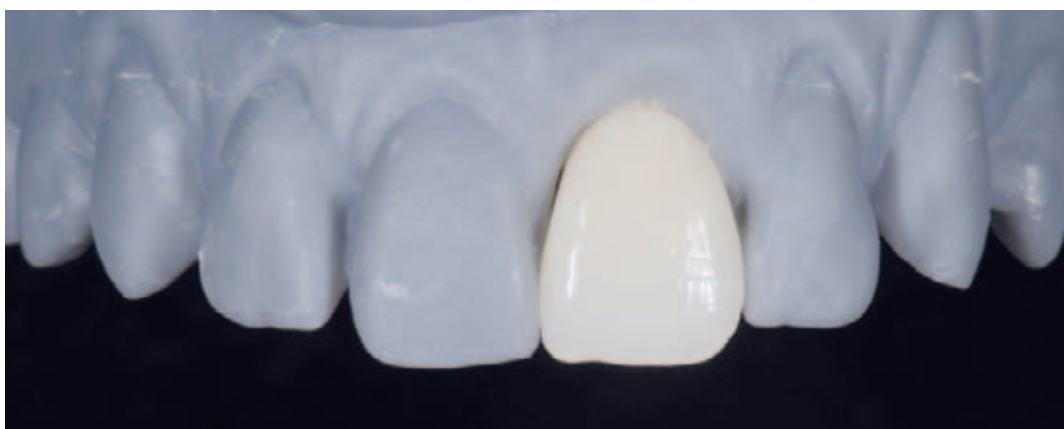Fig. 8 Design of the surgical stent for the computer-guided implant installation.



**Fig. 9** The stent and the resin model after the printing process.



**Fig. 10** The temporary abutment is modified in line with the crown shape.



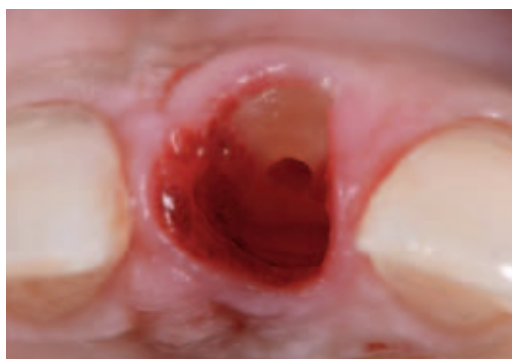**Fig. 11** Provisional crown to be connected to the abutment after the implant placement.

resin model simulating the clinical situation after extraction and implant installation (**Fig. 9**). Using this approach, the dental technician was able to produce a very precise provisional resin crown on tooth 21, to be finally connected to the temporary abutment after the placement of the implant (**Fig. 10 and 11**).

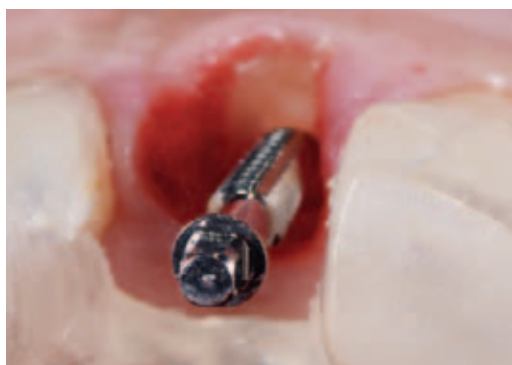## SURGICAL PHASE

During the surgical phase, the first step was to remove the fractured crown. As shown (**Fig. 12**), the next challenge was the extraction of the root: it is crucial not to damage the thin vestibular wall of the socket if the implant is to be immediately placed. For this reason, a special device (Exomed, Medesy, Italy) was used to pull out a screw previously placed into the root (**Fig. 13**). By slowly turning the device wheel connected to the screw (**Fig. 14**), the root was gently extracted (**Fig. 15**).

At this point, the guide was placed in the correct position (**Fig. 16**) and the drilling procedure was



**Fig. 12** The remaining root after the extraction of the dental crown.



**Fig. 13** Positioning of the dedicated screw for the extraction.

performed, driven by the guide, until the bur was at a diameter of 2.8mm (Fig. 17). The BLX implant was then placed without a strictly guided protocol, instead using only the stent as a reference

point (Fig. 18). The remaining space between the implant and the vestibular bone wall was finally filled with bone substitute material.

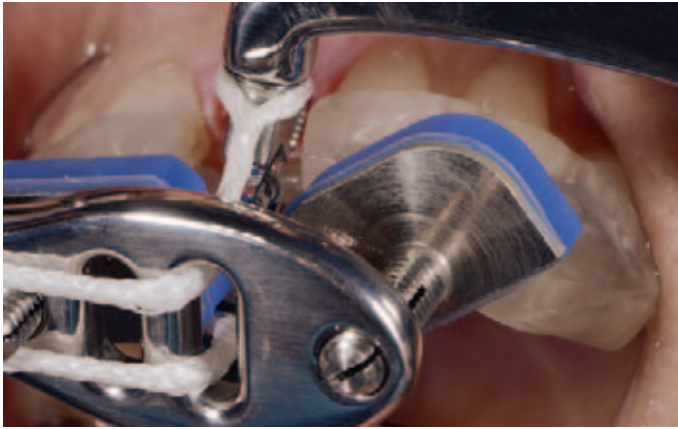

Fig. 14 The special device at work for the pulling out of the root.

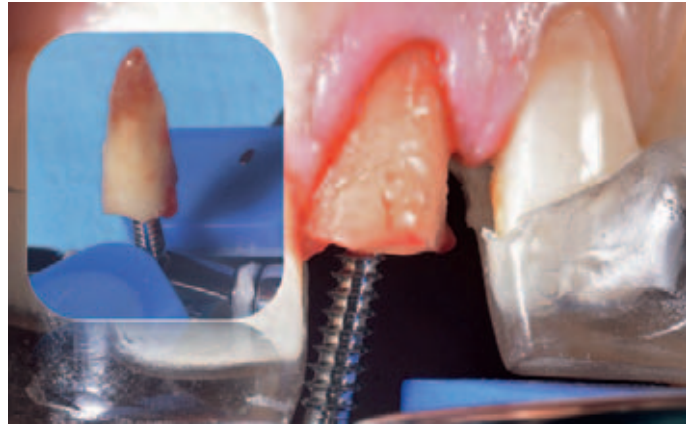


Fig. 15 After the slow traction, the root is gently extracted.

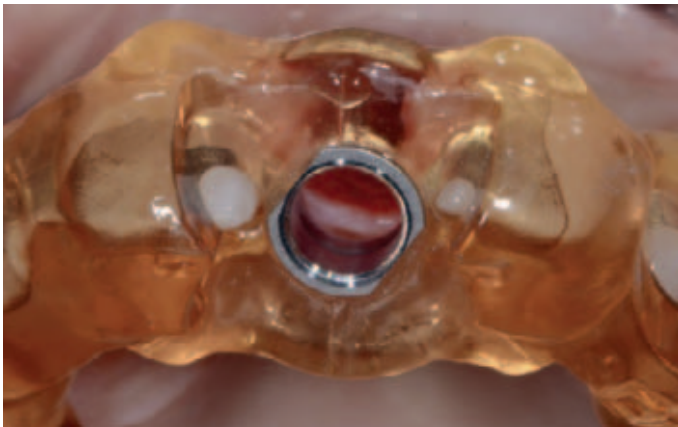

Fig. 16 The tooth-supported surgical stent is seated with great precision.



Fig. 17 The drilling procedure: the implant bed is prepared till the bur diameter 2.8.

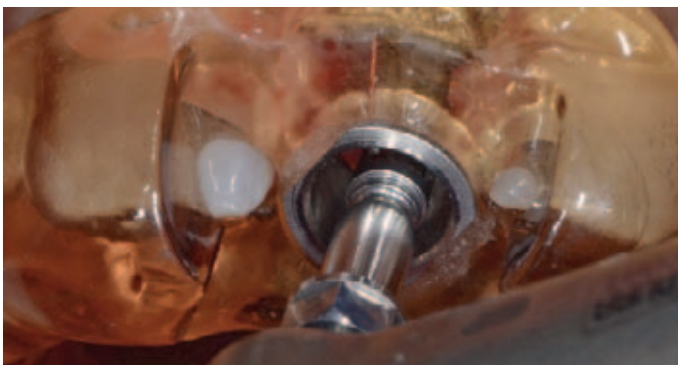

Fig. 18 The BLX implant is placed not strictly driven by the stent.

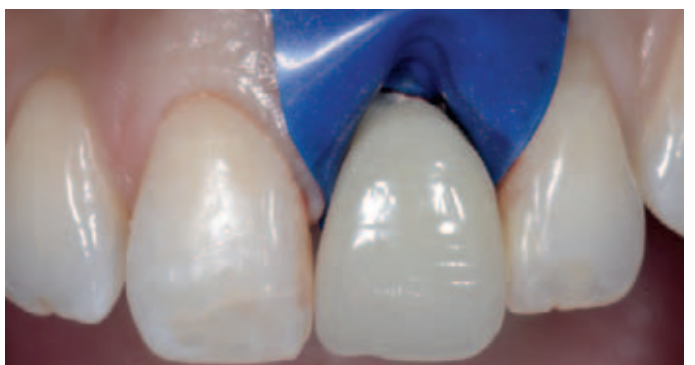
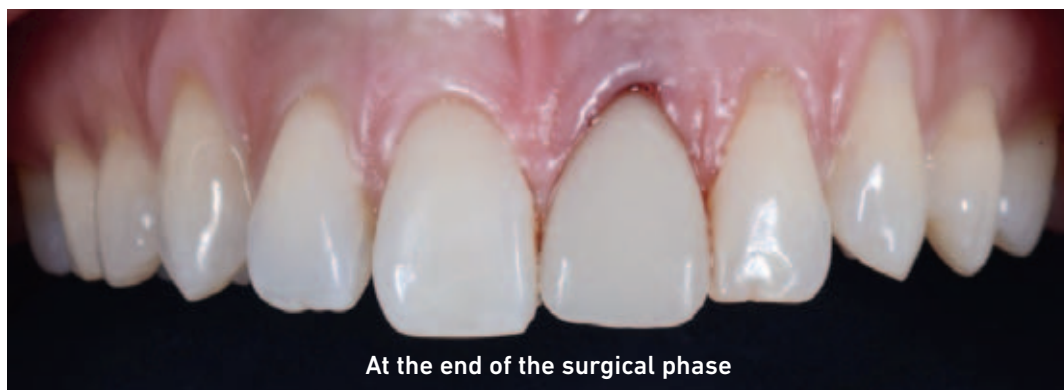
Fig. 19 Connection of the provisional crown to the abutment.



**Fig. 20** Clinical situation at the end of the procedure.

## PROSTHETIC PROTOCOL AND PROVISIONALISATION

The resulting implant stability was very high (greater than 50 nw/cm), a pre-requisite for the placement of a temporary crown.

After screwing in the temporary abutment, the temporary crown was then connected to it; a small piece of dental dam kept the field dry in order to ensure optimal adhesive conditions (Fig. 19).

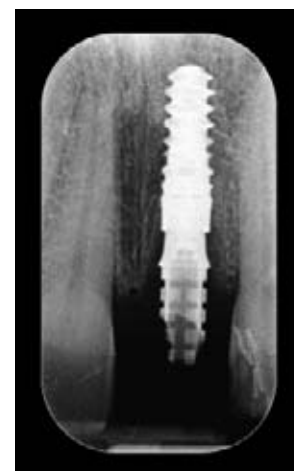The provisional crown was screwed on with a torque of 20 nw/cm; the screw hole was protected with Teflon and closed with temporary filling material. The crown was not in contact with

the opposite jaw, either in centric occlusion or during disclusion movements.

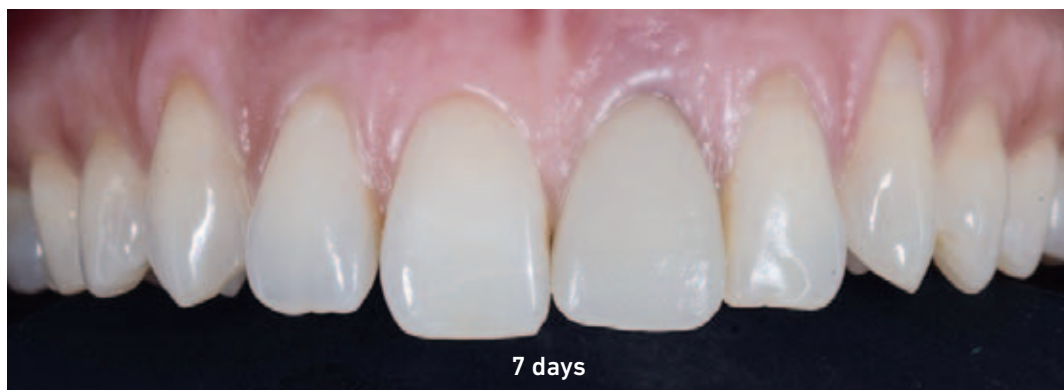## OUTCOME

The final outcome, at the end of the procedure, was absolutely aesthetically-pleasing and the patient was more than happy to have obtained such a satisfactory result with such a comfortable approach (Fig. 20). The post-operative X-ray confirmed the success of the procedure (Fig. 21).

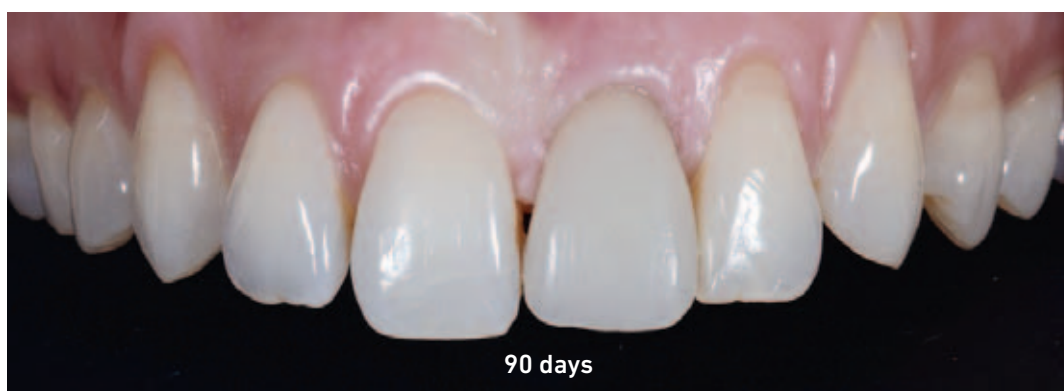What was truly impressive was the way in which the soft tissue surrounding the implant was healthy just one week after placement (Fig. 22).



**Fig. 21** X-ray image at the end of the procedure.



**Fig. 22** Clinical situation after 7 days.



**Fig. 23** Clinical situation after 90 days.

## CONCLUSION

The photo shot after 90 days (Fig. 23) demonstrates the high quality of the restoration whilst the corresponding x-ray taken at the same time (Fig. 24) shows the perfect integration of the implant, ready for the final prosthesis. The pleasant smile of the patient (Fig. 25) has been guaranteed during

all the phases of the treatment till the complete implant healing.

## Acknowledgements

I would like to thank Alessandro Giacometti DT, Genoa, Italy for his precious lab work and Guido Prando DDS, Genoa, Italy for his considerable support and help.

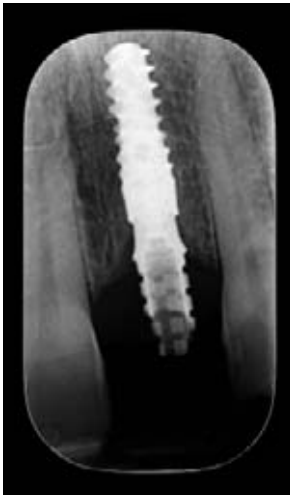

Fig. 24 X-ray image after 90 days.

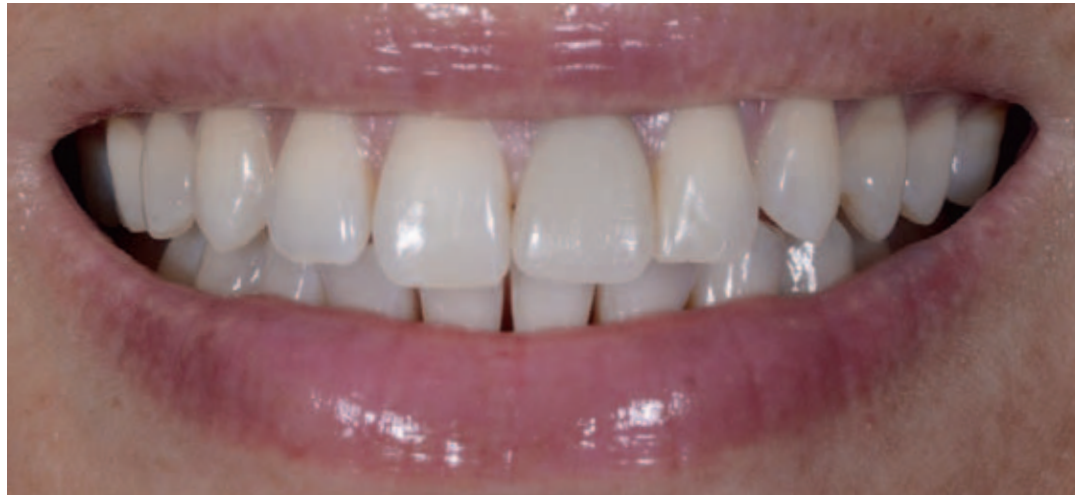

Fig. 25 The smile of the patient after the implant integration.

## REFERENCES

- Chen ST, Buser D. Esthetic outcomes following immediate and early implant placement in the anterior maxilla--a systematic review. *Int J Oral Maxillofac Implants.* 2014;29 Suppl:186-215. doi: 10.11607/jomi.2014suppl.g3.3.
- Buser D, Chappuis V, Belser UC, Chen S. Implant placement post extraction in esthetic single tooth sites: when immediate, when early, when late? *Periodontol 2000.* 2017 Feb;73(1):84-102. doi: 10.1111/prd.12170.
- Blook MS, Mercante DE, Lirette D, Mohamed W, Ryser M, Castellon P. Prospective evaluation of immediate and delayed provisional single tooth restorations. *J Oral Maxillofac Surg.* 2009 Nov;67(11 Suppl):89-107. doi: 10.1016/j.joms.2009.07.009.
- De Rouck T, Collys K, Cosyn J. Single-tooth replacement in the anterior maxilla by means of immediate implantation and provisionalization: a review. *Int J Oral Maxillofac Implants.* 2008 Sep-Oct;23(5):897-904.
- Chen ST, Buser D. Clinical and esthetic outcomes of implants placed in postextraction sites. *Int J Oral Maxillofac Implants.* 2009;24 Suppl:186-217.
- Greenstein G, Cavallaro J. Implant Insertion Torque: Its Role in Achieving Primary Stability of Restorable Dental Implants. *Compend Contin Educ Dent.* 2017 Feb;38(2):88-95; quiz 96.
- Esposito M, Barausse C, Pistilli R, Jacotti M, Grandi G, Tuco L, Felice P. Immediate loading of post-extractive versus delayed placed single implants in the anterior maxilla: outcome of a pragmatic multicenter randomised controlled trial 1-year after loading. *Eur J Oral Implantol.* 2015 Winter;8(4):347-58.
- Weigl P, Strangio A. The impact of immediately placed and restored single-tooth implants on hard and soft tissues in the anterior maxilla. *Eur J Oral Implantol.* 2016;9 Suppl 1:S89-106.
- Fürhauser R, Mailath-Pokorny G, Haas R, Busenlechner D, Watzek G, Pommer B. Esthetics of Flapless Single-Tooth Implants in the Anterior Maxilla Using Guided Surgery: Association of Three-Dimensional Accuracy and Pink Esthetic Score. *Clin Implant Dent Relat Res.* 2015 Oct;17 Suppl 2:e427-33. doi: 10.1111/cid.12264. Epub 2014 Oct 27
- Pozzi A, Polizzi G, Moy PK. Guided surgery with tooth-supported templates for single missing teeth: A critical review. *Eur J Oral Implantol.* 2016;9 Suppl 1:S135-53.

# Use of BLX implants for immediate loading protocol in a full arch rehabilitation



## ANTOINE POPELUT

DDS, Assistant Professor  
Periodontology Department,  
Bordeaux University.

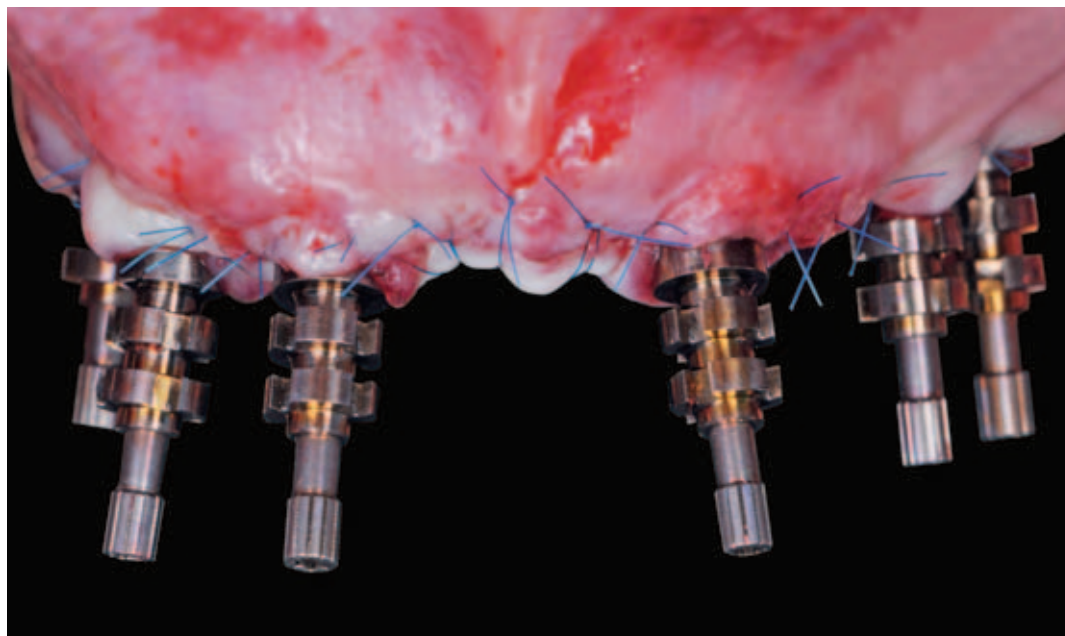
Speaker ITI (International  
Team for Implantology).

Post-graduate EFP  
Paris 7, France.

Master in research,  
Stanford, USA.

Private Practice  
Bordeaux, France

@ antoine.popelut@hotmail.fr



## JÉRÔME LECLAIR

DDS, Private Practice  
Bordeaux, France  
Membre ITI.

CES in Periodontology.  
CES in Prosthodontics.

DU of Periodontology,  
University Victor-Segalen  
Bordeaux.

DU of Oral Implantology,  
Toulouse University

@ drjeromeleclair@wanadoo.fr

Immediate loading protocols for full-arch rehabilitations are well documented. In 2009, Gallucci et al.<sup>4</sup> reported in a systematic review that immediate loaded full arch implants in the maxilla showed implant survival rates (1 to 3 years) of 95.4% to 100% and prosthetic survival rates of 87.5% to 100%. This technique makes it possible, on the day of the surgery, to manage the soft tissues at the level of the emergence profile and obtain a scalloped mucosa. However, this protocol requires sufficient primary stability of the implants of at least 30 N. The development of tapered implants has thus favored these techniques through their primary anchoring. In parallel to this, there are many

possibilities for CAD/CAM in the implant rehabilitation of fully edentulous patients: first at the surgical level, for surgical planning and implant placement in guided surgery, and secondly for prosthetic steps such as digital impressions, data processing for the design of the temporary and final prosthesis, and the manufacture of the prosthetic components (Hämmerle et al. 2009)<sup>5</sup>.

The rehabilitation of the following case will be achieved through immediate loading using a surgical guide and BLX (Straumann) implants.

A 65-year-old female patient visited the office due to mobility of the lower left bridge (Fig. 1 to 3). She also reported difficulty chewing.

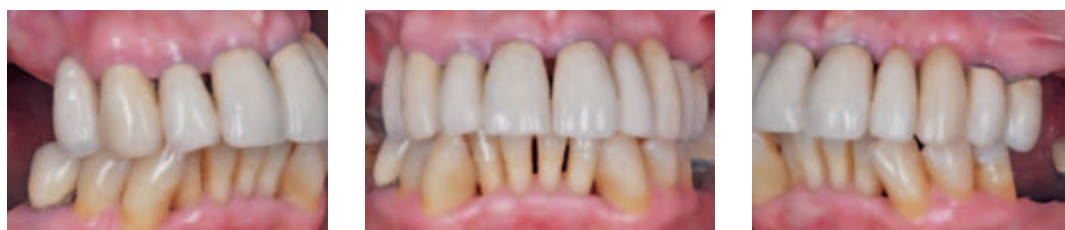

Fig. 1 to 3 Initial clinical situation.

## PASCAL MARSEILLE

Laboratory Technician  
Bordeaux, France

## GUILAUME RENY

Laboratory Technician  
Bouliac, France

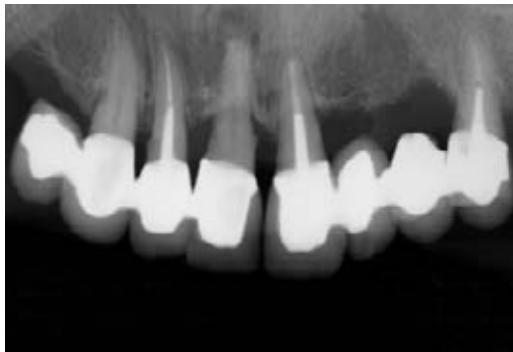
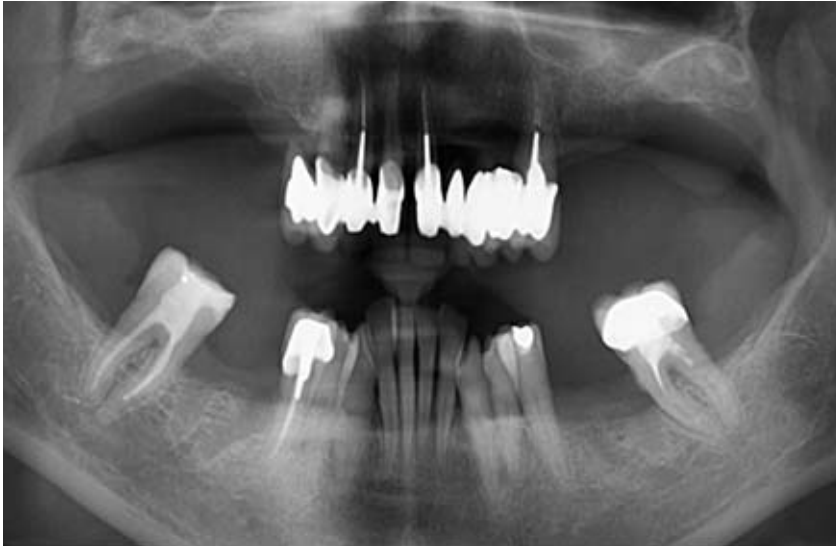

Fig. 4 and 5 Radiographic examinations.

Upon clinical examination (Fig. 4 and 5), we found:

- absence of 14, 15, 16, 17, 26, 27, 36 and 46
- presence of 2 soldered prostheses:
  - crowns on 11, 12, 13 and extension on 14; 11 and 13 kept vital;
  - bridge from 21 to 25;
- insufficient endodontic treatment of 25;
- periodontal probing greater than 5 mm with presence of bleeding;
- sector 2 bridge mobility;
- opening of an interincisive diastema.

The following diagnoses were made:

- Occlusal diagnosis: mandibular incisal extrusions, Class 1 occlusion with BiPro, dentomaxillary disharmony and alveolar compensation by linguoversion of the incisal block. The intermaxillary occlusion is stable and reproducible.
- Periodontal diagnosis: periodontitis stage 3 grade B (Papapanou et al. 2018)<sup>8</sup>.
- Aesthetic diagnosis: low smile line, correct positioning of the incisal edge of the central incisor, correct lip support and harmonious profile.

In view of the reserved prognosis of the remaining teeth, we considered for this patient a full arch rehabilitation on 6 implants with immediate loading with a transitional bridge.

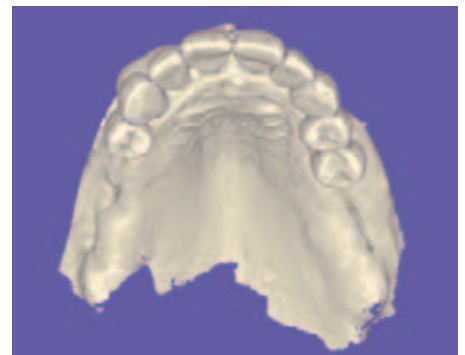
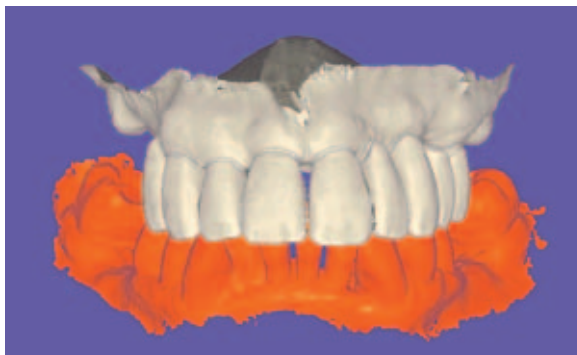
Fig. 6 and 7 Digital recording of the initial situation.

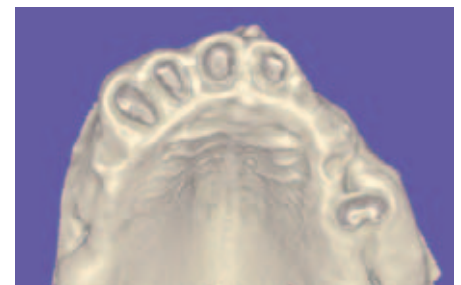
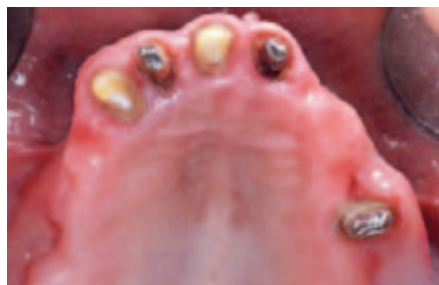
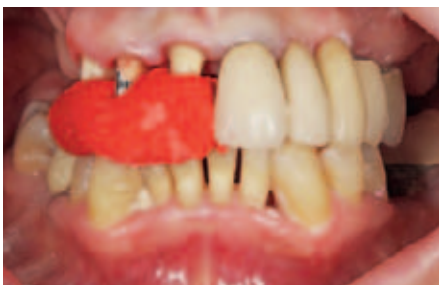Fig. 8 and 9 Successive removal of restorations with positioning of resin block.

Fig. 10 Digital impression of the residual abutments.



## CLINICAL PROTOCOL

Periodontal therapy was carried out with non-surgical techniques. During reevaluation, we found no periodontal probing deeper than 4 mm. The decision was therefore made to proceed with an implant.

During the first session, an initial impression was taken (True definition 3M scanner - Fig. 6 and 7) and an alginate impression was taken to for the purpose of making the transitional bridge.

In the same session, the old prostheses were removed, the endodontic treatments of 11 and 13 were performed and the limits of the crowns were refreshed in order to:

- allow the subsequent fitting of the prosthetic project;
- support the impression-molded transitional bridges until the surgical phase (thus avoiding any use of a removable prosthesis);
- support a surgical guide with a combination of teeth and mucosal support.

The removals were carried out successively on the lateral sectors in order to keep the vertical dimension using resin blocks (Fig. 7)

A new recording of the margins was taken (Fig. 8 and 9) and a mounting on an articulator with a face

bow was undertaken using the FAG system.

The aesthetic parameters of the face were sent to the laboratory using the Ditramax system. The objective of this first phase was to produce a transitional impression-molded prosthesis (Fig. 11), as the patient wished to keep the morphological criteria of the old prostheses (crown height and lip support).

The creation of an immediate temporary prosthesis supported by implants was intended to facilitate the completion of all the prosthetic steps and make it possible to guide gingival healing (Galluci et al.)<sup>3</sup>.

In the laboratory, an aesthetic assembly without artificial gingiva was carried out on the dental preparations after printing the model (Formlabs 2 3D printer). From an occlusal point of view, the decision was made to:

- make an ameloplasty of the mandibular incisors (Fig. 17) to compensate for their extrusion, reduce the overbite and ensure proper anterior guidance;

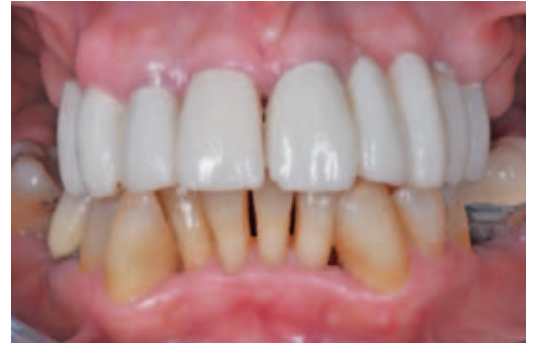

Fig. 11 Making an immediate fixed prosthesis by impression molding.

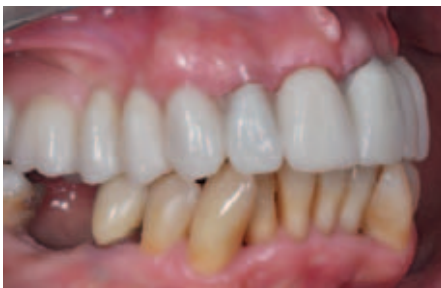

Fig. 12

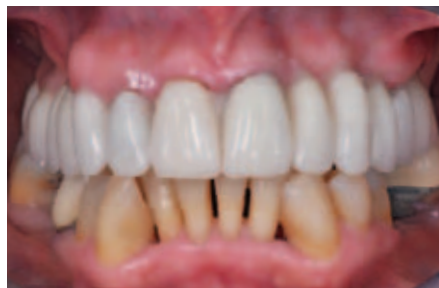

Fig. 13

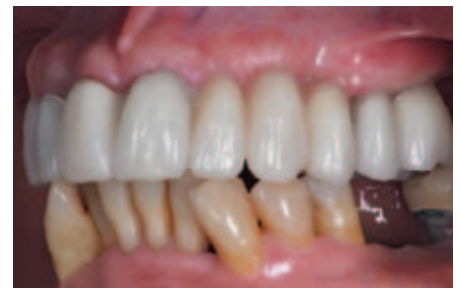

Fig. 14

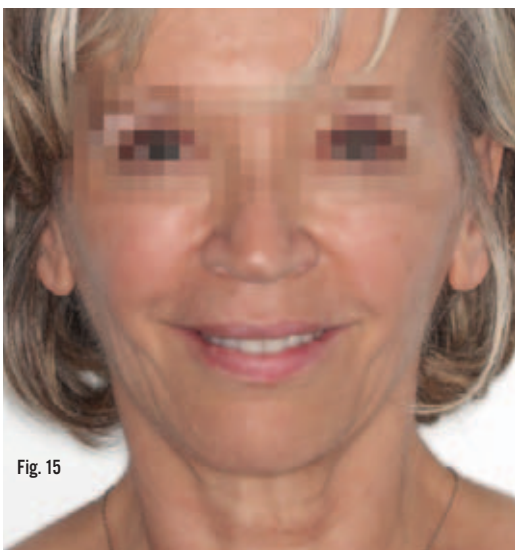


Fig. 15

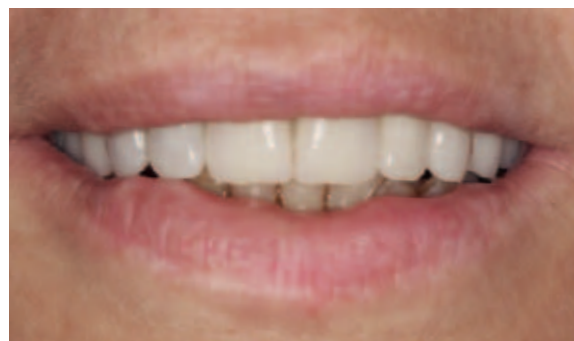

Fig. 16

Fig. 12 to 16 Aesthetic and phonetic fitting of the prosthetic project.

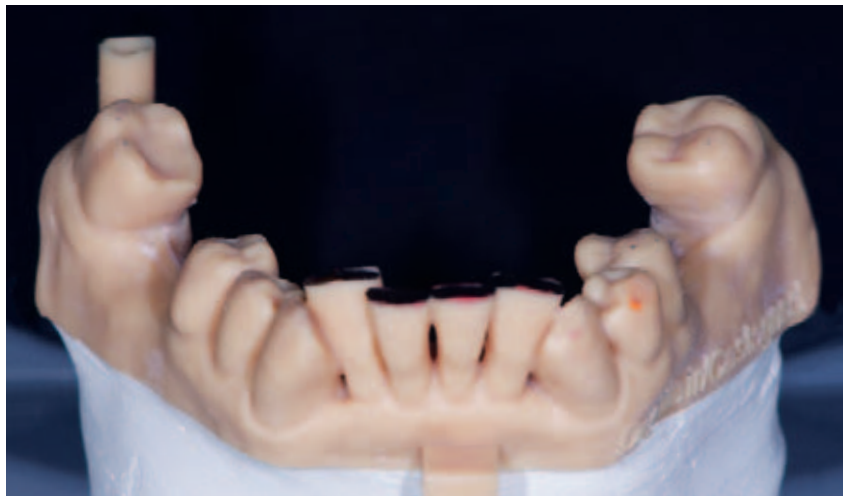

Fig. 17 Quantification of mandibular incisor ameloplasty.

- re-establish antagonistic contact with 37 and 47 in order to re-establish posterior wedging and improve the distribution of occlusal forces as part of the immediate loading protocol.

The project was then tested in the mouth (Fig. 12 to 16) and validated according to aesthetic and phonetic criteria. Once validated, the project was scanned in the laboratory and stored in STL form. It was

then merged with the tomographic acquisition (DICOM) to allow for the positioning of the implants according to the prosthetic parameters (Fig. 18). A surgical guide was then created (Fig. 19). The planning made it possible to identify low bone volume for sites 12 and 22, requiring guided bone regeneration. On site 22, the choice was to place the implant in the fresh extraction socket. The clinical situation perfectly met the criteria for immediate implantation defined by Morton et al<sup>7</sup>. The implant diameter was defined according to the study of surgical parameters, while the diameter of the abutments was chosen according to the future emergence profile. Each SRA (screw retained abutment) was chosen during planning, as merging of the STL and DICOM data allowed for visualization at the bone level (implant neck) and the gingival level (SRA shoulder).

From the validated prosthetic project, the following were obtained (Fig. 20 to 23):

- a surgical guide, limited to the pilot drill;
- an implant positioning guide;
- a transparent resin duplicate of the project, hollowed out at the edentulous ridge to allow for transmission of predetermine occlusion;
- an individual perforated impression tray to take the impression using a pick up technique.

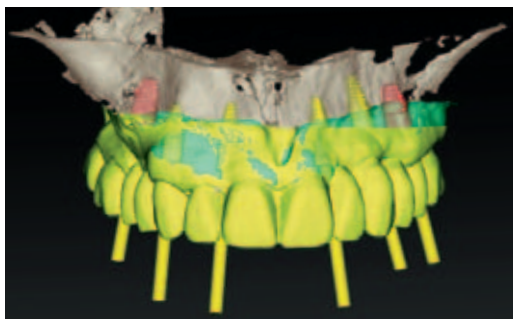


Fig. 18 Implant positioning according to the prosthetic parameters.

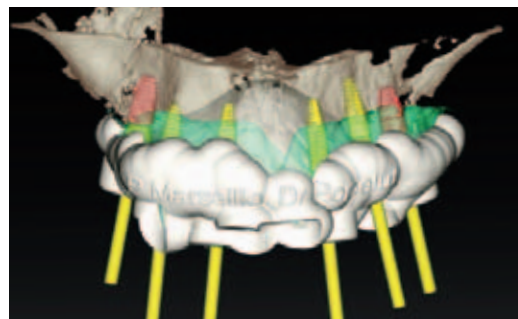


Fig. 19 Design of the surgical guide.



Fig. 20 Surgical guide printed.

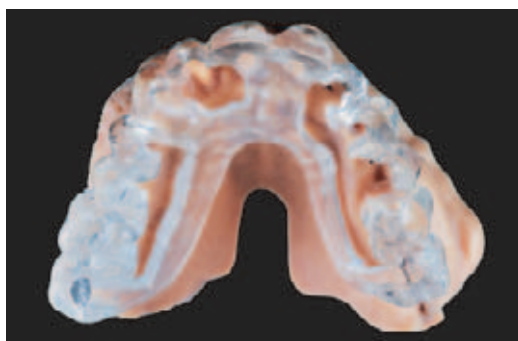


Fig. 21 Implant positioning guide.

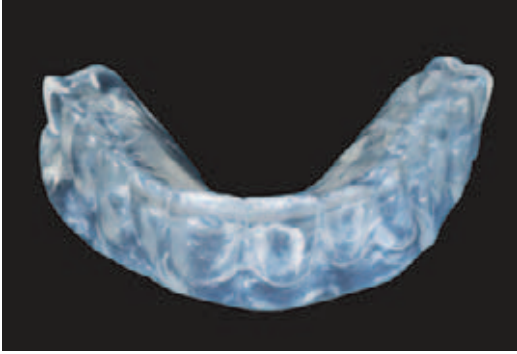

Fig. 22 Project duplicate.

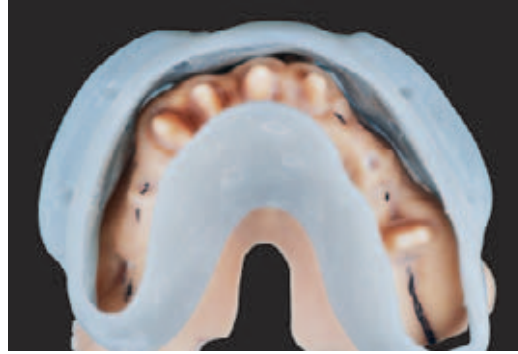


Fig. 23 Individual impression holder.

## SURGICAL STEP & POSTOPERATIVE IMPRESSION

Before surgery, the vertical dimension was measured by placing two marks directly on the skin.

A full-thickness flap was made. The surgical guide was placed (Fig. 24), then the pilot drill was placed in sites 16, 14, 12, 22, 24 and 26 through the surgical guide. The transparent resin template obtained from the prosthetic project allowed the implants to be placed with proper emergence allowing for future screw-retained restoration (Fig. 25). The low bone density in site 24 made it necessary to place the implant in site 25. Four

3.75 mm diameter BLX implants were placed in sites 14, 12, 22 and 25, and two 4.5 mm diameter BLX implants were placed in sites 16 and 26. An immediate implant was placed in the fresh extraction socket in site 22 (Fig. 26). The residual teeth were then extracted, and alveolar preservation techniques were applied. The primary stability of all the implants was 35 Ncm, meeting the criteria for immediate loading.

The SRAs were placed and torqued to 35 Ncm during the surgical phase in order to avoid rupturing of the attachments related to the successive unscrewing of the transgingival supra-implant components (Fig. 27).

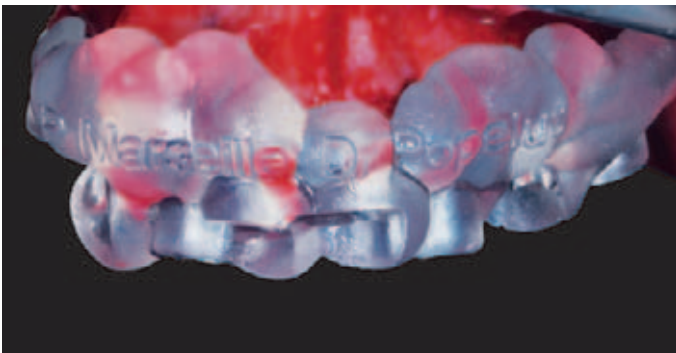

Fig. 24 Surgical guide in place.

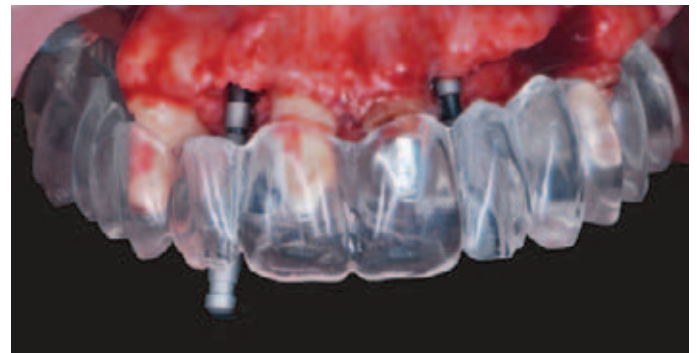


Fig. 25 Check of correct implant positioning.

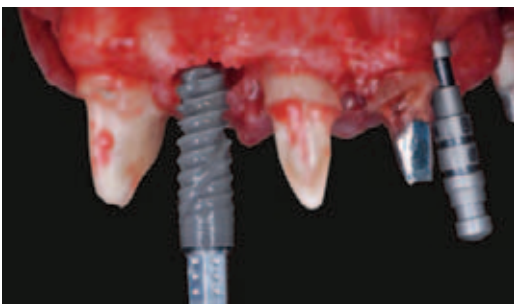

Fig. 26 Placement of the BLX implant (diameter 3.75 mm) in site 22.

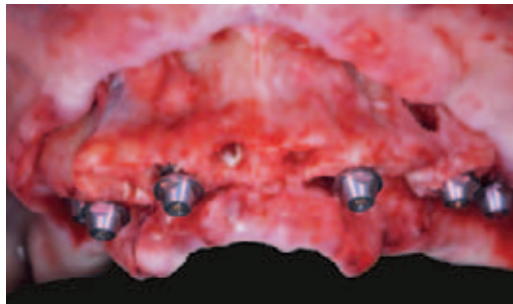

Fig. 27 Positioning of SRAs (diameter 4.6 mm).

**NB:** The abutments placed on implants 12 and 22 with a diameter of 4.6 mm (the only diameter available at this stage).

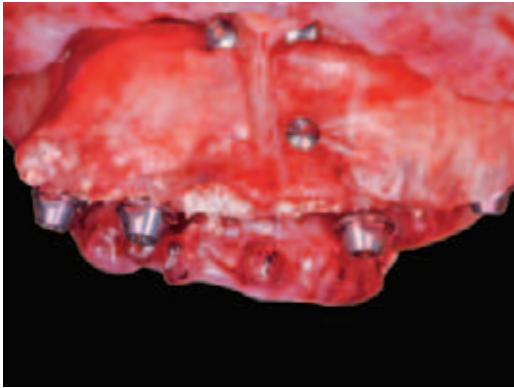


Fig. 28 Guided bone regeneration of the anterior sectors.

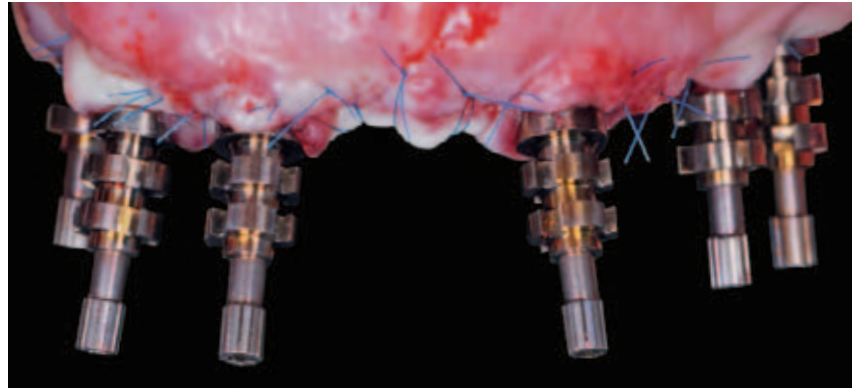


Fig. 29 End of procedure with positioning of impression abutments on SRAs.

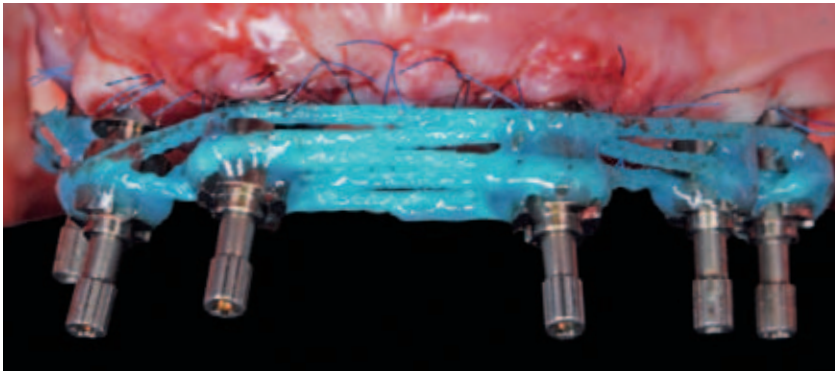


Fig. 30 Solidification of transfers.

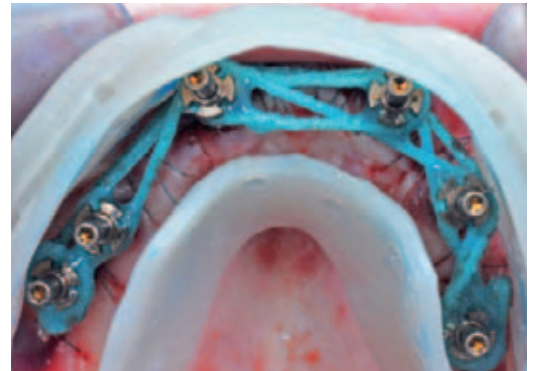

Fig. 31 Check of IEP adaptation to the mesh transfer set.

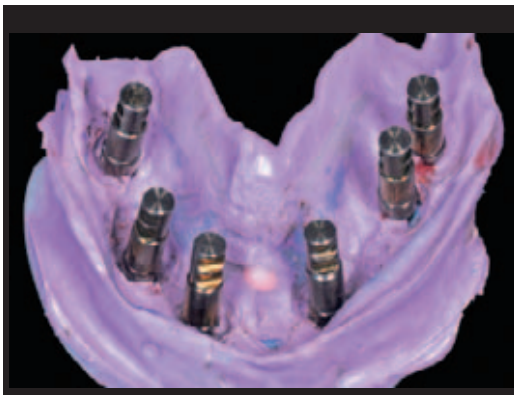

Fig. 32 Impression with repositioned analogs.

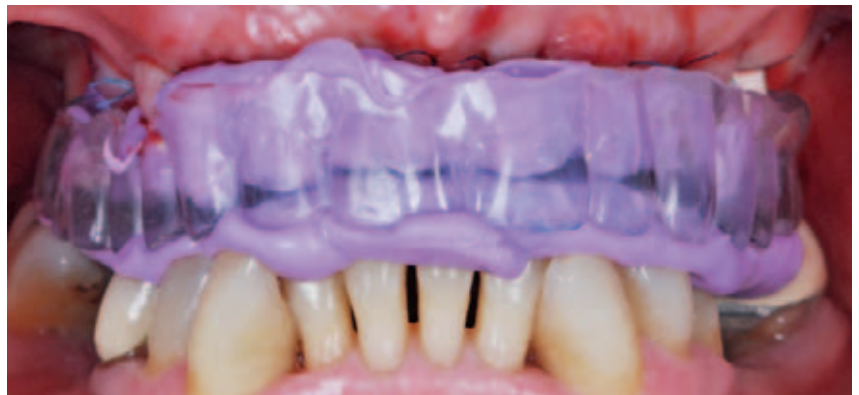

Fig. 33 Relining and occlusion taking using the duplicate.

Since BLX implants have an internal connection, the use of SRAs makes it easier to achieve prosthetic passivity as they can compensate for potential divergence of up to 40°.

In sites with low bone thickness a simultaneous guided bone regeneration was made (bone substitutes: Botiss Cerabone, Membrane: Jason Botiss) (Fig. 28).

Before the sutures were performed, the impression copings were connected to the SRAs (visual inspection confirmed they were positioned

correctly) (Fig. 29). After the sutures were made, the impression copings were splinted using a photo-activated fiber mesh (CST Link - Bio Medical Components) (Fig. 30). This was to prevent any mobility of the transfers in the impression in case of insufficient material and to secure the screwing phases of the replica to the impression copings.

The individualized impression tray was adjusted until friction-free insertion was possible (Fig. 31); in this case, a wax stop was placed at the bottom

surface of the tray to ensure a sufficient quantity of the material around the impression copings.

An impression was made using a polyether (Impregum – 3M), injecting the material under the fiber mesh and with conventional lining, increasing the accuracy of recording the gingival environment and the inclusion of the copings in the material (Fig. 32).

When the impression was removed, the PEEK cylinders were immediately screwed onto the SRA abutments.

In the absence of a reference once the residual teeth were extracted, occlusion was recorded by placing a duplicate of the prosthetic project (vertical dimension validated and checked using the two the marks placed at the beginning of surgery), which was hollowed out at the ridge and relined using occlusion silicone (Fig. 33).

In order to allow it to be repositioned in the prosthesis laboratory and placed in the articulator, an identical number of transitional PEEK caps were sent to the laboratory in order to be repositioned on the SRA analogues.

## LABORATORY STEPS

The impression was poured in plaster (Fuji rock GC class 4). This method allowed edentulous areas to be sculpted in the plaster to create gingival compression and promote scalloping of the edentulous ridge (Fig. 34 and 35).

After screwing the PEEK caps onto the replica, the impression was repositioned on the articulator against the initial mandibular model, using the duplicate that was relined at the end of the procedure.

Our preference of material for the temporary bridge was a PMMA because of its mechanical<sup>1</sup>

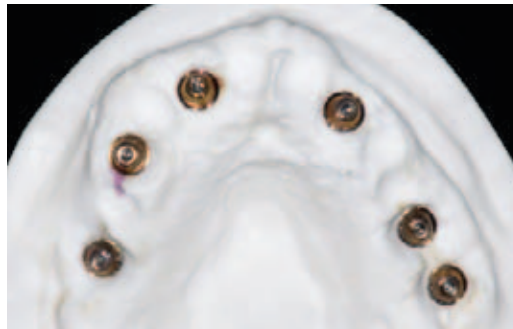
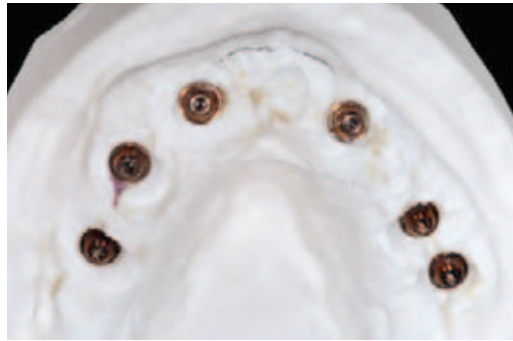
Fig. 34 and 35 Development of the gingival compression zone at the expense of the plaster.

and biocompatibility<sup>2</sup> properties, which are adapted to these immediate loading situations. Nonetheless, in the maxilla<sup>9</sup>, our preference involved increasing the mechanical resistance of the transitional bridge by including a metal framework to prevent any mechanical complications during the osteointegration phase.

The scanning (Kapos<sup>6</sup>) of the validated prosthetic project allowed us to reproduce it accurately (PMMA 5 layers from Anaxdent, machined in a Zenotech Wieland 5 axis machine), and the CoCr framework, designed by reducing the prosthetic project, included the temporary abutments through relining (Fig. 36). The bridge was then stained and polished (Fig. 37).

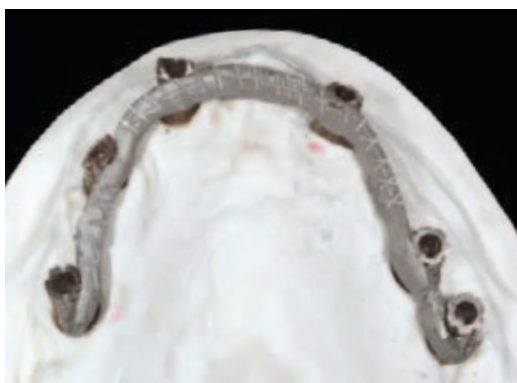


Fig. 36 Casting of a metal framework.

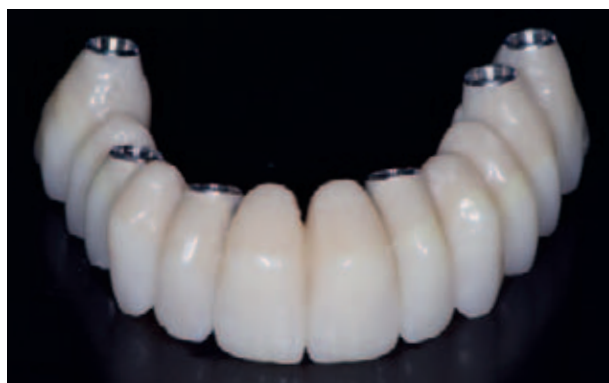

Fig. 37 Temporary bridge before installation.

## PLACEMENT OF THE TRANSITIONAL PROSTHESIS AT 24 HOURS

The transitional bridge received from the laboratory was decontaminated before any placement using a saline and betadine mixture.

The unscrewing of the PEEK caps (Fig. 38) was accompanied by the placement of cotton pellets soaked in betadine (Fig. 39) to limit soft tissue collapse and promote bridge placement without gingival tissue interposition. The transitional bridge was torqued to 15 Ncm (Fig. 40 to 43)

after radiographic inspection (Fig. 44). The screw accesses were sealed with PTFE and a temporary filling material (TELIO CS Ivoclar). Finally, occlusal verification was performed to ensure the homogeneous distribution of the static and dynamic contacts.

Healing after 2 weeks and after 3 months was satisfactory (Fig. 45) as was the aesthetic integration into the patient's smile. A frenectomy was performed to limit excessive gingival forces. The validation of osteointegration will make it possible to transition to the use phase after 6 months.

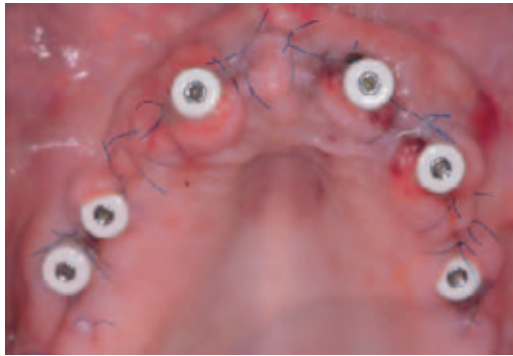


Fig. 38 Situation at 24 hours postoperatively.

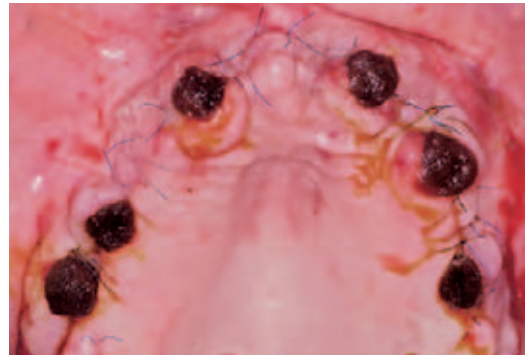


Fig. 39 Unscrewing the PEEK caps.

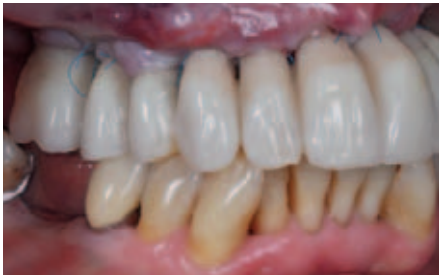

Fig. 40

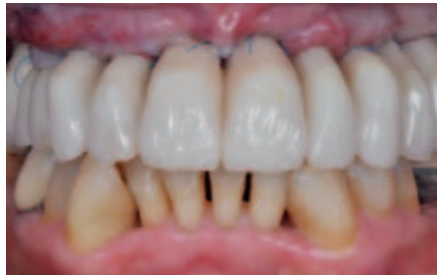

Fig. 41

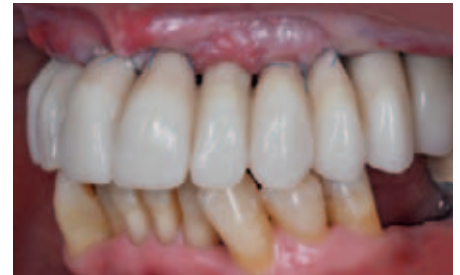

Fig. 42

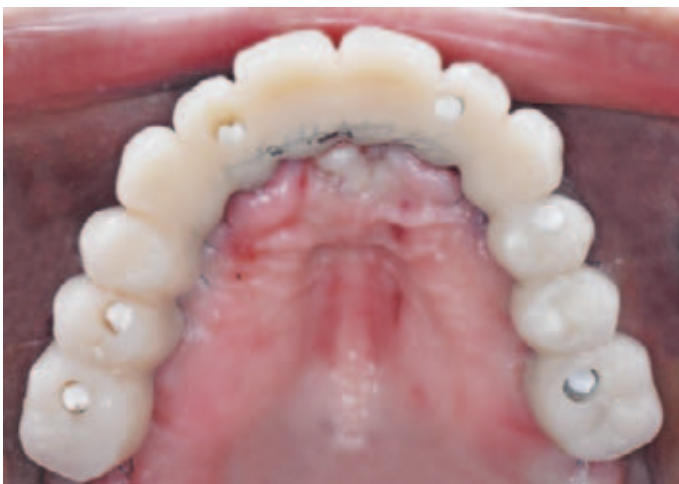

Fig. 40 to 43 Close-up of the temporary bridge immediately after placement.

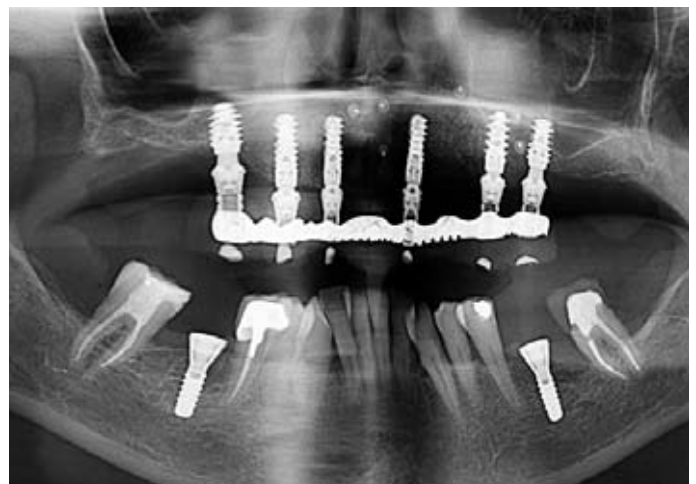

Fig. 44 Radiographic check-up confirming the proper adaptation of the temporary bridge on all SRAs.

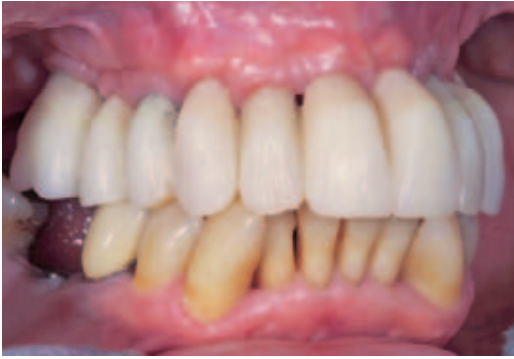

Fig. 45 Healing at 3 months.

## FINAL BRIDGE

4 months after the surgical phase and the production of the immediate temporary prosthesis, the temporary bridge was removed.

The objectives of the first removal were:

1. To ensure the osseointegration of each implant
2. Prosthetic re-evaluation:

- functional reassessment: occlusion was checked, as was the patient's phonetic adaptation to her new prosthesis;
- aesthetic reassessment of the bridge: the patient was fully satisfied with the temporary bridge and refused to add artificial gingiva, although this was indicated here;
- reassessment of the compression of bridge pontics: areas clearly undergoing excessive compression were relieved in order to promote reepithelialization of the gums;
- re-evaluation of hygiene allowed by the embrasures for the passage of brushes.

3. Once these parameters were validated, impression for the final bridge was taken.

Here we chose a plaster impression technique (Snow White by Kerr), which was our preference for 3 reasons:

- dimensional stability of the material during its setting phase;
- absolute rigidity between impression transfers, no need for splinting the copings to each other and plaster key validation phases (Pera et al. 2016)<sup>10</sup>;
- a low compression that facilitates the recording of the pontics and pseudo-papilla areas, sculpted by the temporary bridge.

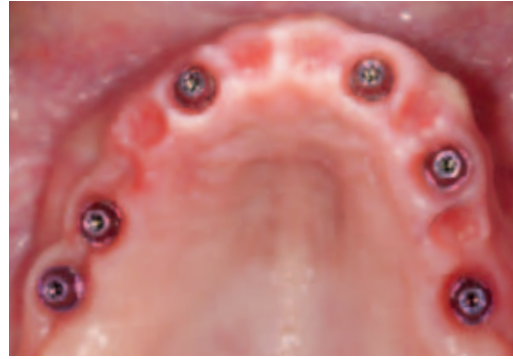

Fig. 46 Occlusal view 4 months after surgery after the temporary bridge was removed.

The impression was made using a pastry bag, which facilitated both the filling of the impression tray and the peripheral coating of the transfers. After setting, the transfers were released using an ultrasonic insert. The low compression of the material allowed the registration of the pontics area and pseudo-papillae in an efficient manner (Fig. 46 to 49).

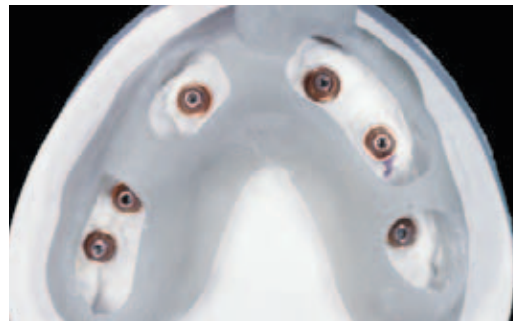

Fig. 47 A customized impression tray is prepared.

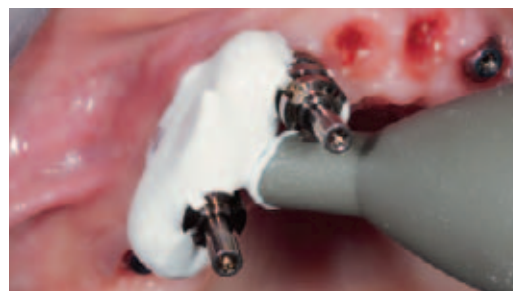

Fig. 48 Plaster impression technique.

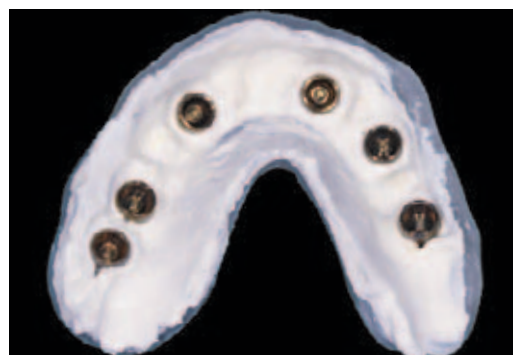


Fig. 49 View of the tray after plaster impression.

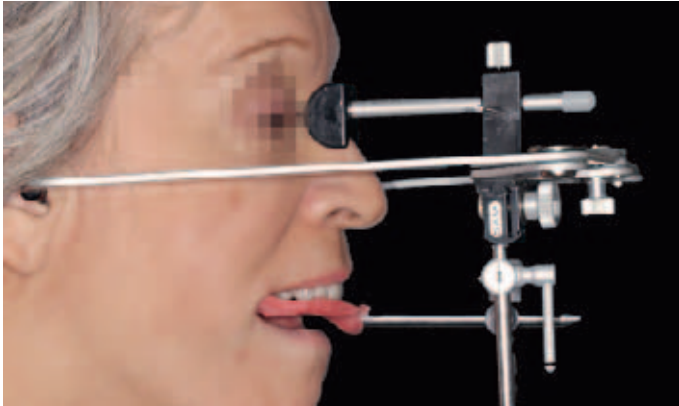


Fig. 50 Facebow registration (SAM System).

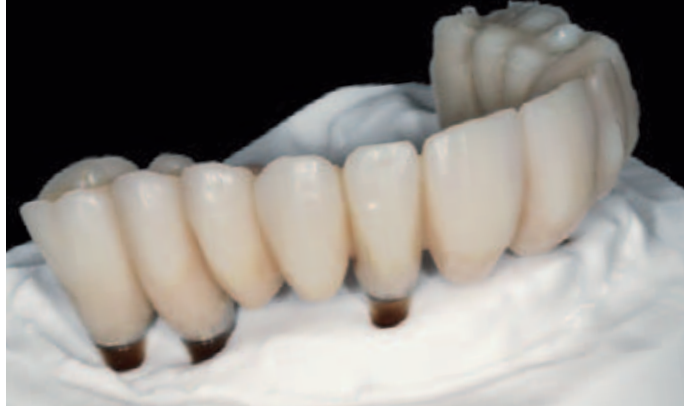

Fig. 51 The temporary bridge is repositioned on the master model.

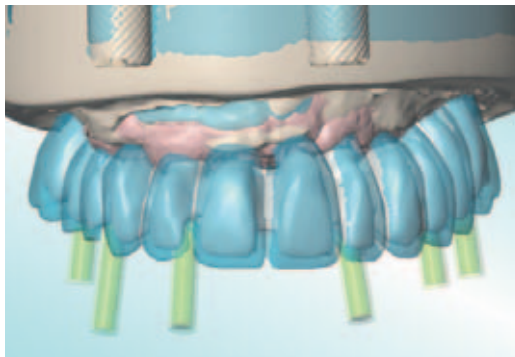


Fig. 52 The temporary bridge is scanned on the master model.

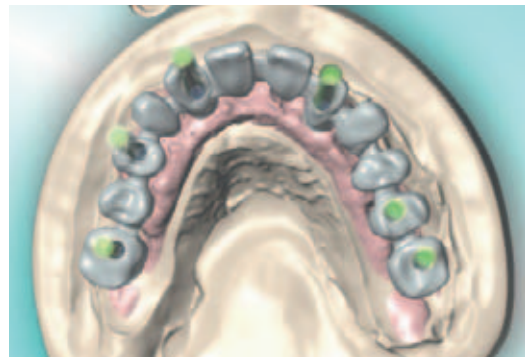

Fig. 53 The framework is designed by homothetic reduction of the temporary bridge.

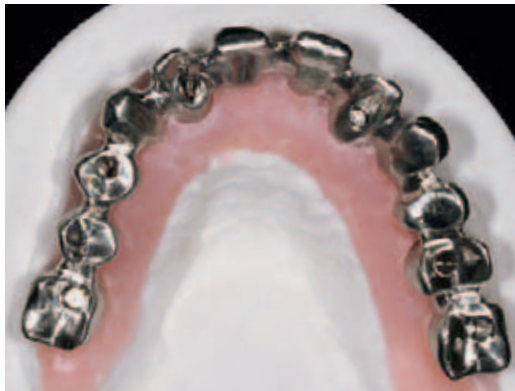
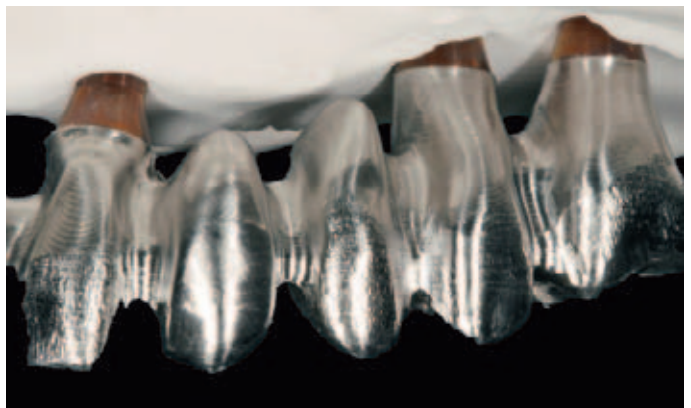
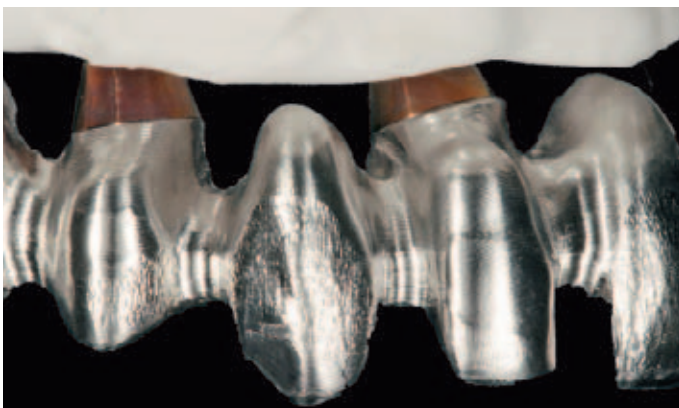Fig. 54 to 56 The framework is received. The passive fit is verified on the master model.

In the next clinical visit, a face bow registration (SAM system) was made, allowing the master model to be placed in the articulator (Fig. 50 and 51).

At the same time, the temporary bridge was scanned in the mouth and a printed model was placed in an articulator. This model made it possible to create an index for the final prosthesis.





In this case, as the temporary bridge fulfilled all the aesthetic and functional objectives, it was scanned (Dental Wings® 7series scanner) directly on the model obtained from the impression.

The framework was then designed by homothetic reduction of the bridge: we chose to produce a screw-retained ceramo-metallic bridge with a machined CoCr Cares® framework, a material that, when machined, offers excellent passivity (De França, 2017)<sup>11</sup> (Fig. 52 to 56).

When the framework was received, its passivity was checked on the model and in the mouth. Duralay shims were made on the framework to ensure that the vertical occlusion dimension defined by the temporary bridge was respected.

Once the framework had been validated, the ceramic was layered on the framework and the

occlusion was adjusted according to the indications from the index taken from the digital models (Fig. 57 and 58).

The ceramic fitting phase was carried out with several check points:

- check of prosthetic profiles: compression, passage of interproximal brush, absence of concavity;
- check of static and dynamic occlusion by restoring efficient anterior guidance;
- phonetic and aesthetic integration check.

After finishing, the prosthesis was inserted with a screwing torque of 15 Ncm and the screw channels were closed through compaction of PTFE tape and an occlusal composite (Fig. 59 to 61).

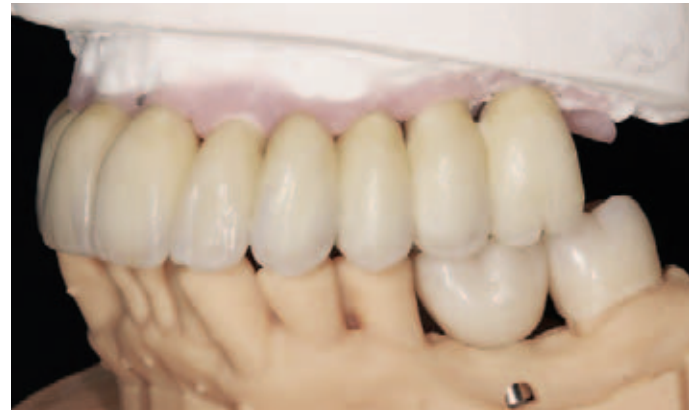
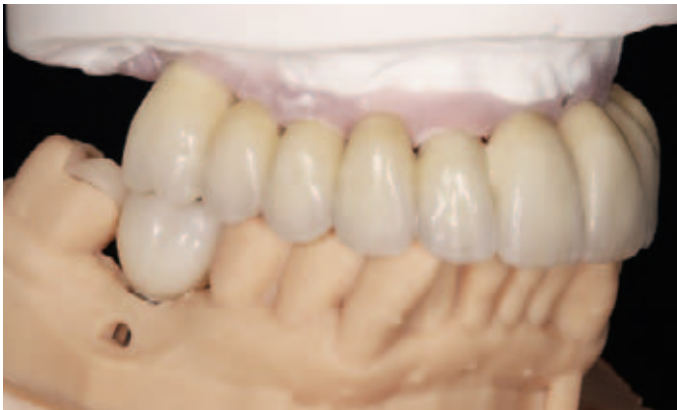
Fig. 57 and 58 The ceramic is layered on the framework and the occlusion is adjusted.

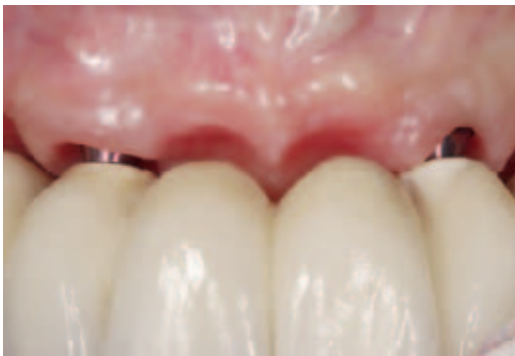

Fig. 59 Final bridge insertion.

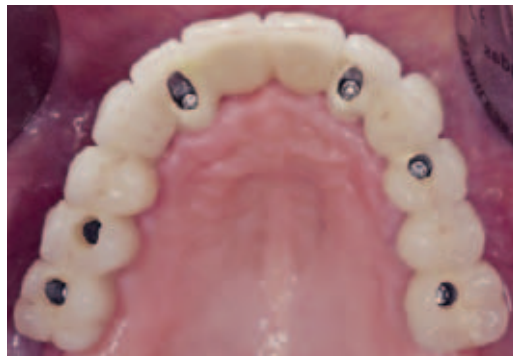

Fig. 60 Occlusal view of the final bridge.

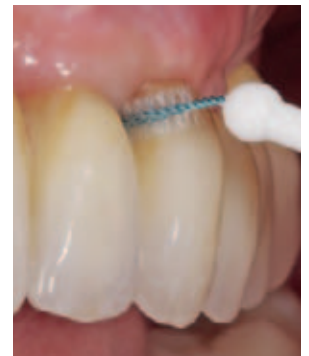

Fig. 61 Passage of interproximal brush.

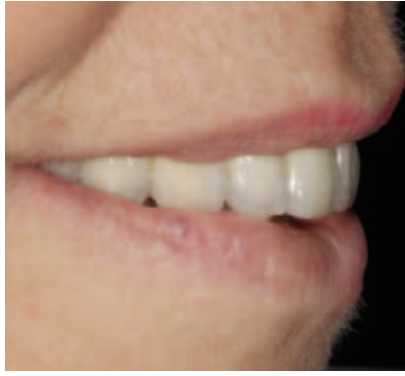

Fig. 62 and 63 Extra-oral view of the smile with the final bridge.

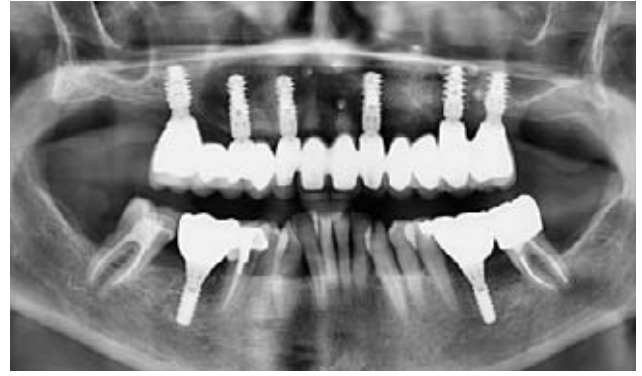


Fig. 64 X-ray after placement of the final restoration.

The immediate loading of a temporary full screw-retained bridge is a real benefit for our patients, restoring aesthetics and function during the day. This protocol thus saves time and provides precision, soft tissue healing quality and better access to hygiene for the patient, and optimizes our aesthetic results (Fig. 62 to 64).

The advantages of this protocol are:

- treatment in 4 sessions;
- no use of a removable prosthesis;

- reliability of the aesthetic project with the use of preparations;
- stability of the guide thanks to the dental supports.

*With thanks to Doctor Mathilde Jacquemont for her clinical and photographic assistance.*

*The authors would like to thank Mr. Guillaume Reny from the Corus LSO laboratory for the prosthetic realization.*

## REFERENCES

1. Edelhoff D, Beuer F, Schweizer J, Brix O, Stimmelmayer M, Guth JF - CAD/CAM-generated high density polymer restorations for the pretreatment of complex cases: a case report. *Quintessence Int* 2012 Jun; 43(6):457-467. Cat 4.
2. Frazer RQ, Byron RT, Osborne PB, West KP. PMMA: an essential material in medicine and dentistry. *J Long Term Eff Med Implants*. 2005;15(6):629-39. Review.
3. Gallucci GO, Marvopoulos A et al.- Influence of immediate implant loading on peri-implant soft tissue morphology in the edentulous maxilla. *Int J Oral Maxillofac Implants* 2007;22(4):595-602.
4. Gallucci GO, Morton, D et al. Loading protocols for dental implants in edentulous patients. *Int J Oral Maxillofac Implants* 2009, 24 Suppl: 132-146.
5. Hämmerle CH, Stone P, Jung RE, Kapos T, Brodala N Consensus statements and recommended clinical procedures regarding computer-assisted implant dentistry. *Int J Oral Maxillofac Implants* 2009, 24 Suppl: 126-31.
6. Kapos T, Ashly LM, Gallucci GO, Weber HP, Wismeijer D - Computer-aided design and computer-assisted manufacturing in prosthetic implant dentistry. *Int J Oral Maxillofac Implants*. 2009; 24 suppl: 110-7 cat1.
7. Morton et al. Immediate restoration and loading of dental implants: clinical considerations and protocols *Int J Oral Maxillofac Implants* 2014.
8. Papapanou et al *J Periodontol* 2018 Jun, 89 Suppl 1:173-182.
9. Salvi GE, Brägger U - Mechanical and technical risks in implant therapy *Int J Oral Maxillofac Implants* 2009;24 suppl: 69-85.
10. Pera F, Pesce P, Bevilacqua M, Setti P, Menini M - Analysis of different impression techniques and materials on multiple Implants through 3-dimensional laser scanner. *Tooth Implant* 2016 Apr; 25(2): 232-237.
11. De França DG, Morais MH, Das Neves FD, Barbosa GA - Preciso fit of screw-retained Implant-supported Fixed Dental Protheses fabricated by CAD/CAM, copy-milling and conventional Methods. *Int J Oral Maxillofac Implants*. 2017 May/June; 32(3):507-513.

# Immediate implant placement

with immediate loading following extraction of natural teeth and cystectomy of adjacent tooth



## ALESSANDRO PERUCCHI

DDS, Dental clinic in Mendrisio, Switzerland.

Specialist in Oralsurgery. Pedagogical speaker at universities and in training courses.

Author of several scientific publications.

Member of SSO, EAO, ITI and founder of MINEC.

www.perucchi.dentist

@alessandroperucchi@sunrise.ch



## CHRISTIAN MONTI

DDS, Member of SSO in Switzerland.

AISOD member and expert in intravenous sedation in dentistry.

Surgical Assistant and Faculty member of Lake Como Institute.

Chairman and founder of MINEC Switzerland.

Freelance professional in Como and Ticino, Switzerland.

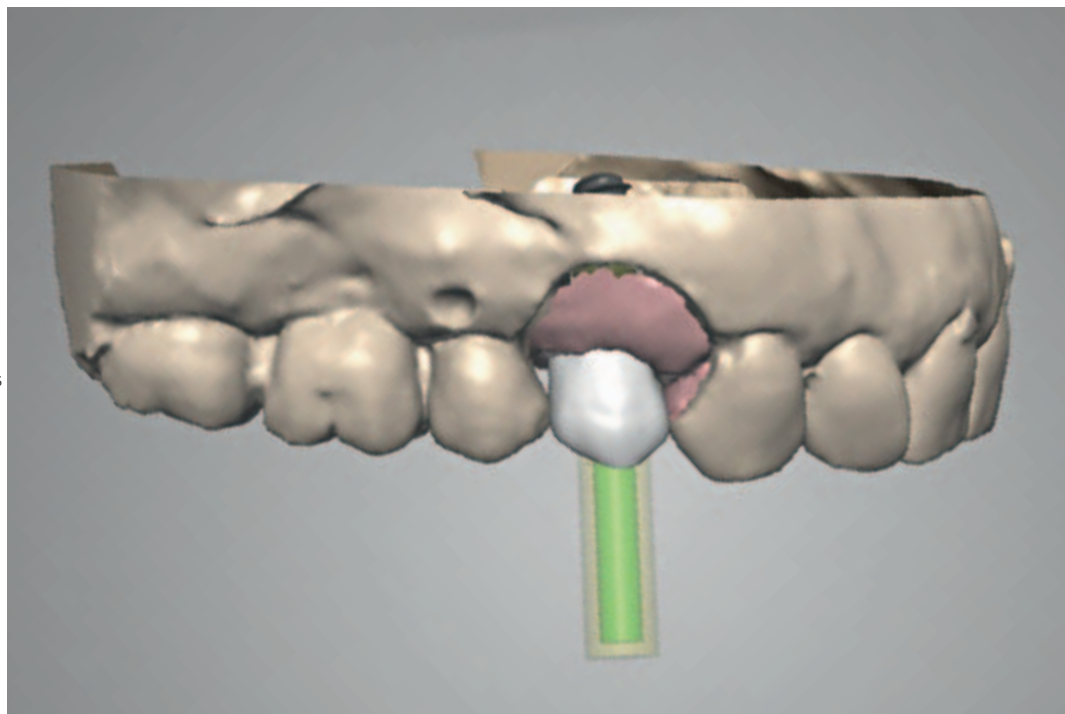
@monti.christian@libero.it

## SERENA PEDRAZZINI

DMD, PhD Student at Zürich University.

## JESSICA DANA

Medical dentistry student, University of study of Insubria in Varese (Italy).



## INTRODUCTION

The appropriate treatment, care and management of a patient always begins with a properly-established diagnosis. A diagnosis cannot always be established through efficient intra-oral and complete radiographic examination alone, as unforeseen and unusual situations are often right around the corner.

## INITIAL SITUATION

A patient came to our attention after a trauma due to a fall, in which she slipped and hit her right cheek. She reported soreness and the feeling of having broken a tooth. Upon intraoral inspection, a crack on element 14 was clear and sharp, but to assess its depth we performed an intraoral radiograph.

This indeed showed a longitudinal fracture extending below the bone crest on the palatal side, too deep to attempt conservative reconstruction. The

woman immediately agreed to the suggestion of replacing the damaged tooth with an implant, as she did not wish to be without that tooth for even one day (Fig. 1 and 2).

## PROCEDURES

### Treatment plan

First of all, we performed a three-dimensional radiograph to plan an implant-prosthesis placement with immediate loading on the unfortunately lost element due to the excessive depth of the fracture. During this radiograph, we encountered a significant surprise: unclear radiographic transparency on the asymptomatic tooth 15 (Fig. 3 and 4) was in fact a lateral periodontal cyst on the mesial side of the root, obstructing our planned implant on tooth 14. This lesion had never been noticed through regular radiographic Bite-Wing checks as it was entirely asymptomatic, and may have

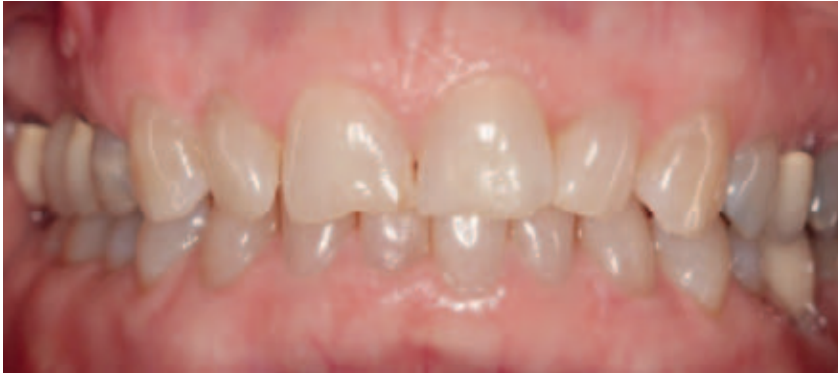

Fig. 1

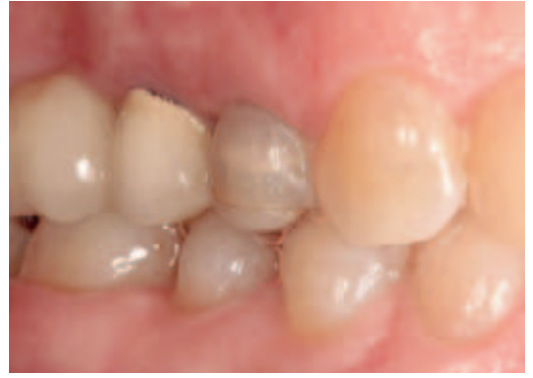

Fig. 2

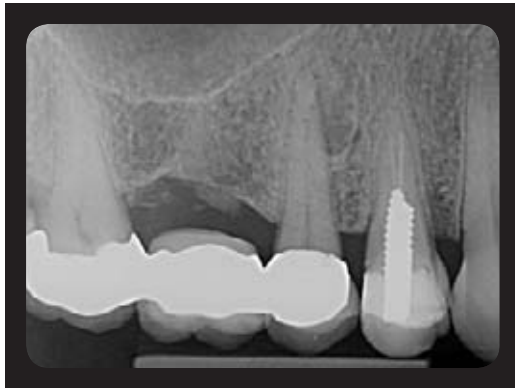


Fig. 3

been present for a long time. We therefore decided to redefine our treatment plan to include devitalization and cystectomy on 15, and then focus on 14. We chose to insert a BLX implant (Fig. 5): thanks to their macro-geometry, these fixtures are particularly suitable for the stability required for immediate loading, and as the patient wanted us to immediately replace the tooth, we opted for a Roxolid SLActive BLX implant to increase the

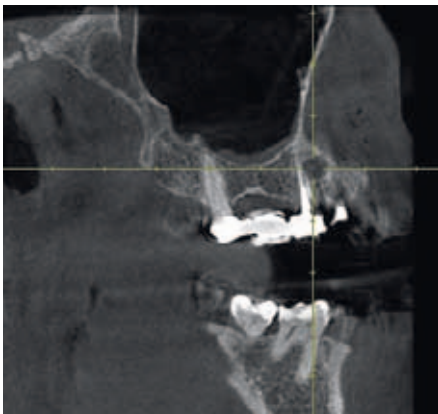


Fig. 4

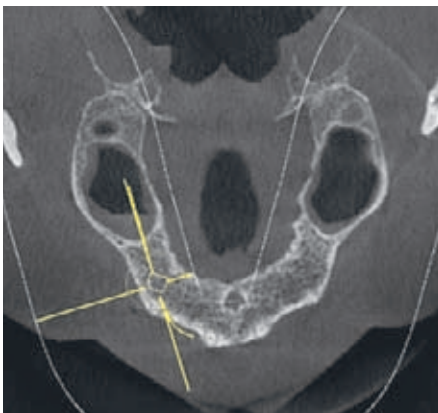
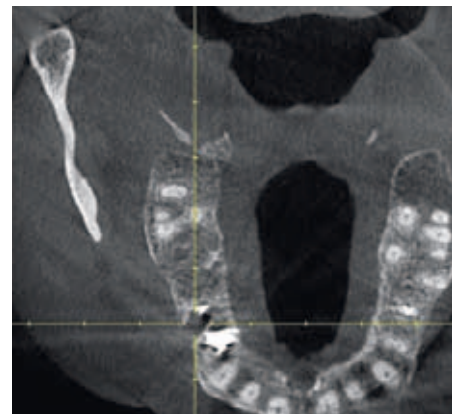
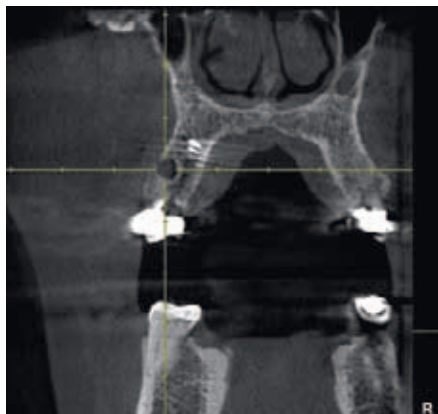
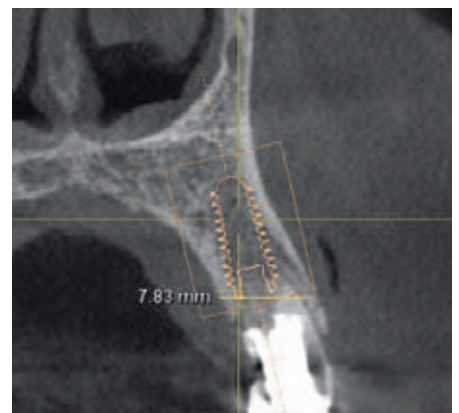
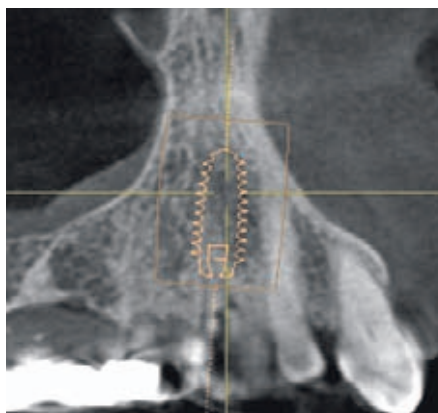


Fig. 5



chance of achieving the primary stability needed in this type of treatment.

### Surgical and prosthetic procedures

We started with the devitalization of 15 with both manual and mechanical instrumentation, and placed gutta-percha and AH Plus as root canal obturation materials (Fig. 6). The extraction of 14 was performed with as little trauma as possible (Fig. 7), in order to ensure that a satisfactory amount of tissue-support remained, maintain the two bone peaks under the papillae, and enable subsequent gingival conditioning with the laying of the temporary crown. We then performed the cystectomy of 15, creating a full-thickness flap and identifying the area. We then opened a trapdoor of cortical bone to allow us to access the lesion and remove it with a bone curette spoon (Fig. 8). In the excision of a cyst, even if in the context of unfavorable bone volume, it is important not to fill it with biomaterial as this makes it impossible to identify any subsequent

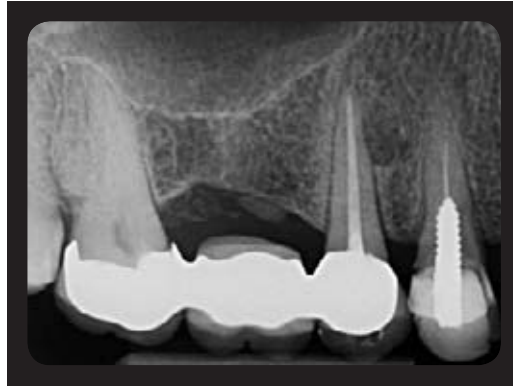

Fig. 6

flare-ups. We checked the site by staining it with Methylene Blue in order to be reasonably sure that all of the pathological tissue had been removed. We then filled the resulting void with PRF membranes obtained through the L-PRF Block protocol. In this case, we chose to include the use of PRF-membranes because, in our clinical experience, this promotes faster and more effective healing. Modern studies have shown the benefit and potential of white blood cells in the inflammatory process in stimulating osteoprogenitor cells. PRF captures all monocytes, making bone graft stimulation more efficient.

We placed a Roxolid® SLAactive® BLX implant with a diameter of 4.5 mm and a length of 12 mm at site 14 (Fig. 9), reaching a torque of 65 Newtons and an ISQ value of 73 (measurements taken using Mega ISQ, Osstell Technology), allowing us to confirm the treatment plan of immediate loading as previously defined, thanks also to the bone quality of the site. During implantation we measured a distance greater than 4 mm between the implant and the buccal alveolar wall (Fig. 10),

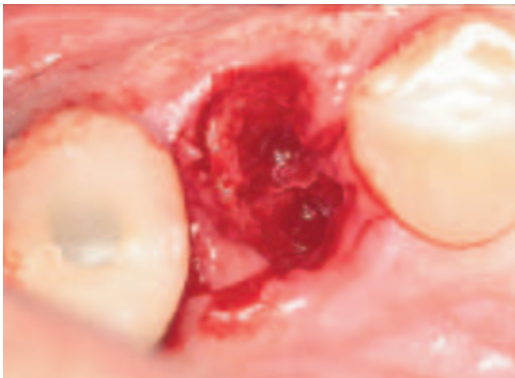


Fig. 7

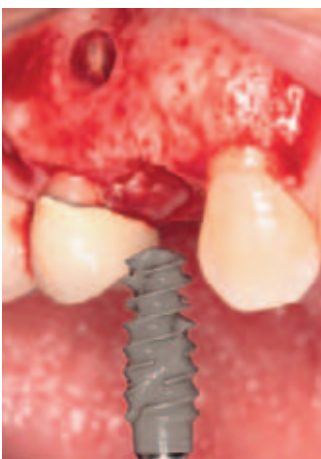

Fig. 8

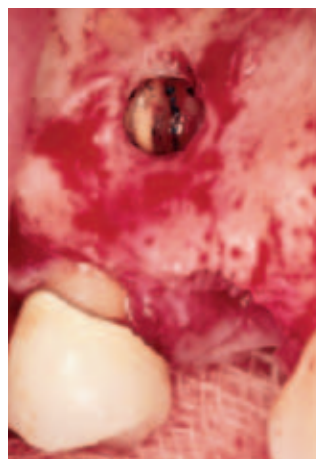

Fig. 9

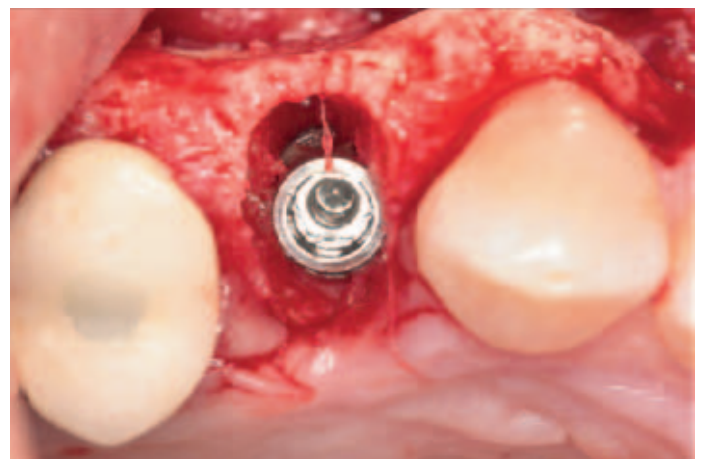

Fig. 10

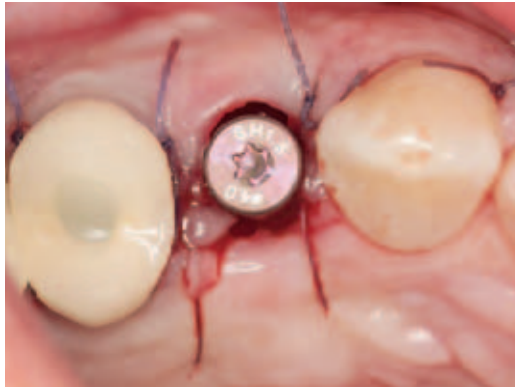

Fig. 11

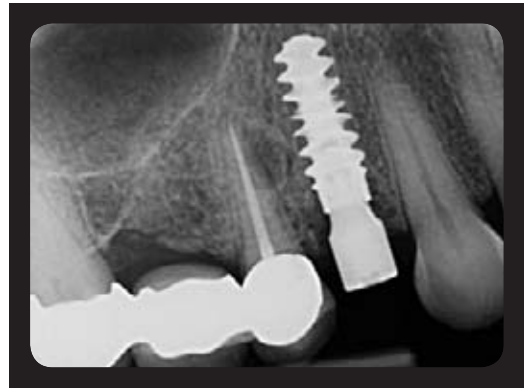

Fig. 12

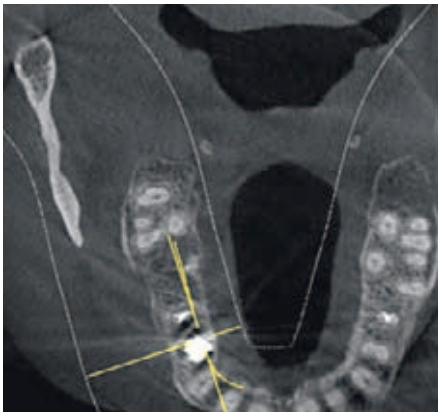


Fig. 13

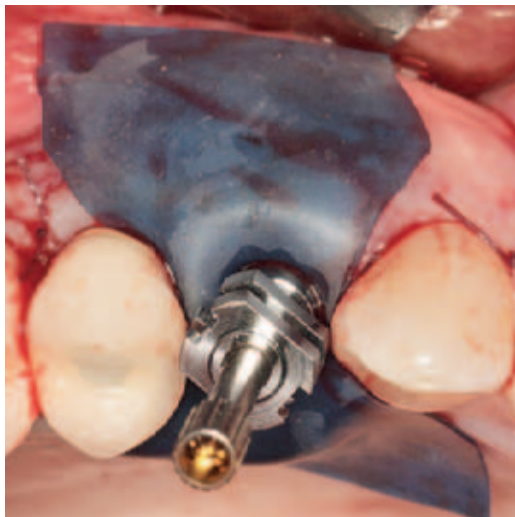
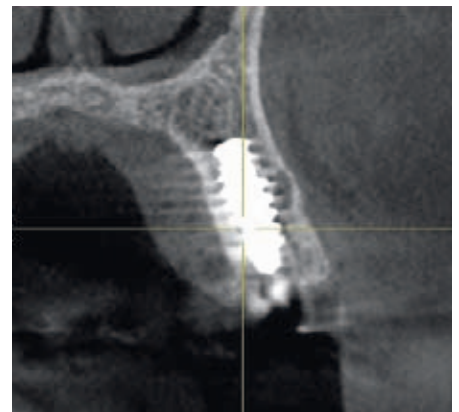
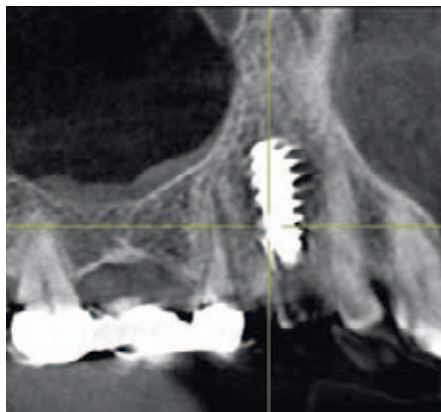

Fig. 14

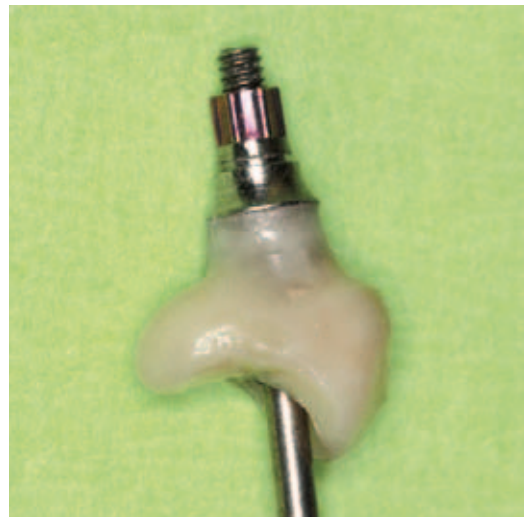

Fig. 15

so we only performed an interalveolar bone augmentation with bone regeneration material (Maxgraft allograft) previously mixed with L-PRF without increasing the risk of buccal over-contouring. Under the gingiva we reinforced the keratinized tissue around the implant using PRF membranes obtained with the L-PRF Block protocol, and sutured these with absorbable stitches (Vicryl, 5/0) (Fig. 11 to 13).

Immediately after the surgery, the prosthetic phase began: we protected the operative field with a rubber dam (Fig. 14), and, using an individual tray that had been previously created using the plaster cast, we took a precise impression with a polyether material (Permadyne, 3M ESPE) using the pick-up technique (open tray). A few hours later, the temporary screwed crown was delivered (Fig. 15 to 18), which the patient was to keep for 3 months before receiving the definitive crown, once both the soft and hard tissues had been

remodeled and renovated (Fig. 19). The temporary crown was designed to remain under-occluded, so as not to create excessive loads on the freshly-placed implant.

A monolithic zirconia crown was selected as the material for the definitive restoration, with a buccally -stratified and aesthetic veneer, as needed according to the level of exposure in the patient's smile (Fig. 20 to 25).

## TREATMENT OUTCOME

After 3 months, the soft tissues had been reconditioned and reshaped thanks to the provisional crown, ensuring a perfect emergence profile that was therefore suitable for the placement of the final crown. The patient, who was afraid to smile after her bad fall, was extremely satisfied with the result.

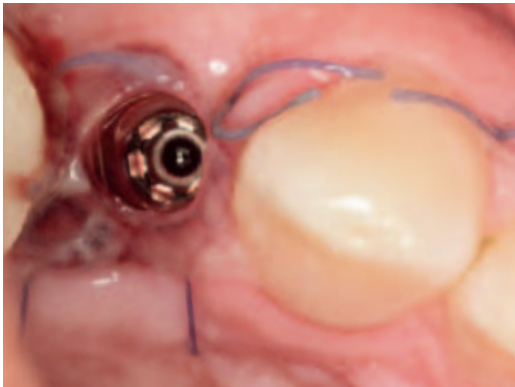


Fig. 16

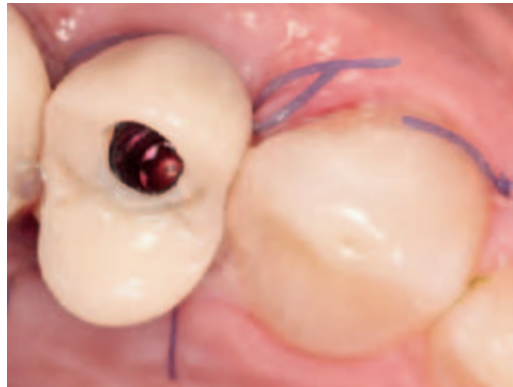

Fig. 17

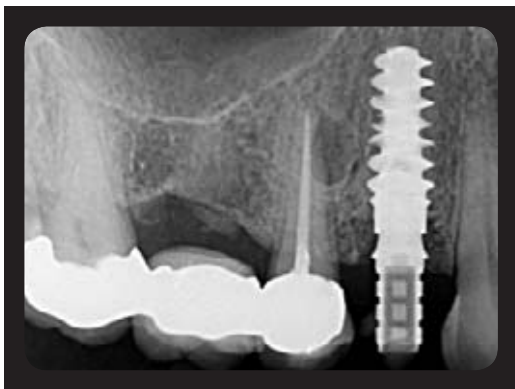

Fig. 18

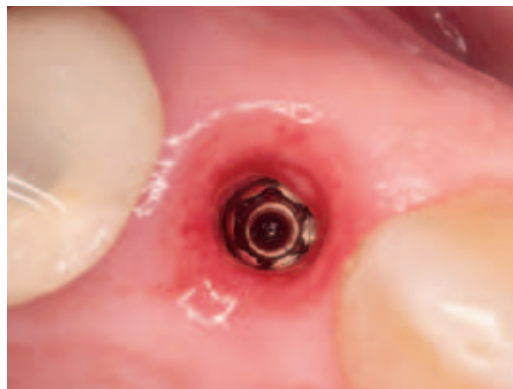


Fig. 19

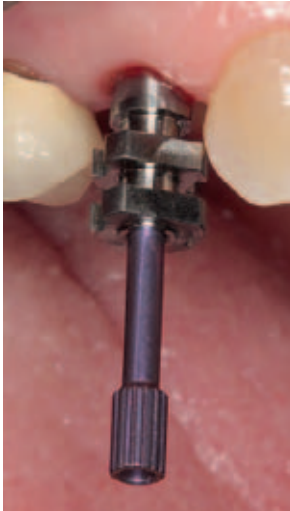


Fig. 20

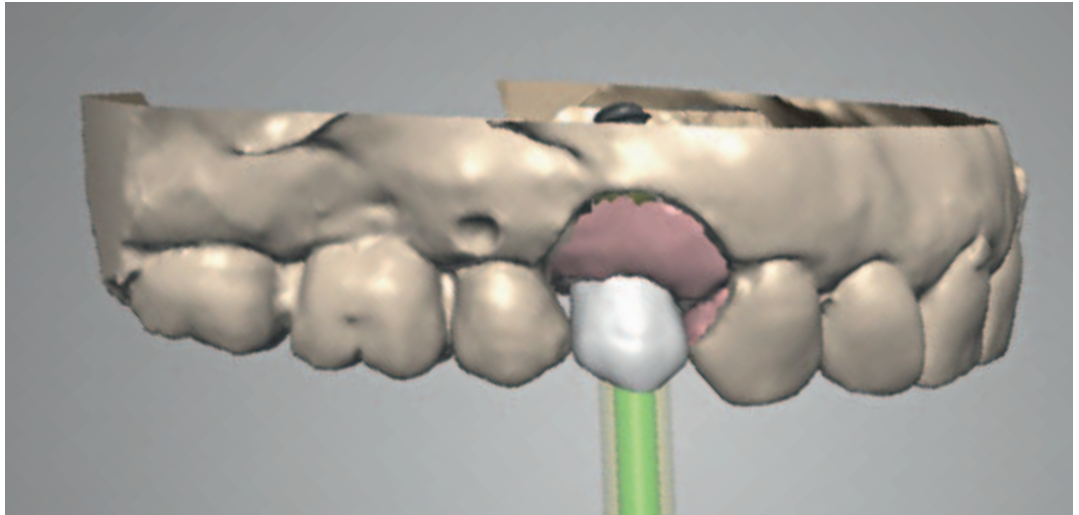


Fig. 21



Fig. 22



Fig. 23

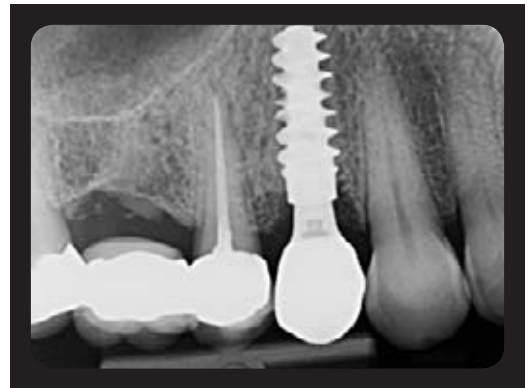

Fig. 24

## FINDINGS

We must remember not to focus solely on the central problem, but instead investigate each individual's case as a whole, in all its complexity, as in the case reported here. The BLX implants, with their innovative design (progressive thread design) and their bidirectional cutting, have been very helpful to us in the management of immediate loading, providing us with remarkable stability coupled with the Roxolid alloy and an excellent SLA Active surface supported by years of clinical trials.

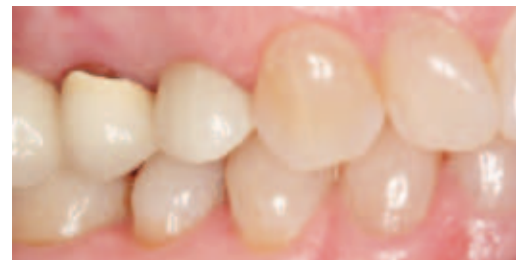

Fig. 25

## REFERENCES

1. M Chiapasco, *Manuale di chirurgia orale*, Edra Masson Ed., 2013.
2. Kawazoe T, Kim HH, *Tissue augmentation by white blood cell-containing platelet-rich plasma*, *Cell Transplant* 2012,21(2-3):601-7.
3. Capelli M, Testori T, Galli F, Zuffetti F, Motroni A, Weinstein R, Del Fabbro M. *The Implant-Vestibular Plate distance: a diagnostic parameter in immediate implant placement* *J.Periodont.* 2013.



EXCELLENCE IN IMMEDIACY

Straumann® SLActive®  
Performance beyond  
imagination.



Contact your local Straumann representative  
or visit: [www.straumann.com](http://www.straumann.com)

 **straumann**

# 10 years of SActive®

## Meeting with Professor David Cochran



Straumann has been unanimously recognized as the pioneer in surface technologies since the company introduced the SLA® surface that reduced the osteointegration time of its previous surface (TPS) from 12 to 6 weeks.

Since it was first studied in 1994, this macro- and micro-structured osteoconductive surface has become the industry's gold standard in surface technology.

In 2005, Straumann again turned the tide by introducing SActive®, a nanostructured and highly hydrophilic surface, this time optimizing things at the molecular level. This innovation further reduced healing times to only 3 to 4 weeks in most cases thanks to a highly accelerated osteointegration process.

**Professor Cochran, your work on surface topography has greatly contributed to the success but also to a better understanding of this technology. Historically, how do see the way Straumann implant surfaces have evolved, and what does this now famous phrase that characterizes the SLA® surface: “we have cut time in half” mean to you?**

We have been familiar with surface technologies since the 1970s. When we moved into the era of the SLA® implant, it all started with a brilliant observation in which Professor Steinemann was very involved, which resulted in the development of a highly osteoconductive surface. Then we switched to SActive®, which allowed molecular interactions to occur at the surface with titanium dioxide. It is this native chemical bond of titanium dioxide that makes SActive® so magical and that has made this innovation possible. We have been mastering this technology for decades now and it is all these years of expertise that have enabled us to have such advanced products today.

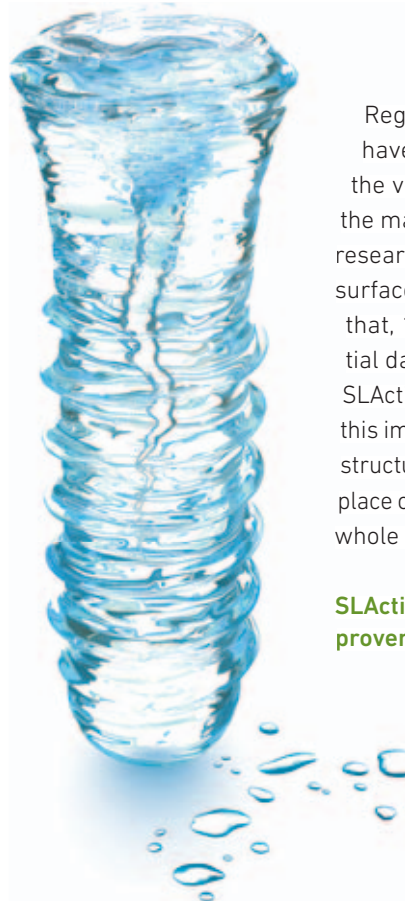### DAVID COCHRAN

David Cochran is Professor and Chairman of the Department of Periodontics at the University of Texas Health Science Center at San Antonio, School of Dentistry.

He is a Board Certified Periodontist and a past President of the American Academy of Periodontology and the Academy of Osseointegration.

He is ITI Fellow, ITI Speaker, Past President of the ITI and a member of the Board of Directors of the ITI.

He is an active basic science and clinical researcher who has received funding from both the NIH-NIDR and private industry. In 2010, Professor Cochran was awarded an honorary doctorate from the University of Bern in recognition of his contribution to implant dentistry.



Regarding SActive®, I am very fortunate to have been involved in its development since the very beginning, since it was released onto the market, and I was very involved in the initial research that set it apart from the SLA® implant surface. I think the most fantastic thing today is that, 15 years later, we see that it was the initial data that showed that the chemistry on the SActive® surface is the most important aspect of this implant. Only Straumann can offer this native structure of titanium and the chemistry that takes place on this surface, because Straumann has this whole history in the field of surface technology.

**SActive® is based on the scientifically proven SLA® topography, in addition to a fundamentally improved surface chemistry. What was the clinical challenge?**

The SActive® implant surface is the subject of many in-depth studies. It is the chemistry on this

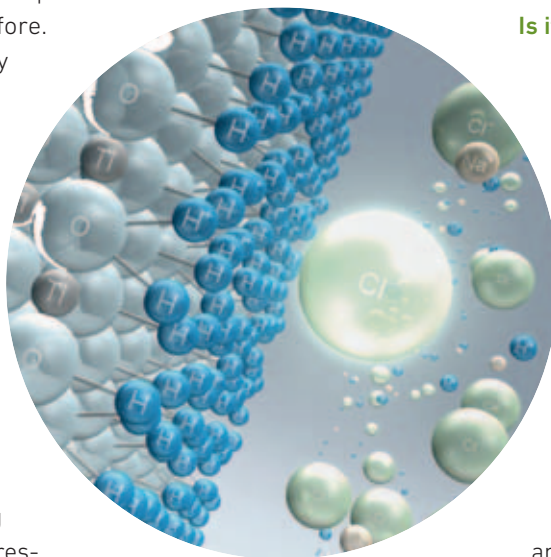
surface that allows everything else to occur around this implant. It is truly fabulous to study the process of bone formation that occurs around this implant through the chemistry that attracts proteins, blood, etc. to the surface, stabilizes the blood clot, and allows tissue to form around the implant in a way that's never been seen before.

The other thing that has really emerged today is that the initiation of this process really advances healing around the SLActive® implant, more than any other implant available on the market. This chemistry, combined with scientifically proven optimal surface topography for bone formation, ensures that contact between bone and implant is maximized. This, combined with a very strong bond between the implant surface and the surrounding bone, allows patients to receive their restorations at a very early stage and with a high level of confidence.

**The distinct nanostructures recently discovered on the SLActive® surface prove, for the first time, that the topography of the SLActive® surface differs from that of SLA®. What are the results of the advanced research?**

When it comes to this advanced healing, we now have very new data that show that the nanostructures that form on the SLActive® surface really provide us with a third level of roughness, which explains and reinforces why we obtain such phenomenal results with SLActive®. But all of this has very concrete and very clinical implications for every implantology surgeon. Treating compromised patients, with compromised sites or poor bone quality is a clinical challenge that we all face on a daily basis. According to the World Health Organization, approximately 425 million adults worldwide have diabetes. It is essential to offer these patients, as well as those in difficult treatment situations, a safer and more reliable implant treatment option. This is precisely the strength of a nanostructured surface like SLActive®. We can see today, in specific patient cohorts in which patients have been weakened

by radiation therapy or cancer treatments, or by severe diabetes, that SLActive® performs spectacularly in these patients and shows high success rates, allowing me as a practitioner to treat more patients in my office by using this surface.



**Is it fair to say that changes in the composition of dental implants and advances in surface technology have changed your treatment paradigms?**

After 25 years of evolution in the use of endo-osseous dental implants, first in edentulous patients and then in partially edentulous patients, it is relevant to ask what is the current state of technology in terms of implant composition, surface characteristics, and the design of the various components. It is clear that variations can exist in these three aspects and that the most relevant question is how biological tissues respond to these variations.

Today, innovations make it possible to obtain very high mechanical resistance in our implants thanks to the introduction of the Roxolid® titanium-zirconium alloy. This gain in resistance makes it possible to treat certain indications with narrower diameter or shorter implants, thereby reducing the morbidity of our treatments by reducing the need for bone

augmentation. The combination of this progress in terms of mechanical resistance with the nanostructured SLActive® surface will increase the clinician's confidence in treating situations previously considered compromised and reduce the invasiveness of implant treatment. In this sense, I think we can speak of a paradigm shift. Thanks to the work of Straumann over the past sixty years, we are able to better treat our patients and provide them with a better prognosis. I can sincerely say that Straumann can be proud of its innovations, which have not only improved the quality of its products, but have also changed the data acquired from science.

Professor Cochran, thank you for this informative and interesting interview.

*Interview conducted  
by Daniela Albu.*

# Dental implant surfaces

## Nanostructures enhance osseointegration



### MICHEL M. DARD

DDS, MS, PhD


Global Medical Director

Head of Medical Affairs  
Straumann Group  
Peter Merian Weg 12  
Basel, Switzerland

Associate Professor,  
Section of Oral,  
Diagnostic and  
Rehabilitation Sciences

Columbia University,  
New York, United States  
of America

[michel.dard@straumann.com](mailto:michel.dard@straumann.com)



### RAPHAEL S. WAGNER

Ph.D. in Nanosciences,  
University of Basel, Switzerland

Head of Surfaces Research,  
Straumann Group  
Peter Merian Weg 12  
Basel, Switzerland

## INTRODUCTION

One of the key factors for implanted medical devices in dentistry and orthopedics is the successful osseointegration of the implant with the host bone.

Clinical success of dental implants can be influenced by a number of factors, including the age, general health and disease status of the patient, and the quality of the host bone (Variola et al. 2011; Gittens et al. 2013). Innovations in implant dentistry led to new implant systems and surfaces. Hence it is becoming ever more important to obtain long-term clinical data on the implants available. Over recent decades, a number of paradigm shifts have changed our understanding of how the surface characteristics of biomaterials influence biological response. Researchers have

constantly striven towards improving the osseointegration potential of implants beyond those of early smooth titanium surfaces. This research resulted in surface modification techniques, such as coatings (e.g. hydroxyapatite, titanium plasma spraying) and physical treatments (e.g. grit blasting (mechanical), acid etching (chemical) or anodic oxidation (electrochemical) (Salou et al. 2015).

These modifications can increase the available surface area at the implant-bone interface; more surface area means more opportunities for proteins and bone-forming cells (osteoblasts) to populate and form new bone around the implants, and also greater stability, as the newly forming bone interlocks in and around the micrometer-scale nooks and crannies formed by the roughened surface (Gittens et al. 2013; Abraham 2014; Salou et al. 2015).

We perceived how roughness as well as hydrophilicity contributes to improving the cellular contact and osseointegration of titanium dental implants. Very recently, Rupp et al. documented the synergistic effects of nanoscale topographic characteristics and hydrophilicity at the implant/bone interface (Rupp et al. 2018).

With improved osseointegration potential it can be expected that implants will perform even better in clinically challenging situations.

### Optimizing the performance of dental implants: Ti versus TiZr

Since the beginning of the 1990s, titanium/zirconium (TiZr) alloys have attracted considerable attention as a material for dental use.

The research by Steinemann (1998) on TiZr surgical implants was followed by that of Bernhard et al. (2009) who published their findings on a binary TiZr alloy called Roxolid® containing 13–17% Zr and was developed exclusively for dental implants.

Pure titanium and high-strength TiZr alloy exhibit micro- and nanostructures on hydrophilic surfaces. These factors play a vital role in the success of TiZr implants. Although a number of parameters may influence biological response to TiZr implant surfaces, hydrophilicity and macro-, micro- and nano-roughness seem to contribute most to a favorable osteoblastic (and even immunological) response as well as to faster implant osseointegration (Hotchkiss et al. 2016 and 2017).

The surface properties of Ti implants have been identified as one of the most determining factors in the reaction of tissue to dental implants and degree of osseointegration achieved (Albrektsson et al. 2004; Ellingsen et al. 2006).

Cell surface receptors recognize biological and topographic surface changes, Boyan et al. (2016) emphasized the impact of surface topography on mesenchymal cell response and differentiation into the osteoblast lineage.

TiZr alloy stands apart from any of the  $\alpha\beta$  structured alloys in that it maintains the same  $\alpha$  structure as cpTi.

For that reason the SLActive® surface treatment is directly transferable from Ti to TiZr while maintaining hydrophilicity and roughness.

Nanostructures were found on both Ti, TiZr hydrophilic SLActive® surfaces (Wennerberg et al. 2012) (Fig. 1 and 2), although they differ in their size and density. Metals grain size influences

the mechanical properties, since the smaller the grains, the greater the number of grain boundaries, and so the more dislocation movement is impeded (Hall–Petch relationship) (Fig. 3 a and b).

Because grain size is markedly smaller in the initial state (1 to 2  $\mu\text{m}$ ), the TiZr alloy is 10 to 15% stronger than grade 4 Ti without sacrificing any of its fracture strength (Medvedev et al. 2016).




Fig. 1 Nanotopographie of Roxolid Slactive. Distinct nanostructures develop on the surface of Roxolid Slactive during a proprietary production process.


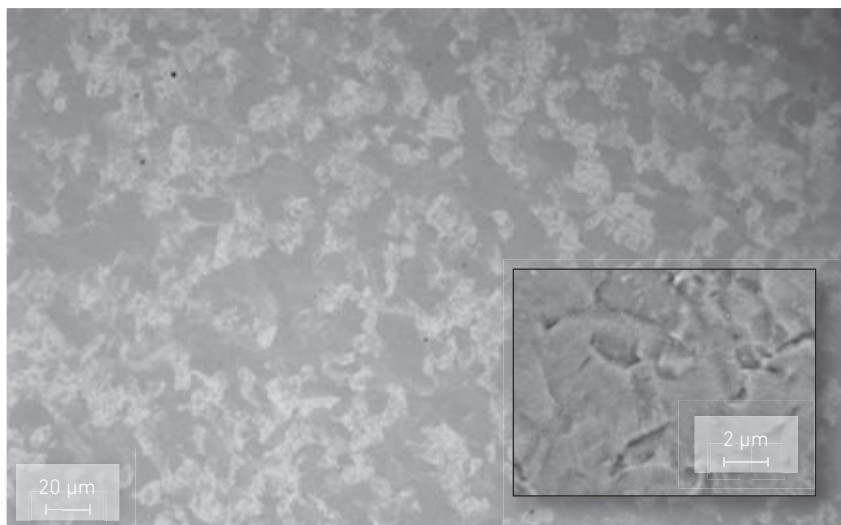



Fig. 2 Nanotopography of Titanium SLActive.



**Fig. 3a** Titanium grade 4 grain boundaries.



**Fig. 3b** Roxolid grain boundaries.

Targeting understanding enhanced osseointegration kinetics, the goal of the study by Murphy et al. (2017) was to characterize the surface morphology and composition of Ti and TiZr dental implant substrates subjected to one of two surface treatments developed by Straumann. These two treatments are typically known as SLA and SLActive, with the latter resulting in more rapid osseointegration.

Consistent with previous work, surface morphology was found to differ only at the nanoscale between SLA and SLActive, with both SLActive substrates displaying nano-protrusions on Ti and TiZr. All substrates exhibit a titanium oxide layer. Amorphous TiO<sub>2</sub> is most likely the only phase present on TiSLA, whilst rutile-TiO<sub>2</sub> is also evidenced on TiSLActive, TiZrSLA, and TiZrSLActive.

### Nanotechnology in medical device applications

Research in recent years has focused particularly on ways of improving the microenvironment around implants. The intention is not just to provide a surface that is conducive to osseointegration, but to actively promote osseointegration by stabilizing the initial coagulum around the implants, attracting bone-forming cells, enhancing cell differentiation and triggering activation of the molecules involved in the process (Variola et al. 2011; Streicher et al. 2007; Chan et al. 2015; Feller et al. 2015). More recently, the advent of nanotechnology has become an important part of the armamentarium used to optimize medical devices and implants, since bone itself is a nanocomposite material comprising organic and inorganic elements. Nanomedicine, i.e. the exploitation of nanoscale particles, capsules, coatings and structures to enhance treatment, is one of the most rapidly growing areas of medicine.

One example of this is the use of nanomaterials and/or nanoparticles to inhibit the growth of biofilm on implantable medical devices through the creation of surfaces that are resistant to microorganisms (Streicher et al. 2007; Naik et al. 2015). Promising results have been observed with several metal oxides (e.g. TiO<sub>2</sub>, ZnO, CuO, etc.), transition metals (Ag, Cu, Zn, Au) and polymer-based materials (e.g. polyethylene glycol (PEG)-coated polyurethane, polycarbonate and PEG copolymers, etc.) in controlling or preventing biofilm-associated infection (Naik et al. 2015). This concept has been extensively used in implanted drug delivery systems and drug-eluting coatings to prevent infection. (Naik et al. 2015; Saiz et al. 2013; Mazaheri et al. 2015; Ramos et al. 2017).

Other implantable nanomaterials have been used in orthopedics to enhance biocompatibility and mechanical properties, especially with metallic devices (Mazaheri et al. 2015). For example, bioinert, nanocrystalline or ultrafine-grained

high-strength titanium can be made using severe plastic deformation techniques. These have exhibited superior biological responses. Nanostructuring of other materials, such as selenium, has shown promise in orthopedic anticancer applications (Mazaheri et al. 2015). Nanostructured surfaces have also improved fracture resistance in bioceramics, with the added benefit that the ceramics can be sintered at lower temperatures. The addition of nanofibrous structures to natural polymers, which already show good biological activity and biocompatibility, greatly increases their scope for use in bone or cartilage tissue engineering. Recent additions to the growing list of nanocomposite materials in orthopedics include carbon nanostructures such as graphene, and carbon nanotubes and fibers.

Nanostructured biomaterials have been particularly beneficial in the use of spinal implants, thanks to the synergistic effect of the combination of micro-roughness with nanoscale structuring (Gittens et al. 2014). Likewise, nanoscale materials are proving to be ideal in bone engineering, for example in the repair and regeneration of bone defects in orthopedics (Saiz et al. 2013; McMahon et al. 2013). Nanotechnology makes it possible to minutely tailor the surface chemistry and structure of bone scaffold materials (Saiz et al. 2013), due to a combination of strength, bioactivity and biocompatibility, the promotion of cellular adhesion, proliferation and differentiation, as well as protein adsorption (McMahon et al. 2013). There has also been significant research interest in the use of nanoparticles to deliver bone morphogenetic proteins (BMPs) directly at the bone repair site (McMahon et al. 2013). While bone engineering may be the most obvious application of nanotopography, there is also tremendous potential in other forms of tissue engineering; these include the development of three-dimensional (3D) organs for repair or regeneration of, e.g., skin, ear, liver and kidney, where nanotopography can influence mesenchymal stem cells through guided differentiation, for example (Salmasi et al. 2015).

### **Nanotechnology in dental implantology**

The investigation, development and potential of nanoscale surface modifications in dental implantology has been every bit as intense as

that in medicine. Indeed, some of the most significant advances have come directly from dental implantology research (Gittens et al. 2014). The more recent generations of dental implant surfaces exhibit nanostructures that are lacking in their predecessors (Wennerberg A et al. 2010). Moreover, because of the huge range of factors that can have an adverse influence on their long-term success, combined with increasing patient demand for reduced overall treatment times and increasing numbers of compromised patients, the potential benefits of nanoscale surface modification may be even greater than in orthopedics. Research into nanotechnology applications for dental implants has also allowed for a greater understanding of certain cell functions (Mendonça et al. 2008).

As with topographical analysis, measures of the wettability of implant surfaces are a challenge.

Current research (Rupp et al. 2018) has focused on topography and has primarily attempted to optimize surface micro-roughness. In this field remains of the highest importance, because many questions subsist regarding what topography is best for bone and soft tissue contact. Besides surface topography, this new paradigm also includes the role of wettability in interfacial biological response and takes account of the interdependent effects of topography and wettability. This relates not only to phenomena such as roughness-induced wettability (Rupp et al. 2018; Gittens et al. 2014) but also to very recent discoveries about the role of nanostructured surfaces and the synergistic effects of nanostructuring and hydrophilicity (Wennerberg et al. 2014).

Several methods have been employed for the nanoscale modification of dental implants, including ion beam deposition, acid or alkali treatment, peroxidation, anodization, nanoparticle deposition (e.g. crystalline or sol-gel), chemical vapor deposition, and plasma spraying, blasting, and sputtering (Mendonça et al. 2008; Bressan et al. 2013; Pachauri et al. 2014).

Studies have shown that greater surface roughness, imparted by nanoscale modifications, results in greater bone-to-implant contact, and that nanoscale properties increase the likelihood of factors related to favorable peri-implant osteogenesis, such as osteoblast adherence (Pachauri et al. 2014). In particular, nanostructures show a profound influence on the proliferation

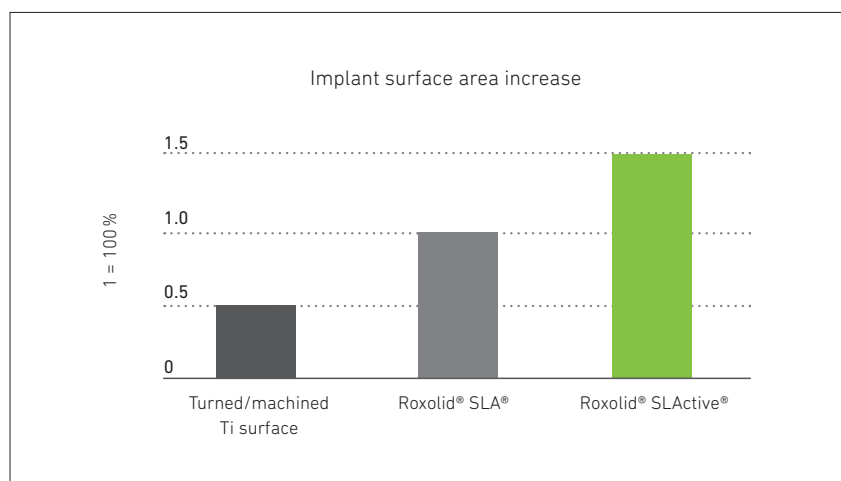


Fig. 4 Increase of the surface area due to nano-roughness on Roxolid® SLActive.

of osteoblasts compared to microstructured or smooth surfaces (Goldman et al. 2014). Recent evidence also indicates that nanoscale modification can substantially influence the differentiation and maturation of stem cells into osteoblasts, a key factor in rapid osseointegration (Boyan et al. 2016).

### A unique nanostructured surface

Straumann has always been a leader in the optimization of dental implant surfaces to improve osseointegration, and this is also true in the rapidly moving world of nanomedicine and nanotechnology. The SLActive® surface (modSLA in the literature) is one of the most well-investigated hydrophilic dental implant surface, and has consistently demonstrated increased biological signals crucial to rapid osseointegration, such as osteoprotegerin, osteocalcin and alkaline phosphatase (Wennerberg et al. 2011).

The SLActive® manufacturing process prevents any contamination from the ambient environment (atmospheric hydrocarbons) and ensures the surface remains chemically active by treating the implants after acid etching under protective gas allowed by storage in saline solution (Rupp et al. 2006). Studies show that this type of surface improves initial healing reactions, thereby accelerating integration (Schwarz et al. 2009, Wennerberg et al. 2011).

Acid etching of Ti implants yields an unsaturated surface texture. After storage in saline

solution, this high-energy surface has been shown to possess very low carbon content (15% versus 35% in the unmodified sandblasted or etched surface) as well as super hydrophilicity. Recent investigations also show that, as well as hydrophilicity and enhanced healing compared to the SLA surface, SLActive also has a fundamentally different topography, in that nanostructures are present where the SLA surface has none; this is true of the surface on both Ti and TiZr (Wennerberg et al. 2013; Kopf et al. 2015; Lotz et al. 2017; Murphy Walczak MS et al. 2017).

Nanostructures have a profound effect on the early phases of osseointegration, partly as a result of macrophage activation and increased levels of interleukin (IL)-4 and IL-10, producing an anti-inflammatory environment, particularly on TiZr (Hotchkiss et al. 2016; Hotchkiss et al. 2017). As previously mentioned, increased surface roughness means more opportunities for the osteoblasts to populate the complicated topography of the implant surface. In the case of SLActive, nanostructures on the surface increase the available surface area by about 50% (Fig. 4) (Wagner R, Berner S 2017, unpublished data).

The combination of hydrophilicity and nanostructures appears to have a synergistic effect, resulting in enhanced osteogenic response (Lotz et al. 2016) and particularly strong osseointegration (Wennerberg et al. 2014). In vitro, blood coagulation (i.e. early clot formation) was greater with a nanostructured, hydrophilic surface, and this combination also resulted in much greater protein adsorption (e.g. fibrinogen, fibronectin), and in the formation and stabilization of the fibrin network (Müller et al. 2017). Deposition of Ca<sup>2+</sup> was also much greater on hydrophilic, nanostructured SLActive surfaces (Müller et al. 2017). Bone response, in terms of bone cell mineralization, has also been found to be much greater with hydrophilic, nanostructured SLActive surfaces, possibly resulting in greater density and subsequent differentiation of human bone and progenitor cells (Müller et al. 2017). More osteoblasts attach to the SLActive surface compared to SLA, and osteogenic differentiation is greater and faster, with enhanced expression of collagen-1 and alkaline phosphatase (osteogenic marker proteins) on the cell surface (Kopf et al. 2015). These effects were not seen with hydrophilicity alone, where the formation of the fibrin network and bone



mineralization were lower (Müller et al. 2017). Bone response is particularly strong on TiZr compared to Ti; early expression of cytokines and markers for bone formation and remodelling is significantly greater on TiZr (Galli et al. 2017), and higher bone-to-implant contact and removal torque values have been recorded (Galli et al. 2017, Jimbo et al. 2017). A study by Schwarz et al. found that SLActive® provides a larger accessible surface area for increased blood protein adsorption (Kopf et al. 2015). Moreover, in preclinical studies, osteoblast differentiation and increased production of the bone-building protein osteocalcin have been observed (Zhao et al. 2005, Gu et al. 2013) as well as stimulated blood vessel growth (Schwarz et al. 2008).

### Time to osseointegration and early and immediate loading protocols

The SLActive® surface accelerates bone maturation (Buser et al. 2004, Schwarz et al. 2007). Higher bone cell mineralization has been described in a preclinical study and confirmed by an in vitro study. It has also been histologically confirmed that healing is faster with SLActive®, as evidenced by higher bone-to-implant contact after 2 weeks and significantly higher contact after 4 weeks of healing (Lang 2011) (Fig. 5).

A shorter healing time not only makes early loading possible but improves safety by shortening the critical healing phase. In addition, Roxolid® SLActive® implants have displayed superior osseointegration compared to SLActive® Ti implants (Gottlow et al. 2012, Wen et al. 2013).

It has been demonstrated that implants with the SLActive® surface treatment can be successfully used in early or immediate loading protocols without compromising treatment outcome or predictability (Nicolau et al. 2013, Bornstein et al. 2010, Buser et al. 2013).

With regard to these early and immediate loading protocols, a recent study demonstrated that, after an initial remodeling phase of 5–6 months, no differences could be found between the immediate and early loading groups, with the survival rates being 98.2% and 97.1%, respectively (Nicolau et al. 2016).

Recent clinical studies have shown that SLActive® implants were successfully placed in patients with low quality bone (type 4 according to the Lekholm and Zarb classification) with 100%

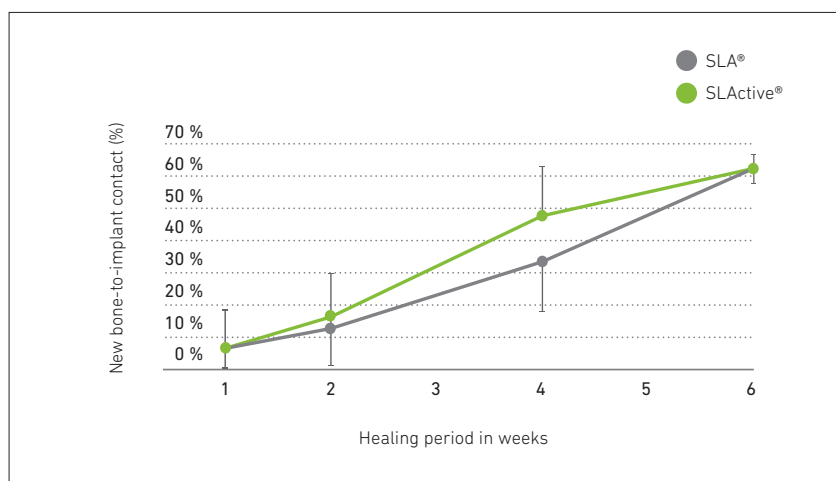


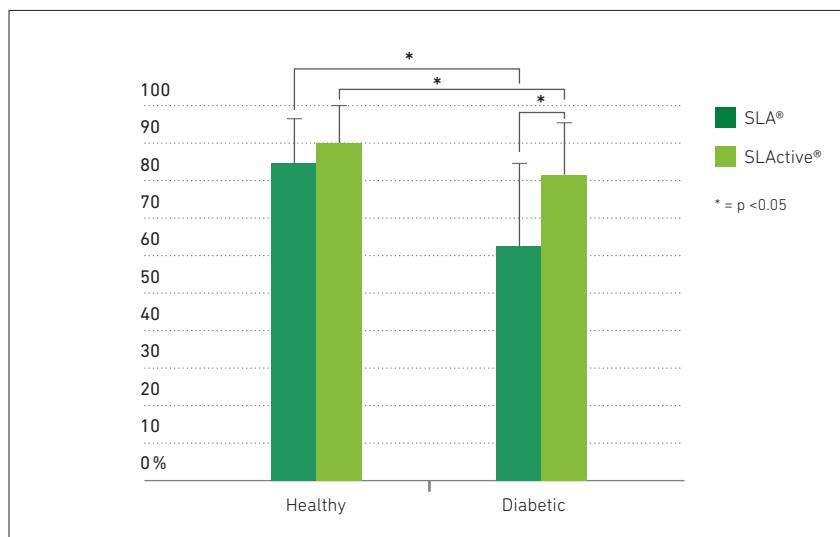
Fig. 5 Higher bone-to-implant contact (BIC) after 2 weeks and significantly higher BIC after 4 weeks of healing.

overall success rates in immediate and early loading protocols (Ganeles et al. 2008, Nicolau et al. 2013, Bergkvist et al. 2010, Markovic et al. 2015).

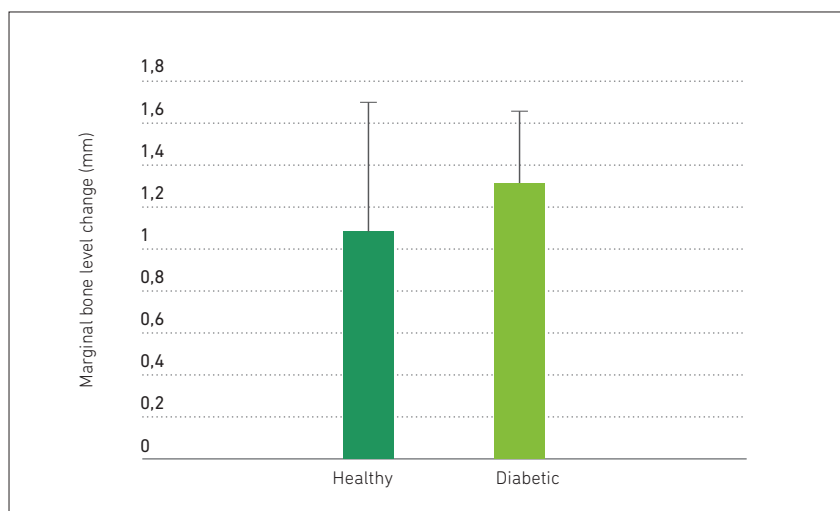
Straumann Roxolid® SLActive® implants have been tested in highly complex indications, and good treatment results have been reported.

Clinical studies have been conducted in challenging clinical situations such as:

- Placement of implants in a horizontally augmented maxillary sinus, with a 97% survival rate at 1 year (Lindgren et al. 2010);
- Dehiscence defects after implant placement, with a 100% survival rate at 1 year (Van Assche et al. 2013);
- Early loading in the posterior maxilla, with a 100% survival rate at 1 year (Roccuzzo and Wilson 2009);
- Immediate loading of hybrid prostheses supported by two implants, with a 99% survival rate after up to 40 months (Stoker et al. 2011);
- Rehabilitation of edentulous atrophic maxillae supporting a hybrid prosthesis, with a 100% survival rate after up to 16 months (Cordaro et al. 2013);
- In a study by Slotte et al. (2012) in patients with atrophic posterior mandibular ridges, 4 mm implants (Straumann® Standard Plus Short) were used to avoid vertical augmentation procedures. A 5-year implant survival rate of 94% was reported.



**Fig. 6** Bone-to-implant contact (%) at 90 days for SLA® and SLActive® implants in healthy and diabetic animals (Schlegel et al. 2013).



**Fig. 7** Marginal bone level change (mm) between healthy and diabetic individuals with SLActive® implants at 6 months of follow-up (Cabrera-Domínguez et al. 2016).

A systematic review summarized the existing clinical evidence on TiZr dental implants (Altuna et al. 2016). Nine studies using TiZr implants were identified following a systematic search of the Medline database in 2014.

In total, 607 patients received 922 implants. Mean survival and success rates were 98.4% and 97.8% at 1 year after implant placement, and 97.7% and 97.3% at 2 years. TiZr narrow diameter

implants displayed similar short-term survival and success rates to normal-sized Ti implants (> 95%).

In addition to very high implant success rates, general patient satisfaction 10 years after implant placement has been assessed as excellent by over 90% of patients with SLActive® implants (88.2% and 93.3% in the early and immediate loading groups, respectively).

Moreover, patient satisfaction regarding comfort, appearance, ability to chew, and ability to taste has been rated as excellent by more than 76% of patients (Nicolau et al. 2016).

### New treatment options for compromised patients

The nanostructured, hydrophilic SLActive surface on both Ti and TiZr supports the early cellular phases of osseointegration, help rapid formation of the blood coagulum and fibrin network, and increase bone mineralization and osteogenic differentiation. The combination of hydrophilicity and nanotopography is therefore beneficial for enhanced implants osseointegration in healthy and likely in compromised patients too.

According to findings from animal studies, unstable blood glucose levels can influence osseointegration by interfering with bone resorption and formation (Takeshita et al. 1997, Nevins et al. 1998, Fiorellini et al. 1999, McCracken et al. 2000).

In a study conducted in diabetic animals, SLActive® implants displayed better bone-to-implant contact values than did implants with SLA® surface treatment (Schlegel et al. 2013) (**Fig. 6**).

Roxolid® SLActive® implants placed in diabetic patients yielded 100% success rates after 6 months of follow-up as well as marginal bone level changes similar to healthy subjects (Cabrera-Domínguez et al. 2016) (**Fig. 7**).

A new clinical study that compared SLActive® performance in patients with and without diabetes showed the performance of SLActive® implants was uncompromised. The implant success rate was 100% in the diabetic group after 2 years, and their bone changes were similar to those of healthy individuals (Cabrera-Domínguez 2017).

What is more, in a study by Khandelwal et al. (2013), SLActive® implants placed in patients with poorly controlled type II diabetes mellitus yielded

a 100% survival rate 16 weeks after placement (Oates 2016) (Fig. 8).

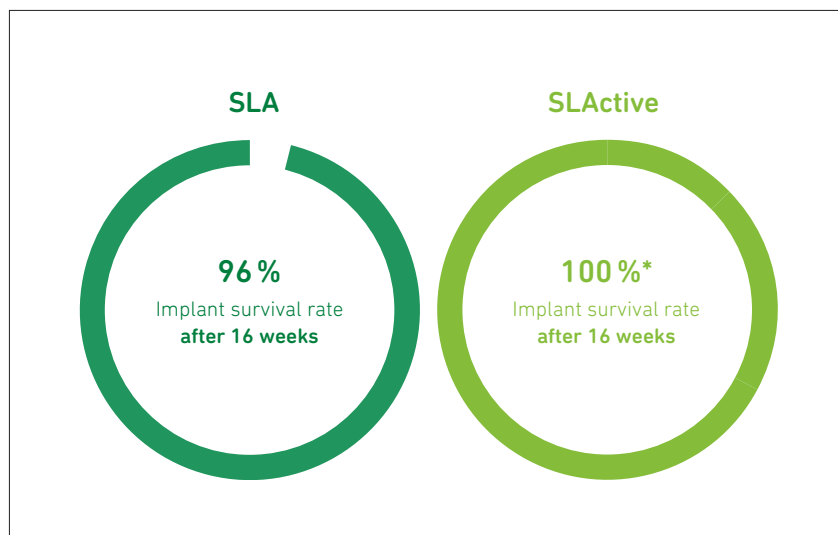
A new in vitro study shows that the Roxolid® SLActive® surface stimulates an early anti-inflammatory cellular response compared to non-SLActive® surfaces, as evidenced in vitro by a reduction in pro-inflammatory markers (Hotchkiss et al. 2017).

SLActive® is associated with an increased anti-inflammatory macrophage response during the early healing phase in both healthy and diabetic animals. This may be an important mechanism for improving bone healing in compromised subjects with systemic conditions (Lee et al. 2016).

A clinical study evaluated the success rates of both conventional (SLA®) and chemically modified (SLActive®) implants in patients receiving radiation therapy following the removal of a malignant tumor (oral squamous cell carcinoma). The authors demonstrated that implants with the SLActive® surface could be placed in such patients with a high likelihood of success. The overall survival rate of implants with the SLActive® surface treatment was 100% after 14 months and 5 years, while the crestal bone levels of these patients remained stable during the 5 years after implant placement (Heberer et al. 2011, Nack et al. 2015, Nelson et al. 2016).

Crestal bone level remained stable during the 5 years after placement, while the surface micro-roughness and hydrophilicity of the SLActive® implants only influenced osseointegration at the beginning of the healing phase (Nack et al. 2015).

These studies demonstrate in a remarkable fashion that SLActive® implants can also be successfully used in highly complex indications involving patients with a compromised state of health. The hydrophilic SLActive® surface improves healing compared with hydrophobic surfaces. Accelerated osseointegration also makes this implant an excellent treatment option for medically vulnerable patients.



**Fig. 8** Survival of SLA® vs. SLActive® implants in patients with poorly controlled type II diabetes at 16 weeks of follow-up (Khandelwal N et al. 2013).

\*T. Oates 2016, personal communication.

## CONCLUSION: TOWARD PERSONALIZED DENTAL MEDICINE

The emergence of new technologies is contributing to a better understanding and control of how tissues respond to implant surfaces, down to the nanoscale, thereby resulting in the generation of high performing implants even if placed in clinical challenging situations. These biotechnological advances in implant dentistry will enable to treat patients according to specific oral and general clinical situations leading to public health improvements.

### Acknowledgements

The authors thank Philippe Habersetzer and Yves Bisselbach, Technology and Testing Group, Institute Straumann, Basel, Switzerland and the Nano Imaging Laboratory of the Swiss Nanoscience Institute, University of Basel, Switzerland for their contributions to the surfaces imaging.

## REFERENCES

- Abraham CM. A Brief Historical Perspective on Dental Implants, Their Surface Coatings and Treatments. *Open Dent J*. 2014;8(Suppl 1-M2):50–5
- Al-Nawas B, Domagala F, Ortiz-Vigón A, Rousseau P, et al. A Prospective Noninterventional Study to Evaluate Survival and Success of Reduced Diameter Implants Made From Titanium-Zirconium Alloy. *J Oral Implantol*. 2015 Aug;41(4):e118–25.
- Al-Nawas Q, Razavi M, Schimmel R, Romeo S. Small-diameter titanium Grade IV and titanium-zirconium implants in edentulous mandibles: three-year results from a double-blind, randomized controlled trial. *Clin Oral Implants Res*. 2015;26(7):831–40.
- Altuna E, Lucas-Taulé J, Gargallo-Albiol O, Figueras-Álvarez F, Hernández-Alfaro J, Nart. Clinical evidence on titanium-zirconium dental implants: a systematic review and meta-analysis. *International Int J Oral Maxillofac Surg*. 2016 Jul;45(7):842–50.
- Badran Z, Struillou X, Strube N, Bourdin D, Dard M, Soueidan A, Hoornaert A. Clinical Performance of Narrow-Diameter Titanium-Zirconium Implants: A Systematic Review. *Implant Dent*. 2017 Apr;26(2):316–323.
- Bernhard, N.; Berner, S.; De Wild, M.; Wieland, M. The binary TiZr alloy—A newly developed Ti alloy for use in dental implants. *Forum Implantol*. 2009, 5, 30–39.
- Bornstein MM, Wittneben JG, Brägger U, Buser D.: Early loading at 21 days of non-submerged titanium implants with a chemically modified sandblasted and acid-etched surface: 3-year results of a prospective study in the posterior mandible. *J Periodontol*. 2010 Jun;81(6):809–18.
- Boyan BD, Cheng A, Olivares-Navarrete R, Schwartz Z. Implant Surface Design Regulates Mesenchymal Stem Cell Differentiation and Maturation. *Adv Dent Res*. 2016;28(1):10–7.
- Bressan E, Sbricoli L, Guazzo R, Tocco I, Roman M, Vindigni V, et al. Nanostructured Surfaces of Dental Implants. *Int J Mol Sci*. 2013;14(1):1918–31.
- Buser D, Brogginini N, Wieland M, Schenk RK, Denzer AJ, Cochran DL, Hoffmann B, Lussi A, Steinemann SG: Enhanced bone apposition to a chemically modified SLA titanium surface. *J Dent Res*. 2004 Jul;83(7):529–33
- Buser D, Chappuis V, Kuchler U, Bornstein MM, Wittneben JG, Buser R, Cavusoglu Y, Belser UC. Long-term Stability of Early Implant Placement with Contour Augmentation. *J Dent Res*. 2013 Oct 24 [Epub ahead of print].
- Cabrera-Dominguez J. A prospective, two-year clinical trial of titanium-zirconium alloy implants (Roxolid® Straumann®) with hydrophilic surface (SLActive®) in patients with Type 2 Diabetes Mellitus. presented during 26th Annual Scientific Meeting of the European Association of Osseointegration – 5-7 Oct 2017, Madrid, Spain.
- Cordaro L, Torsello F, Mirisola di Torresanto V, Baricevic M.: Rehabilitation of an edentulous atrophic maxilla with four unsplinted narrow diameter titanium-zirconium implants supporting an overdenture. *Quintessence Int*. 2013 Jan;44(1):37–43.
- Chan KH, Zhuo S, Ni M. Priming the Surface of Orthopedic Implants for Osteoblast Attachment in Bone Tissue Engineering. *Int J Med Sci*. 2015;12(9):701–7.
- Chrcanovic BR, Albrektsson T, Wennerberg A. Smoking and dental implants: A systematic review and meta-analysis. *J Dent*. 2015 May;43(5):487–98
- Devlin H, Garland H, Sloan P. Healing of tooth extraction sockets in experimental diabetes mellitus. *J. of Oral Maxillofac. Surg*. 1996; 54:1087–1091
- Feller L, Jadwat Y, Khammissa RAG, Meyerov R, Schechter I, Lemmer J. Cellular Responses Evoked by Different Surface Characteristics of Intraosseous Titanium Implants. *Biomed Res Int*. 2015:171945.
- Fiorellini JP, Nevins ML, Norkin A, Weber HP, Karimbux NY. The effect of insulin therapy on osseointegration in a diabetic rat model. *Clin Oral Implants Res*. 1999 Oct;10(5):362–8
- Galli S, Jimbo R, Naito Y, Berner S, Dard M, Wennerberg A. Chemically modified titanium-zirconium implants in comparison with commercially pure titanium controls stimulate the early molecular pathways of bone healing. *Clin Oral Implants Res*. 2017;28(10):1234–40.
- Gittens RA, Olivares-Navarrete R, Cheng A, Anderson DM, McLachlan T, Stephan, I, et al. The roles of titanium surface micro/nanotopography and wettability on the differential response of human osteoblast lineage cells. *Acta Biomater*. 2013;9(4):6268–77
- Gittens RA, Olivares-Navarrete R, Schwartz Z, Boyan BD. Implant osseointegration and the role of microroughness and nanostructures: Lessons for spine implants. *Acta Biomater* 2014b;10(8):3363–71.
- Gu YX, Du J.; Si MS, Mo JJ, Qiao SC, Lai HC The roles of PI3K/Akt signaling pathway in regulating MC3T3-E1 preosteoblast proliferation and differentiation on SLA and SLActive titanium surfaces. *J Biomed Mater Res A*. 2013 Mar;101(3):748–54.
- Goldman M, Juodzbalys G, Vilkinis V. Titanium Surfaces with Nanostructures Influence on Osteoblasts Proliferation: a Systematic Review. *J Oral Maxillofac Res*. 2014;5(3):e1.
- Gottlow J, Dard M, Kjellson F, Obrecht M, Sennerby L. Evaluation of a new titanium-zirconium dental implant; a biomechanical et histological comparative study in the mini pig. *Clin Implant Dent Relat Res* 2012;14:538–545.
- Grandin H, Berner S, Dard M. A review of titanium zirconium (TiZr) alloys for use in endosseous dental implants. *Materials*, 2012, 5: 1348–1360.
- Heberer S, Kilic S, Hossamo J, Raguse JD, Nelson K.: Rehabilitation of irradiated patients with modified and conventional sandblasted acid-etched implants: preliminary results of a split-mouth study. *Clin Oral Implants Res*. 2011 May;22(5):546–51.
- Hotchkiss K., Reddy G., Hyzy S., Schwartz Z., Boyan B., Olivares-Navarrete R. Titanium surface characteristics, including topography and wettability, alter macrophage activation. *Acta Biomater* 2016;31:425–34
- Hotchkiss KM, Reddy GB, Hyzy SL, Schwartz Z, Boyan BD, Olivares-Navarrete R. Titanium surface characteristics, including topography and wettability, alter macrophage activation. *Acta Biomater*. 2016;31(Supplement C):425–34
- Hotchkiss KM, Ayad NB, Hyzy SL, Boyan BD, Olivares-Navarrete R. Dental implant surface chemistry and energy alter macrophage activation in vitro. *Clin Oral Implants Res*. 2017;28(4):414–23.
- Jimbo R, Naito Y, Galli S, Berner S, Dard M, Wennerberg A. Biomechanical and Histomorphometrical Evaluation of TiZr Alloy Implants: An in vivo Study in the Rabbit. *Clin Implant Dent Relat Res*. 2015;17(S2):e670–8.
- Kopf BS, Ruch S, Berner S, Spencer ND, Maniura-Weber K. The role of nanostructures and hydrophilicity in osseointegration: In-vitro protein-adsorption and blood-interaction studies. *J Biomed Mater Res Part A*. 2015;103(8):2661–72.
- Kopf BS, Schipanski A, Rottmar M, Berner S, Maniura-Weber K. Enhanced differentiation of human osteoblasts on Ti surfaces pre-treated with human whole blood. *Acta Biomater*. 2015;19:180–90.
- Lang NP, Salvi GE, Huynh-Ba G, Ivanovski S, Donos N, Bosshardt DD. Early osseointegration to hydrophilic and hydrophobic implant surfaces in humans. *Clin Oral Implants Res*. 2011 Apr;22(4):349–56.
- Lee R, Hamlet SM, Ivanovski S. The influence of titanium surface characteristics on macrophage phenotype polarization during osseous healing in type I diabetic rats: A pilot study. *Clin Oral Impl Res* (accepted 4/8/2016).
- Lindgren C, Mordenfeld A, Hallman M.: A prospective 1-year clinical and radiographic study of implants placed after maxillary sinus floor augmentation with synthetic biphasic calcium phosphate or deproteinized bovine bone. *Clin Implant Dent Relat Res*. 2012 Mar;14(1):41–50.
- Lotz EM, Olivares-Navarrete R, Hyzy SL, Berner S, Schwartz Z, Boyan BD. Comparable responses of osteoblast lineage cells to microstructured hydrophilic titanium-zirconium and microstructured hydrophilic titanium. *Clin Oral Implants Res*. 2017;28(7):e51–9
- Lotz EM, Olivares-Navarrete R, Berner S, Boyan BD, Schwartz Z. Osteogenic response of human MSCs and osteoblasts to hydrophilic and hydrophobic nanostructured titanium implant surfaces. *J Biomed Mater Res Part A*. 2016;104(12):3137–48.
- Matthias J. Frank, Martin S. Walter, S. Petter Lyngstadaas, Erich Wintermantel, Håvard J. Haugen. Hydrogen content in titanium and a titanium-zirconium alloy after acid etching. *Materials Science and Engineering: C Volume 33, Issue 3, 1 April 2013, Pages 1282–1288.*

- Mazaheri M, Eslahi N, Ordikhani F, Tamjid E, Simchi A. Nanomedicine applications in orthopedic medicine: state of the art. *Int J Nanomedicine*. 2015;10:6039–54.
- McMahon RE, Wang L, Skoracki R, Mathur AB. Development of nanomaterials for bone repair and regeneration. *J Biomed Mater Res Part B Appl Biomater*. 2013;101B(2):387–97.
- Medvedev A, Molotnikov A, Rimma Lapovok, Rolf Zeller, Simon Berner, Philippe Habersetzer, Florian Dalla Torre. Microstructure and mechanical properties of Ti–15Zr alloy used as dental implant material. *Journal of the Mechanical Behavior of Biomedical Materials*, September 2016, Pages 384–398.
- Murphy M, Walczak MS, Thomas AG, Silikas N, Berner S, Lindsay R. Toward optimizing dental implant performance: Surface characterization of Ti and TiZr implant materials. *Dental Materials Volume 33, Issue 1, January 2017, Pages 43–53*
- McCracken M, Lemons JE, Rahemtulla F, Prince CW, Feldman D. Bone response to titanium alloy implants placed in diabetic rats. *Int J Oral Maxillofac Implants*. 2000 May-Jun;15(3):345–54.
- Mendonça G, Mendonça DBS, Aragão FJL, Cooper LF. Advancing dental implant surface technology – From micron- to nanotopography. *Biomaterials*. 2008;29(28):3822–35.
- Müller E, Rottmar M, Maniura K. Impact of RXD SLA, RXD, SLAnano, RXD SLActive, and RXD pmod SLA surfaces on protein adsorption, blood coagulation, and osteogenic differentiation of HBCs. 2017.
- Müller E, Rottmar M, Guimond S, Tobler U, Stephan M, Berner S, et al. The interplay of surface chemistry and (nano-)topography defines the osseointegrative potential of Roxolid® dental implant surfaces. In: *eCM Conferences Abstract Collection 3*. St. Gallen, Switzerland: *eCells & Materials*; 2017. p. 31
- Nack C, Raguse J-D, Stricker A, Nelson K, Nahles S. Rehabilitation of irradiated patients with chemically modified and conventional SLA implants: five-year follow-up. *Journal of Oral Rehabilitation* 2015;42:57–64.
- Naik K, Srivastava P, Deshmukh K, Monsoor MS, Kowshik M. Nanomaterial-Based Approaches for Prevention of Biofilm-Associated Infections on Medical Devices and Implants. *J Nanosci Nanotechnol*. 2015;15(12):10108–19
- Nicolau P, Korostoff J, Ganeles J, Jackowski J, Krafft T, Neves M, Divi J, Rasse M, Guerra F, Fischer K.: Immediate and Early Loading of Chemically Modified Implants in Posterior Jaws: 3-Year Results from a Prospective Randomized Multicenter Study. *Clin Implant Dent Relat Res*. 2013 Aug;15(4):600–612.
- Nelson K.: Rehabilitation of irradiated patients with modified and conventional sandblasted acid-etched implants: preliminary results of a split-mouth study. *Clin Oral Implants Res*. 2011 May;22(5):546–51.
- Nevins ML, Karimbux NY, Weber HP, Giannobile WV, Fiorellini JP. Wound healing around endosseous implants in experimental diabetes. *Int J Oral Maxillofac Implants*. 1998 Sep-Oct;13(5):62–9.
- Oates TW, Valderrama P, Bischof M, Nedir R, Jones A, Simpson J, Toutenburg H, Cochran DL: Enhanced implant stability with a chemically modified SLA surface: a randomized pilot study. *Int J Oral Maxillofac Implants*. 2007 Sep-Oct;22(5):755–60.
- Pachauri P, Bathala LR, Sangur R. Techniques for dental implant nanosurface modifications. *J Adv Prosthodont*. 2014;6(6):498–504.
- Ramos AP, Cruz MAE, Tovani CB, Ciancaglini P. Biomedical applications of nanotechnology. *Biophys Rev*. 2017;9(2):79–89.
- Rocuzzo M, Wilson TG Jr.: A prospective study of 3 weeks' loading of chemically modified titanium implants in the maxillary molar region: 1-year results. *Int J Oral Maxillofac Implants*. 2009 Jan-Feb;24(1):65–72.
- Rupp F, Liang L, Geis-Gerstorf J, Scheideler L, Hüttig F. Surface characteristics of dental implants: A review. *Dent Mater*. 2018 Jan;34(1):40–57. doi: 10.1016/j.dental.2017.09.007. Epub 2017 Oct 10. Review
- Salou L, Hoornaert A, Louarn G, Layrolle P. Enhanced osseointegration of titanium implants with nanostructured surfaces: An experimental study in rabbits. *Acta Biomater*. 2015;11(Supplement C):494–502.
- Saiz E, Zimmermann EA, Lee JS, Wegst UGK, Tomsia AP. Perspectives on the Role of Nanotechnology in Bone Tissue Engineering. *Dent Mater*. 2013;29(1):103–15.
- Salmasi S, Kalaskar DM, Yoon W-W, Blunn GW, Seifalian AM. Role of nanotopography in the development of tissue engineered 3D organs and tissues using mesenchymal stem cells. *World J Stem Cells*. 2015;7(2):266–80.
- Slotte Christer et al, Four-mm implants supporting fixed partial dentures in the posterior mandible. 5-year results from a multicenter study. Presented at the 20th Annual Scientific Meeting of the European Association of Osseointegration, 10-13 October 2012, Copenhagen, Denmark.
- Schwarz F, Ferrari D, Herten M, Mihatovic I, Wieland M, Sager M, Becker J.: Effects of surface hydrophilicity and microtopography on early stages of soft and hard tissue integration at non-submerged titanium implants: an immunohistochemical study in dogs. *J Periodontol*. 2007 Nov;78(11):2171–84.
- Schwarz F, Herten M, Sager M, Wieland M, Dard M, Becker J. Histological and immunohistochemical analysis of initial and early osseous integration at chemically modified and conventional SLA® titanium implants: Preliminary results of a pilot study in dogs. *Clinical Oral Implants Research*, 11(4): 481–488, 2007
- Schlegel KA, Prechtl C, Möst T, Seidl C, Lutz R, von Wilmsky C. *Clin Oral Implants Res*. 2013 Feb;24 (2):128–34.
- Schaffner P, Dard M. Structure and function of RGD peptides involved in bone biology. *Cell Mol Life Sci*, 2003;60:119–132.
- Stoker GT, Wismeijer D: Immediate loading of two implants with a mandibular implant-retained overdenture: a new treatment protocol. *Clin Implant Dent Relat Res*. 2011 Dec;13(4):255–61.
- Steinemann S. Titanium - the material of choice ? *Periodontol* 2000, 1998.
- Straumann (2017) Developed area ratio by nanostructures on Rxd modMA surface. Report SR0748. Unpublished data.
- Streicher RM, Schmidt M, Fiorito S. Nanosurfaces and nanostructures for artificial orthopedic implants. *Nanomedicine*. 2007;2(6):861–74.
- Takeshita, F et al. *Journal of Periodontology* 68: 180–185.
- Variola F, Brunski J, Orsini G, Oliveira PT De, Nanci A. Nanoscale surface modifications of medically-relevant metals: state-of-the-art and perspectives. *Nanoscale*. 2011;3(2):335–53
- Van Assche N, Michels S, Naert I, Quirynen M.: Randomized Controlled Trial to Compare Two Bone Substitutes in the Treatment of Bony Deficiency. *Clin Implant Dent Relat Res*. 2013 Aug;15(4):558–568
- Wagner R, Berner S. Report SR0748: Developed are ratio by nanostructures on RXD modMA surface. 2017. Unpublished data.
- Wen B, Zhu F, Li Z, Zhang P, Lin X, Dard M. The osseointegration behavior of titanium/zirconium implants in ovariectomized rabbits. *Clin Oral Implant Res*. 2014;25:819–825.
- Wennerberg A, Albrektsson T. On implant surfaces: a review of current knowledge and opinions. *Int J Oral maxillofac Implants* 2009; 24:63–74
- Wennerberg A, Jimbo R, Stübinger S, Obrecht M, Dard M, Berner S. Nanostructures and hydrophilicity influence osseointegration: a biomechanical study in the rabbit tibia. *Clin Oral Implants Res*. 2014;25(9):1041–50.
- Wennerberg A, Svanborg LM, Berner S, Andersson M. Spontaneously formed nanostructures on titanium surfaces. *Clin Oral Implants Res*. 2013 Feb;24(2):203–9.
- Wennerberg A, Galli S, Albrektsson T. Current knowledge about the hydrophilic and nanostructured SLActive surface. *Clin Cosmet Investig Dent*. 2011;3:59–67.
- Zhao G, Raines AL, Wieland M, Schwartz Z, Boyan BD. Requirement for both micron- and submicron scale structure for synergistic responses of osteoblasts to substrate surface energy and topography. *Biomaterials*. 2007;28(18):2821–9.
- Zhao G et al. 2005; *J Biomed Mater Res A* 74(1):49–58. *J Biomed Mater Res A*. 2013 Mar;101(3):748–54. doi: 10.1002/jbm.a.34377. Epub 2012 Aug 31.

# At the heart of the image

## Mastering the emergence profile

*For every issue our editors screen the most popular social networks and select their favorite dental picture. In this short article the photographer explains his photographic set-up and describes the treatment procedure step-by-step.*

Management of the peri-implant soft tissue contours is a critical component of esthetic implant therapy. In patients with high esthetic demands, minimally invasive surgical techniques and prosthetic soft tissue development are essential in achieving a seamless, naturally appearing implant supported restoration. In cases where pre-formed restorative counter parts are utilized, prosthetic tissue conditioning and accurate translation of the restorative contours to the final restoration are essential in transitioning the patient from the surgical to the restorative phase while maintaining the peri-implant tissue volume and architecture.



### SHERIF SAID

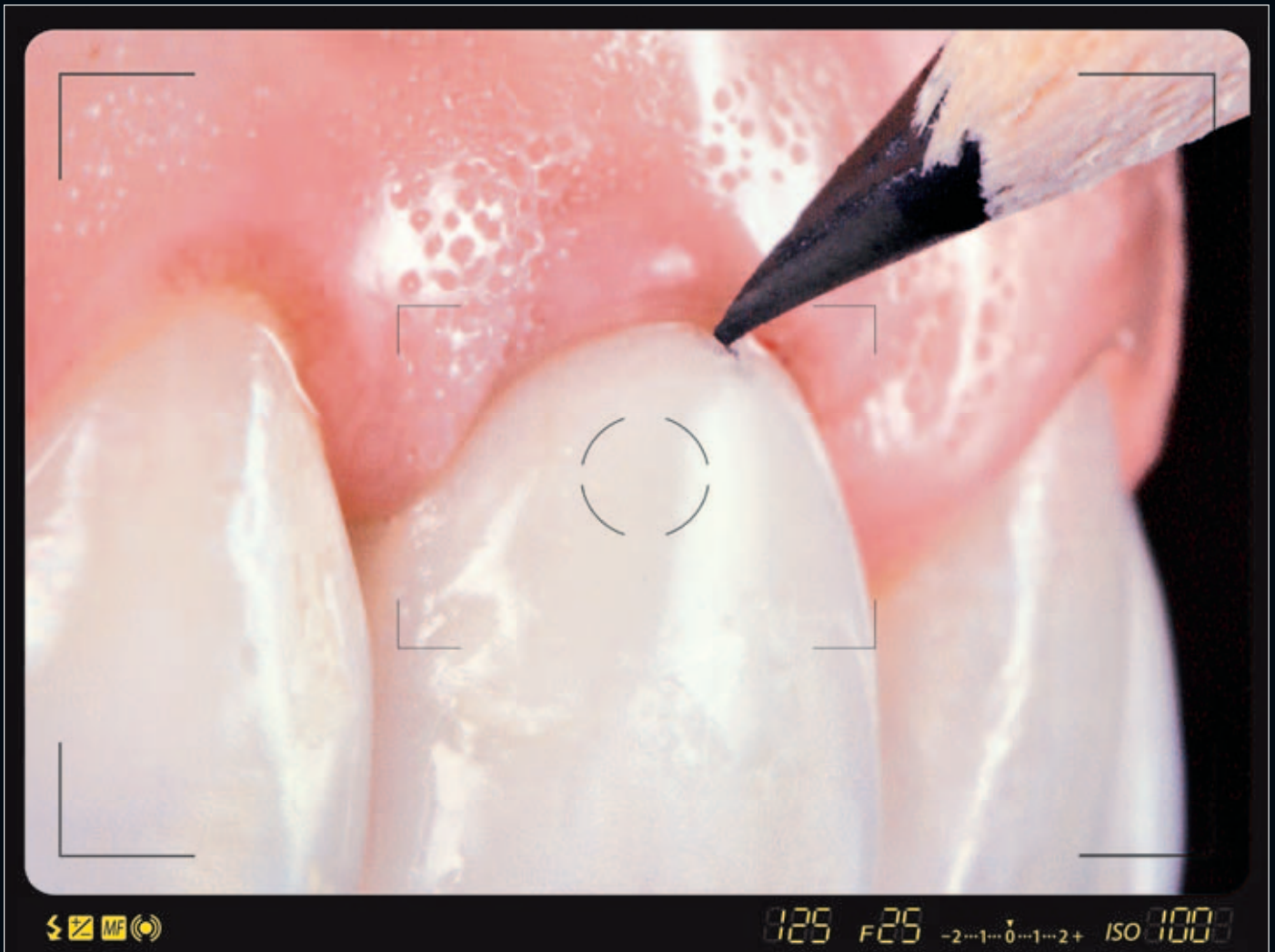Periodontist.  
Assistant Clinical Professor, Boston University.  
Private Practice, Toronto, Canada.  
Periodontal Prosthesis Clinic, Cairo, Egypt.  
[sherif\\_said@hotmail.com](mailto:sherif_said@hotmail.com)

Prosthetics by:  
Dr. Hideo Yamamoto, Dr. Chung Yu  
and Dr. Daniela Rubiano



Canon EOS Rebel T6i  
Exposure : 1/125 s à f/25, ISO 100

Focal distance : 100 mm  
Lens : 100 mm f/2.8L Macro



## Step-by-step protocol

This case report highlights the steps of managing a previously failed implant site with combined minimally invasive hard and soft tissue augmentation followed by the prosthetic sequence for development of the soft tissue architecture.

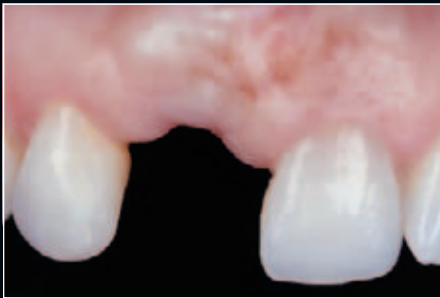

Fig. 1 Pre-operative condition following implant failure in site of a maxillary right central incisor.

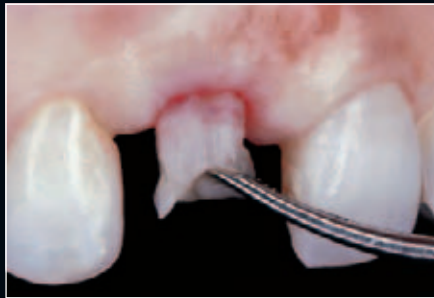

Fig. 2 A tissue punch is performed to allow for sufficient room for implant and tissue manipulation based on the anticipated implant position. In this case the tissue is not discarded as it will be used for future soft tissue development later in the procedure. The tissue punch is removed from the base with a periosteal elevator. Note the whitish color of the tissue indicative of the dense collagenous nature owing to the minimal amounts of adipose and glandular content.

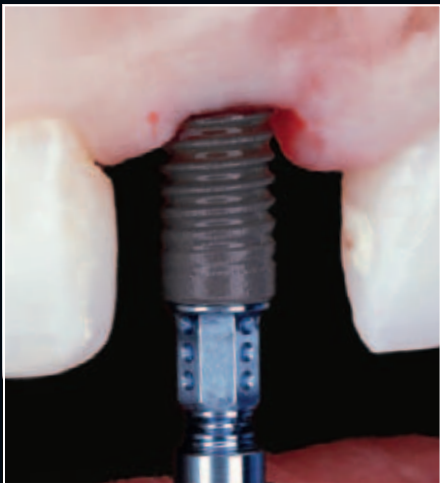

Fig. 3 Implant placement is performed utilizing a SLactive Straumann bone level tapered 4.1x12mm with insertion torque value of >40Ncm.

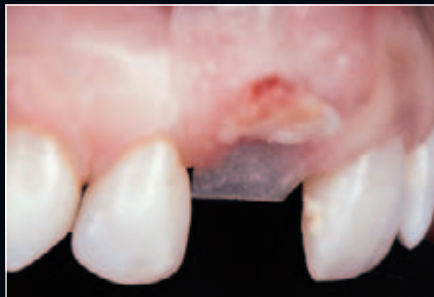

Fig. 4 Full thickness tunnel preparation is performed using tunneling instruments to allow for adequate room for membrane insertion. A Cross-linked collagen membrane is placed onto the buccal aspect of the implant and adjusted to extend 2-3mm circumferentially around the buccal peri-implant osseous defect. The previously utilized tissue punch is dissected and used to augment the volume of the supra-implant soft tissue.

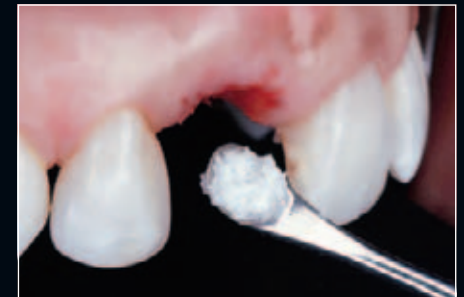

Fig. 5 A Growth factor enhanced bone matrix is introduced to the level of the implant platform to reconstitute the lost buccal bone topography.

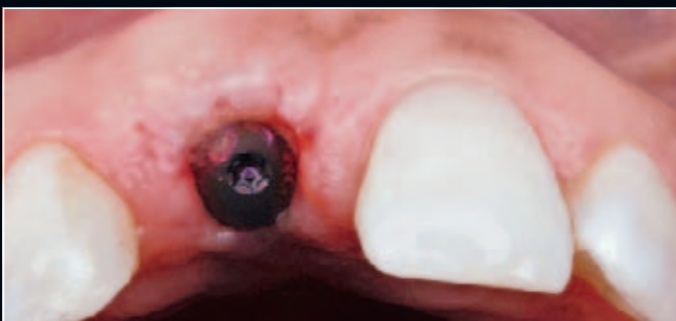

Fig. 6 A soft tissue graft is then inserted coronal to the implant and secured in place with a pre-fabricated healing abutment.

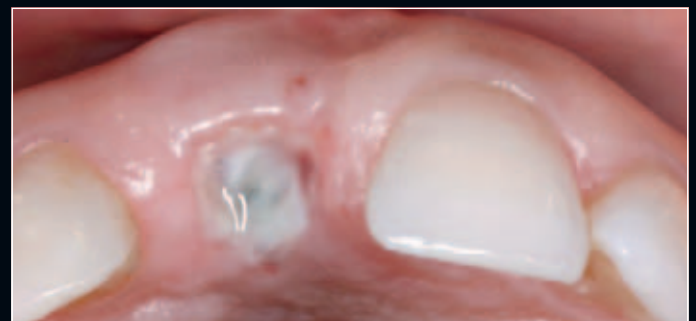

Fig. 7 5 days post-operative view of the surgical site.

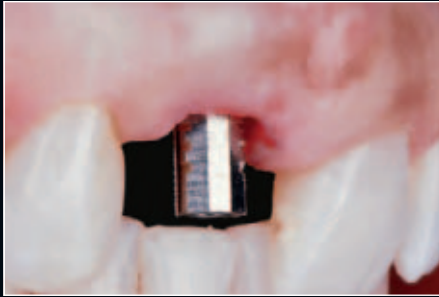


Fig. 8 Following implant integration, try-in of a provisional temporary abutment is performed and adjusted.

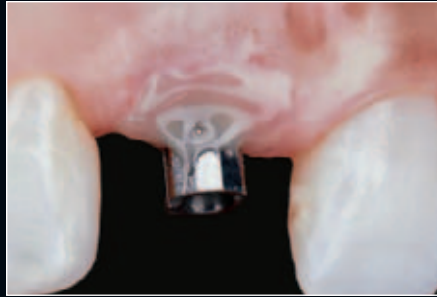


Fig. 9 Flowable composite is used to outline the anticipated emergence of the future restoration at the gingival interface.

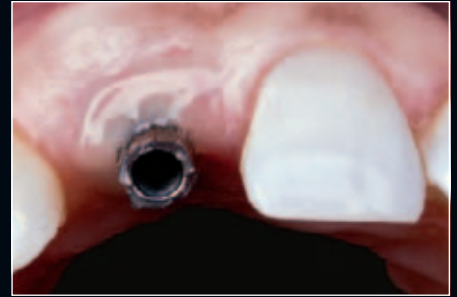


Fig. 10 The composite is adjusted to mimic the emergence of the implant restoration at the gingival margin levels.

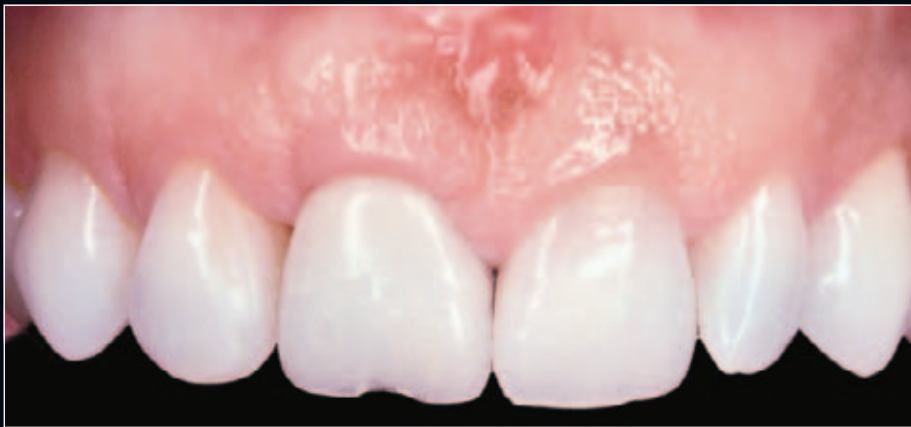

Fig. 11 Following tissue maturation, fine tuning of the provisional restoration is performed to have a symmetrical length and gingival zenith for both central incisors. Note the gingival margin level discrepancy between the 2 central incisors.

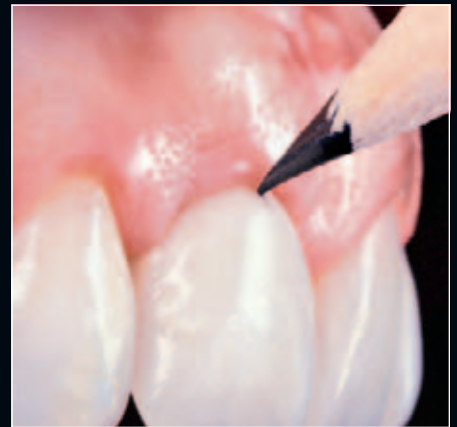

Fig. 12 The Gingival Zenith is outlined to allow for extra-oral adjustments to be performed.

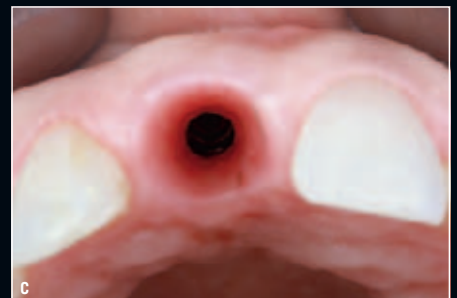
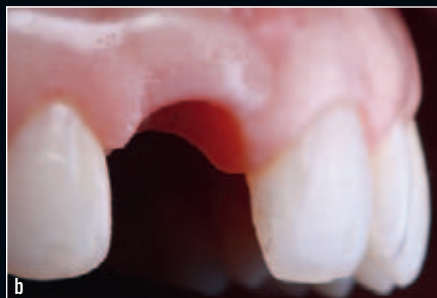
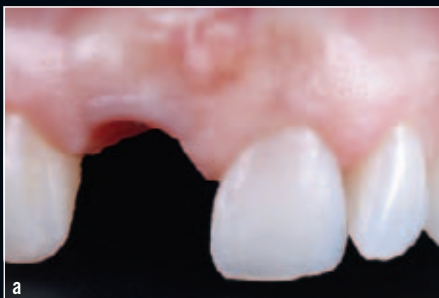Fig. 13 a to c Clinical view of the tissue contours following initial provisionalization.

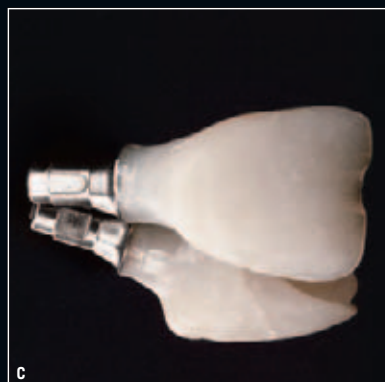


Fig. 14 a to c Extra-oral Adjustments to the provisional restoration are made based on the predetermined gingival zenith adjustments. Flowable composite is added at the gingival contours to apically displace the gingival margin at the area desired. Subgingival contours of the provisional restoration are left straight or under-contoured to avoid tissue compression and allow space for adequate space for maintenance of the peri-implant soft tissue thickness.



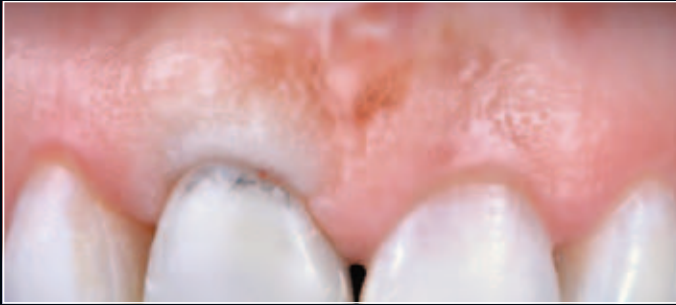


Fig. 15 Immediately post insertion of the modified provisional restoration showing blanching of the tissue due to the temporary indicating ischemia caused by the new provisional contours.

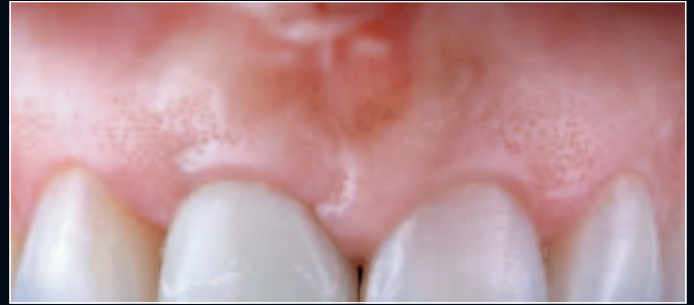

Fig. 16 One week following tissue healing with the modified provisional contours.



Fig. 17 a and b For accurate replication of the sub gingival contours of the final abutment, the implant analogue is fixated using a stone base and an impression of the subgingival contours of the crown will be made to be transferred to create a custom impression coping.




Fig. 18 Grooves are made into the set material to facilitate mechanical interlocking of the impression material.




Fig. 19 (a) A light body PVS material is injected around the provisional restoration to capture the sub gingival contours. (b) The Impression Coping is placed in place of the provisional. (c) Flowable Composite is then injected in the space previously occupied with the provisional restoration to duplicate the emergence profile of the restoration to the lab for custom abutment fabrication.

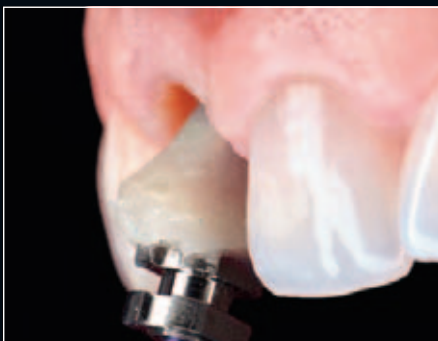
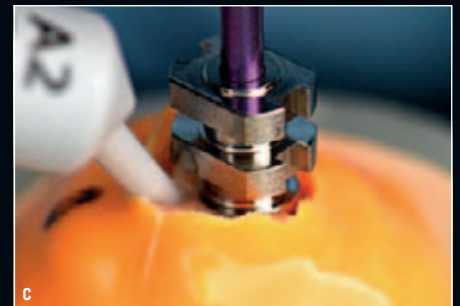
Fig. 20 Prior to seating of the customized impression coping, note the concave subgingival contour mimicking that of the provisional abutment.

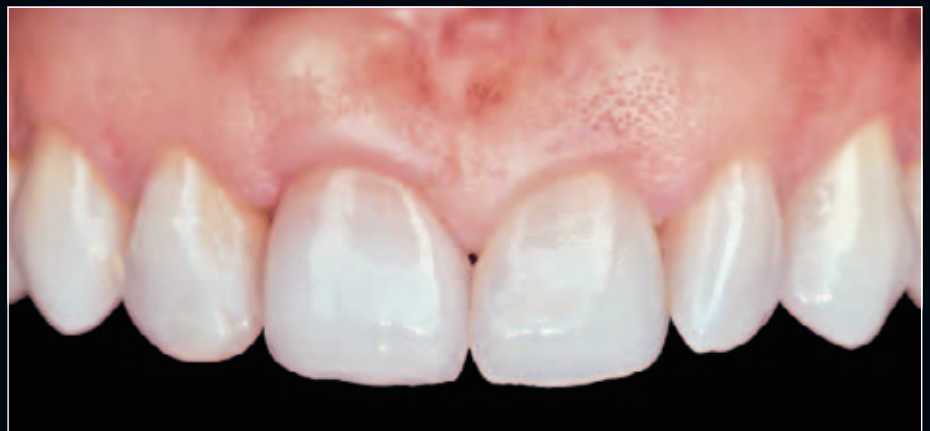

Fig. 21 Post-operative result. Maturation of the tissue is evident and the gingival architecture is an exact copy of what was designed with the provisional.

QUINTESSENCE is published by  
**QUINTESSENCE INTERNATIONAL**  
 62 boulevard de la Tour Maubourg  
 75007 Paris  
 Tél. (+33)1 83 97 97 97  
 infos@quintessence-international.fr  
 www.quintessence-international.fr  
 Court domicile and place  
 of performance: Paris, France.

**PUBLISHERS**

Dr Karim Dada and Dr Léon Parienté

**DIRECTOR OF JOURNAL PUBLICATIONS**

Dr Karim Dada  
 dada@quintes.fr

**EDITORIAL COORDINATOR**

Marie Salier  
 salier@quintes.fr

**PRODUCTION MANAGER**

Laurent Guillaume

**SALES MANAGER**

Irène Martins  
 martins@quintes.fr

**PRINTED IN FRANCE**

Escourbiac, 81304 Graulhet

Tous les papiers  
 ont droit à plusieurs vies.



Copyright © 2019 by Quintessence International. All rights reserved. No parts of this journal may be reproduced or transmitted in any form or by any means, electronic or mechanical, including photocopying, recording, or any information and retrieval system without permission in writing from the publisher. The publisher assumes no responsibility for unsolicited manuscripts. All opinions are those of the authors.

Information included herein is not professional advice and is not intended to replace the judgment of a practitioner with respect to particular patients, procedures or practices. To the extent permissible under applicable laws, the publisher disclaims responsibility for any injury and/or damage to persons or property other proprietary or privacy rights, or from operations any ideas, instructions, procedures, products or methods contained in the material herein. Permission to photocopy items solely for personal use.



Acknowledges the contributions of the following  
**Advanced Education Centers**  
 to this special issue dedicated to Straumann BLX implant

Paris (France): Dr Dada, Dr Pariente, Dr Daas  
 Mendrisio (Switzerland): Dr Perucchi, Dr Monti  
 Verona (Italy): Dr Piano  
 Cape Town (South Africa): Dr Swart, Dr Van Zyl

EXCELLENCE IN IMMEDIACY

Straumann® SLActive®

Performance beyond  
imagination.



Contact your local Straumann representative  
or visit: [www.straumann.com](http://www.straumann.com)

 **straumann**

Straumann® BLX

