

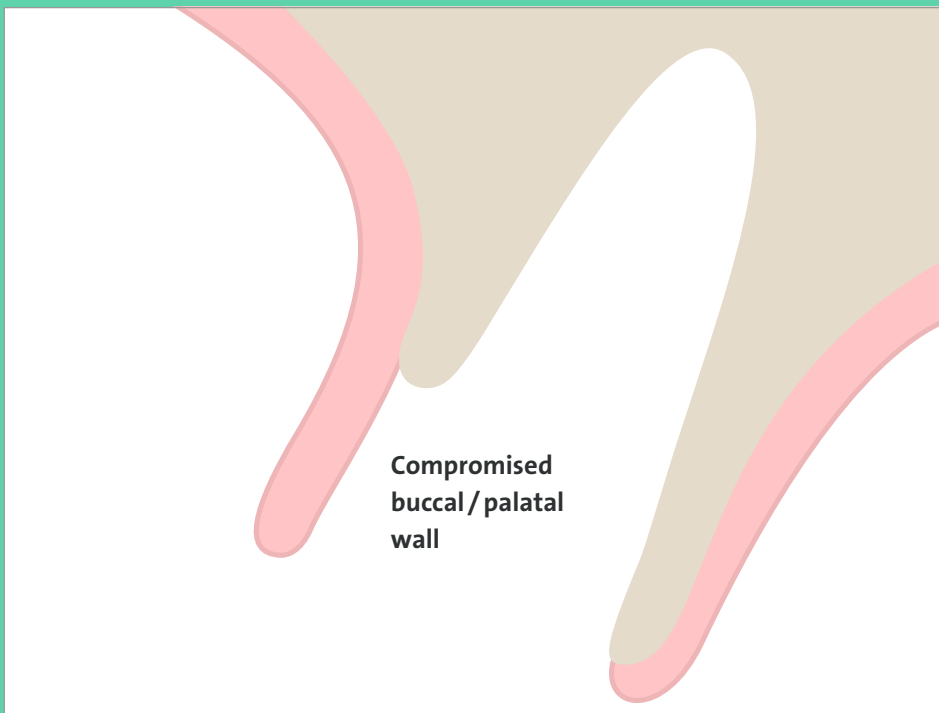
NOVAMAG[®] SHIELD TECHNIQUE

NOVAMag[®]
membrane

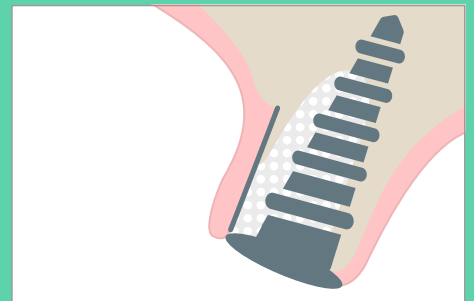
10 × 20 mm

Unique approach for buccal wall defects.

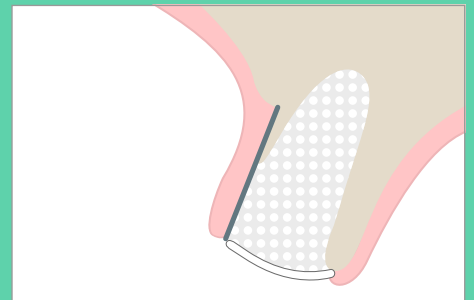
EASY HANDLING 3D MECHANICAL STABILITY



IMMEDIATE IMPLANTATION



RIDGE PRESERVATION

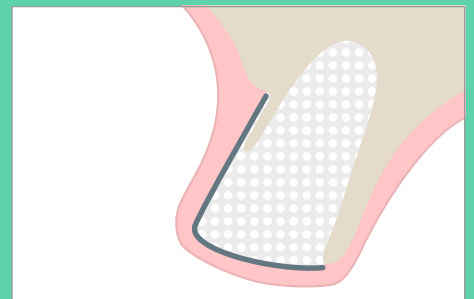


EASY APPLICATION

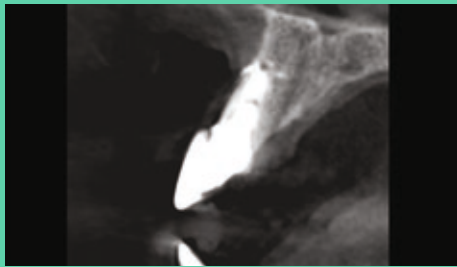
- Place the NOVAMag[®] membrane between the bone and periosteum (soft tissue)

PREDICTABLE OUTCOME

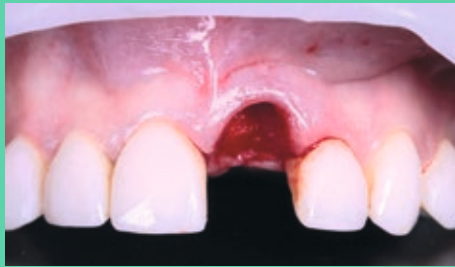- Supports new bone growth
- Magnesium shield maintains ridge contour



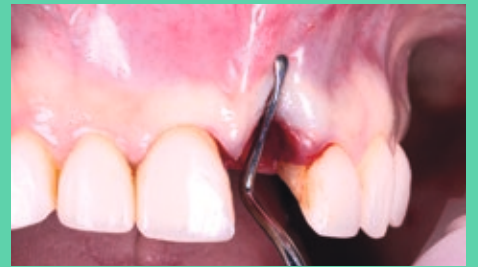IMMEDIATE IMPLANT PLACEMENT IN ANTERIOR MAXILLA | DR. ERICK MOTA (DOM)



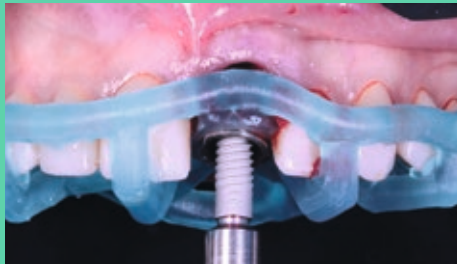X-ray of initial situation: missing buccal wall



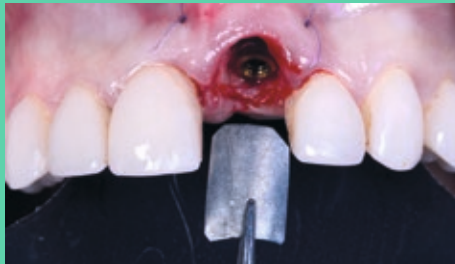Atraumatic tooth extraction



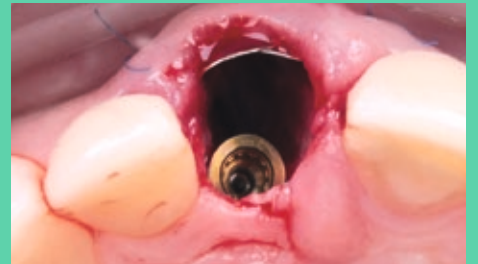Buccal wall defect



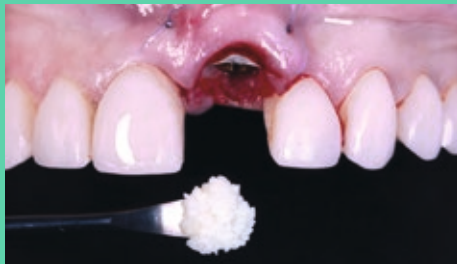Guided implant placement



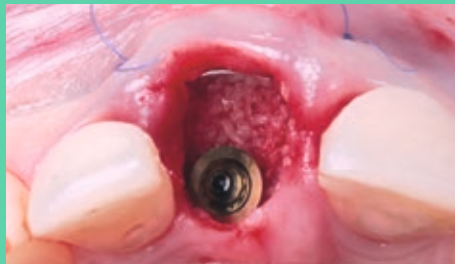Adaptation of NOVAMag[®] membrane



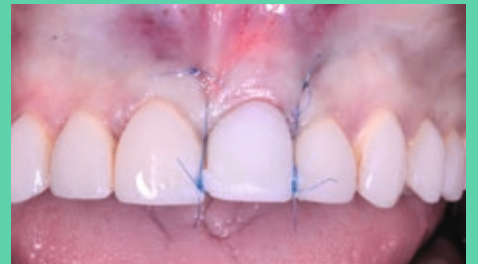Placement under periosteum



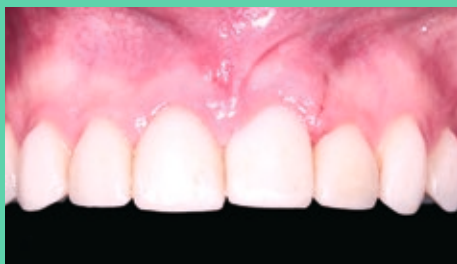Bone grafting



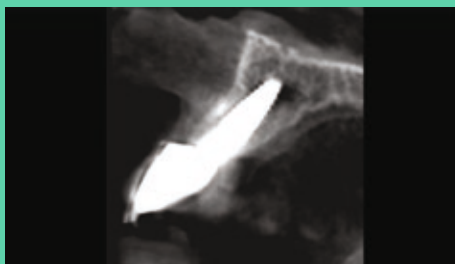Filled defect



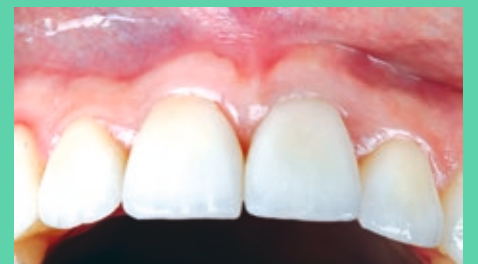Site closure by non-resorbable sutures



Suture removal



X-ray of stable buccal bone wall (3 months post-op)



Final situation: 3 months post-op

RESORBABLE MAGNESIUM METAL MEMBRANE

