

STRAUMANN®
SmileAward



SUPPORTED BY
ZeroDonto

Straumann® Smile Award 2021

Short guideline for photographic documentation

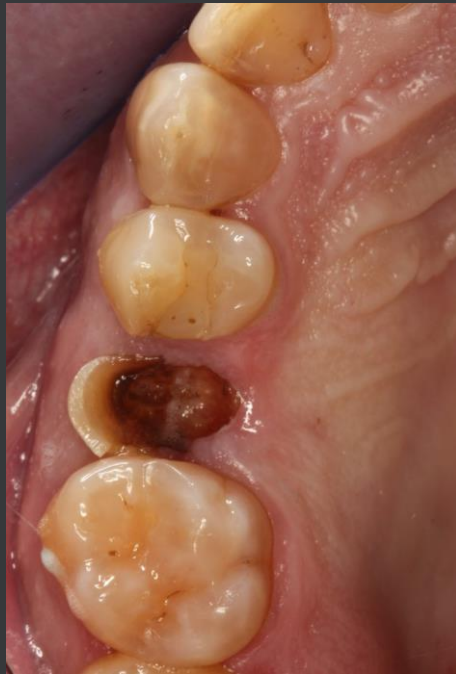Clinical case:

Courtesy Dr Juan Blanco Carrion, Spain

Initial situation: Clinical and radiographic aspects

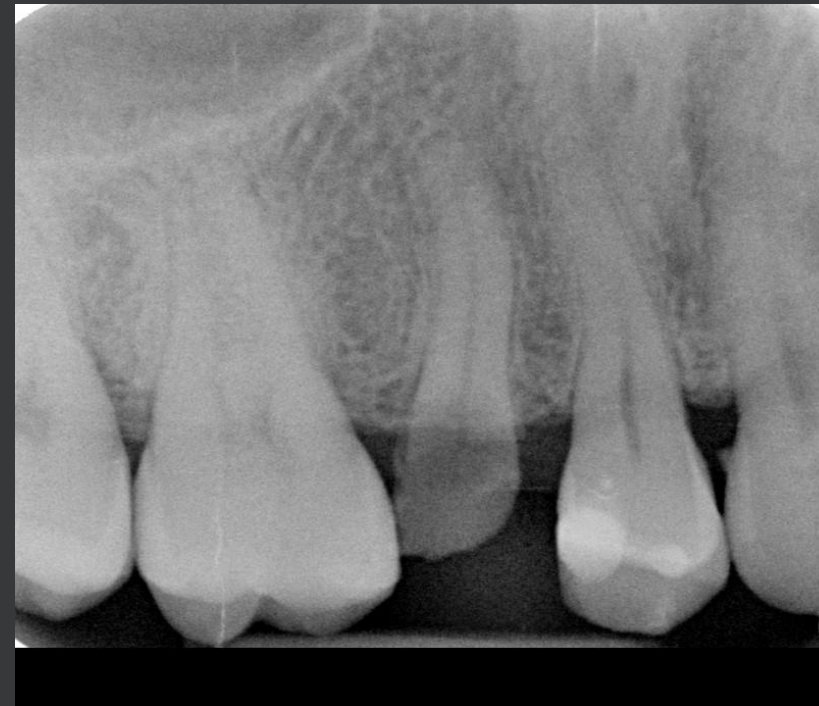Clinical

- One photo occlusal and one photo lateral
- One photo full smile (facial aspect) depending on the case (masked eyes)



Radiographic

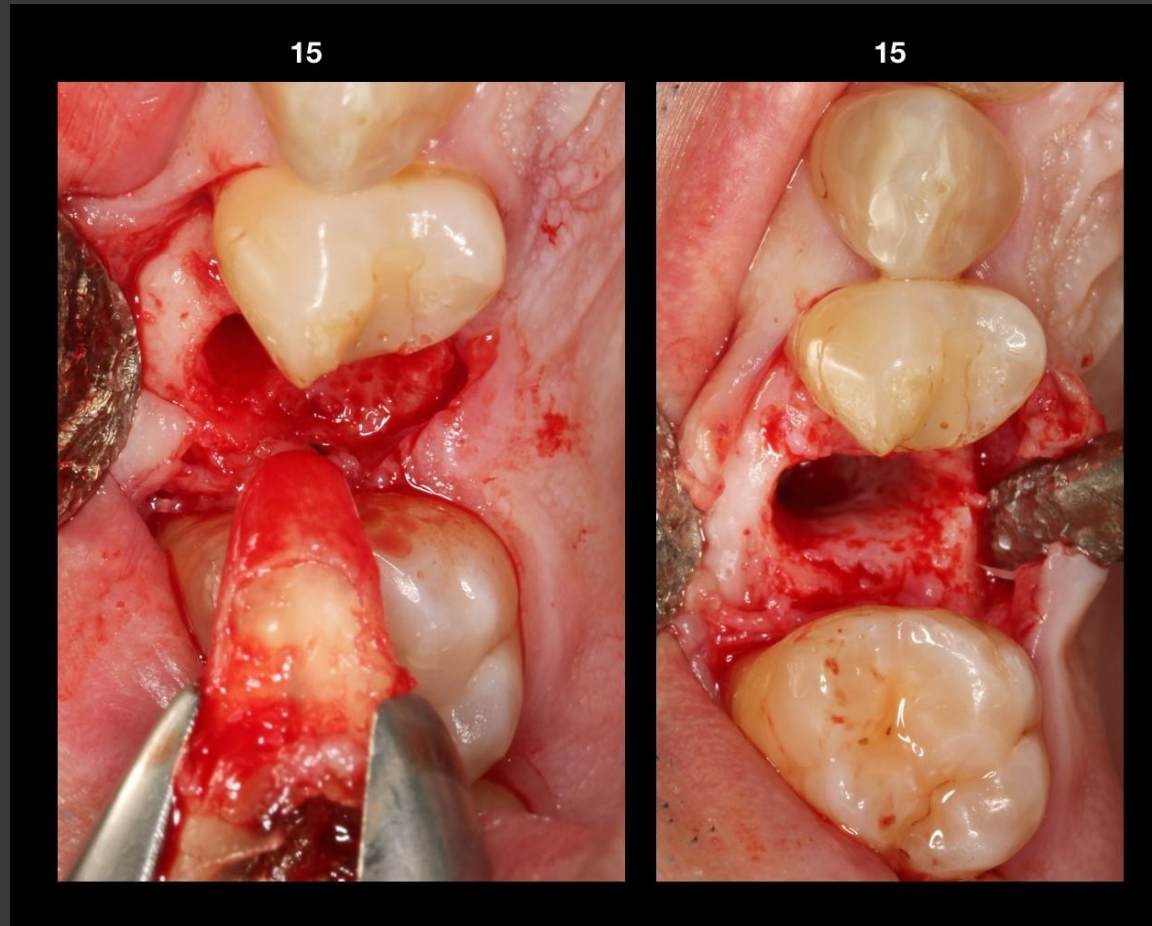
- Periapical X-rays or one OPG or both depending on the clinical situation



Extractions: Clinical aspects

Single tooth extraction

- Atraumatic procedure (one photo)
- Final view of bony situation (one photo)



Multiple or full mouth extractions

- Procedure (one or two photo(s))
- Final view of bony situation (one or two photo(s))

Implant(s) and abutment(s) specifications

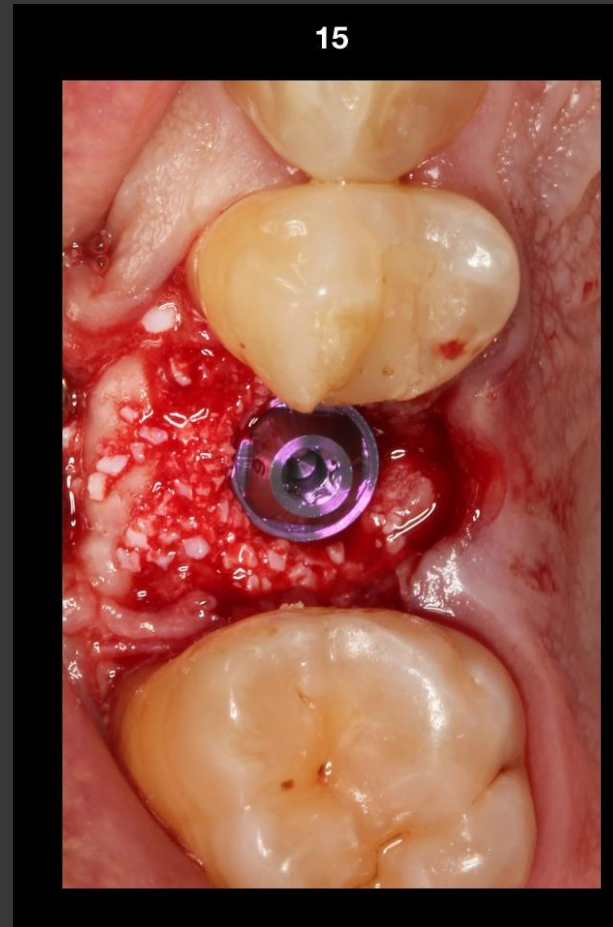
(photos not necessary)

- ▶ Implant type(s) and name(s)
- ▶ Implant(s) length
- ▶ Implant(s) diameter
- ▶ Abutment(s) type(s) and name(s)
- ▶ Abutment(s) height(s)

Implant(s) final placement

Implant(s) position in bone

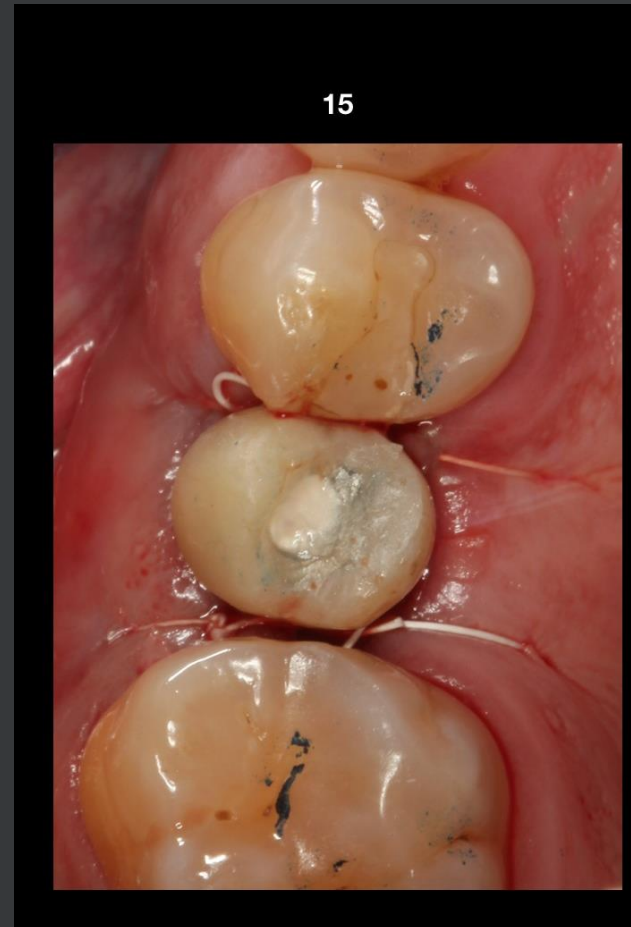- Only before suturing
- One photo



Provisional restoration(s)

Time after implantation: ...

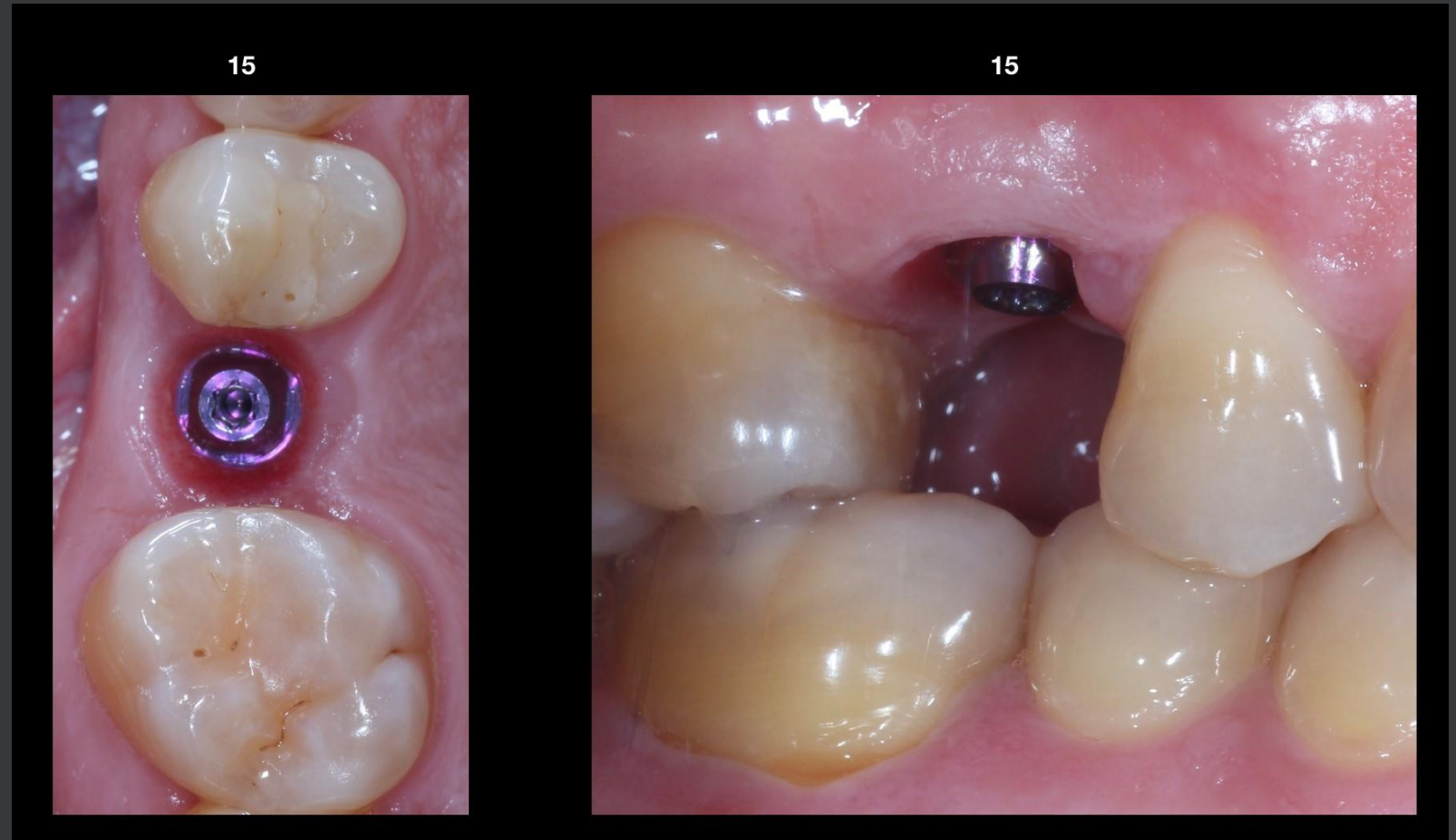- Photo(s):
Occlusal or lateral or both



Clinical situation at final restoration placement

Occlusal and lateral views:

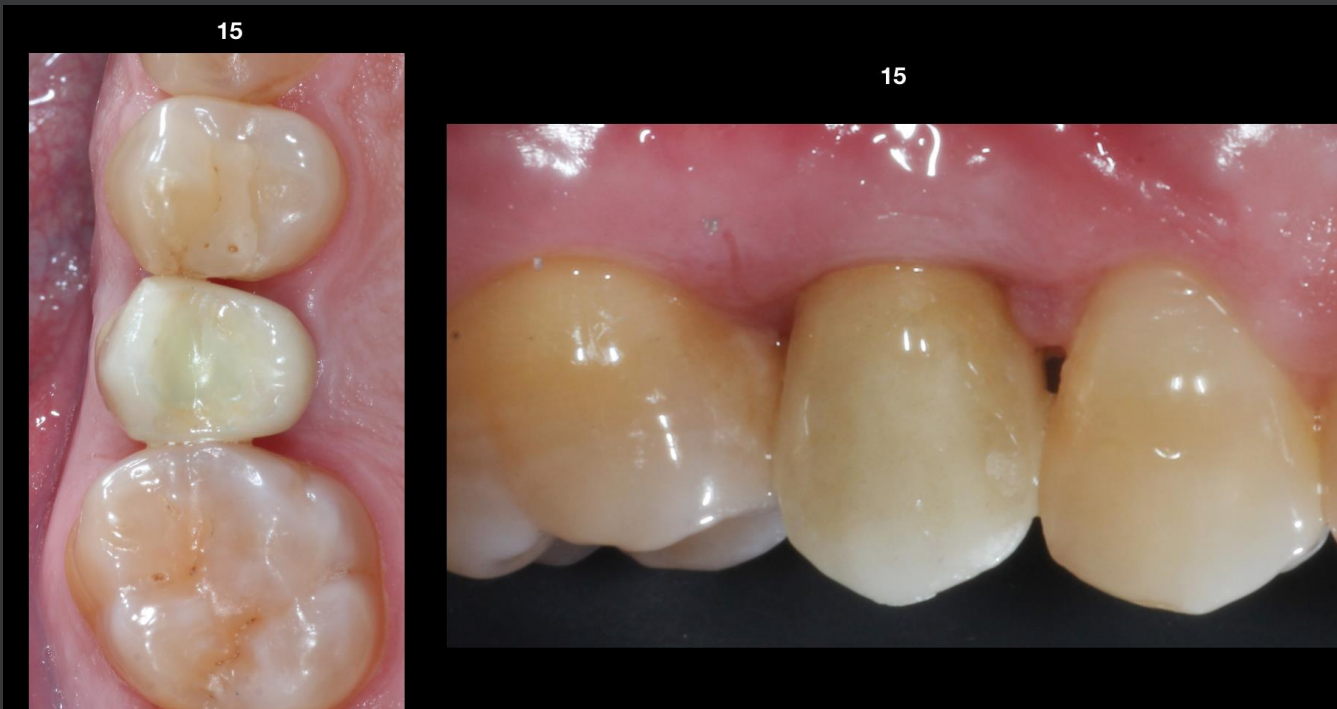- One photo each



Final result: Clinical and radiographic aspects

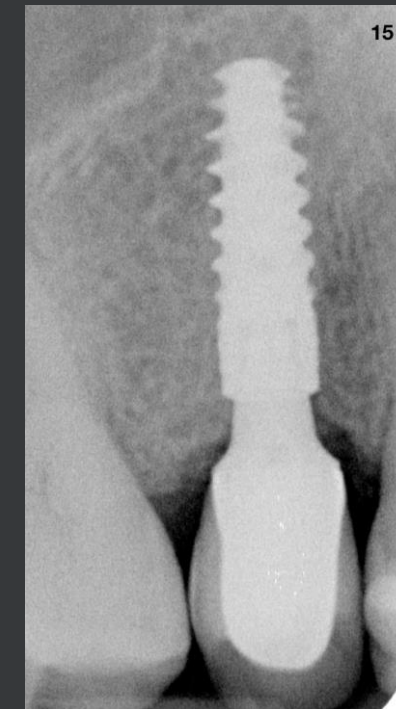
Clinical

- One photo occlusal and one photo lateral
- One photo full smile (facial aspect) depending on the case (with masked eyes)



Radiographic

- Periapical X-rays or one OPG or both depending on the clinical situation



STRAUMANN®
SmileAward



Thank you
for your kind participation