

More than pure esthetics. The natural and strong solution.

Case report: Straumann® PURE Ceramic Implant Jordi Gargallo-Albiol

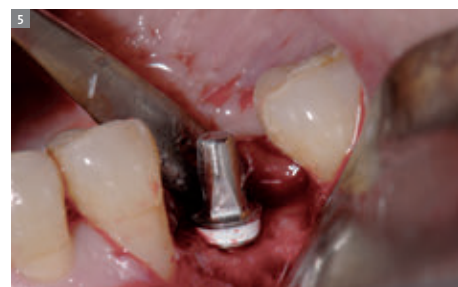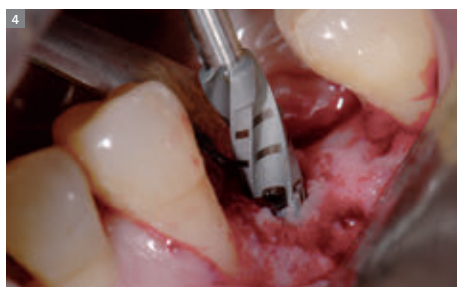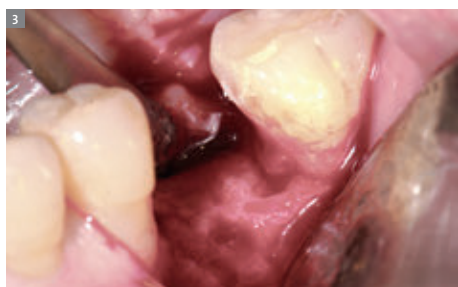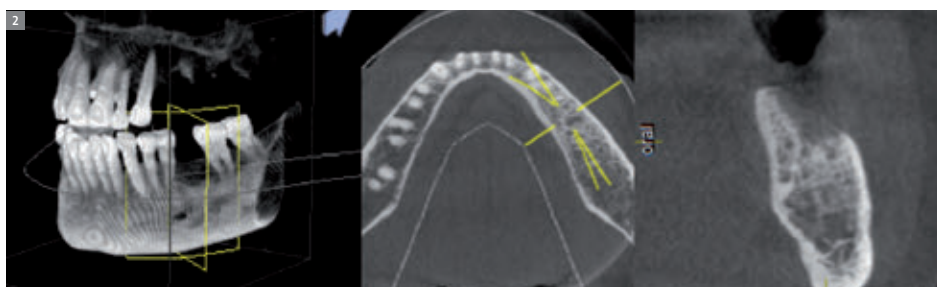
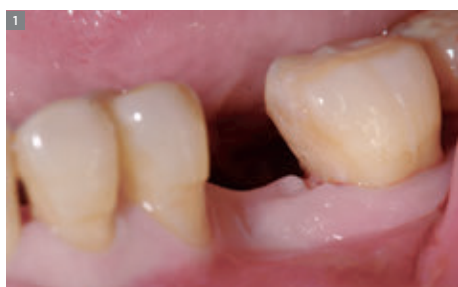« The new Straumann® PURE Ceramic Implant breaks new ground in the world of implant dentistry. It is an ideal solution for patients who request a metal-free solution, providing excellent esthetics and the meeting higher levels of expectation, even in patients with thin gingival contours or who are prone to gingival recession. The proven Straumann quality behind the implant makes it the patient's choice when it comes to a fully ceramic solution. Jordi Gargallo-Albiol »

INITIAL SITUATION

The patient – 73 years old, female – had lost tooth #35 several months ago due to a periodontitis (Fig. 1). Her medical history was characterized by controlled periodontal disease with a clear generalized gingival recession and a thin periodontal biotype. After clinical and radiological examination (panoramic X-ray and CBCT, Fig. 2), a decision was made in favor of a Straumann® PURE Ceramic Implant (10 mm, Ø 4.1 mm).

SURGICAL PROCEDURE

An envelope flap with a crestal incision was made in the middle of the alveolar ridge, with a marginal incision around the neighboring teeth in order to sufficiently reveal the alveolar site and to expose the crestal bone (Fig. 3). Drilling was performed according to the usual Straumann® Bone Level protocol (Fig. 4). After the 2.8 mm and 3.5 mm drills, a position indicator was used to determine implant direction and pillar height and en-



sure proper implant positioning and adequate abutment height (Fig. 5). The implant was placed (Fig. 6) with a simultaneous GBR procedure using demineralized bovine bone graft and a collagen membrane to increase the horizontal bone volume (Fig. 7). Two single monofilament sutures were placed (Fig. 8). The post-operative X-ray shows a correct positioning and the marginal bone in relation to the implant (Fig. 9).

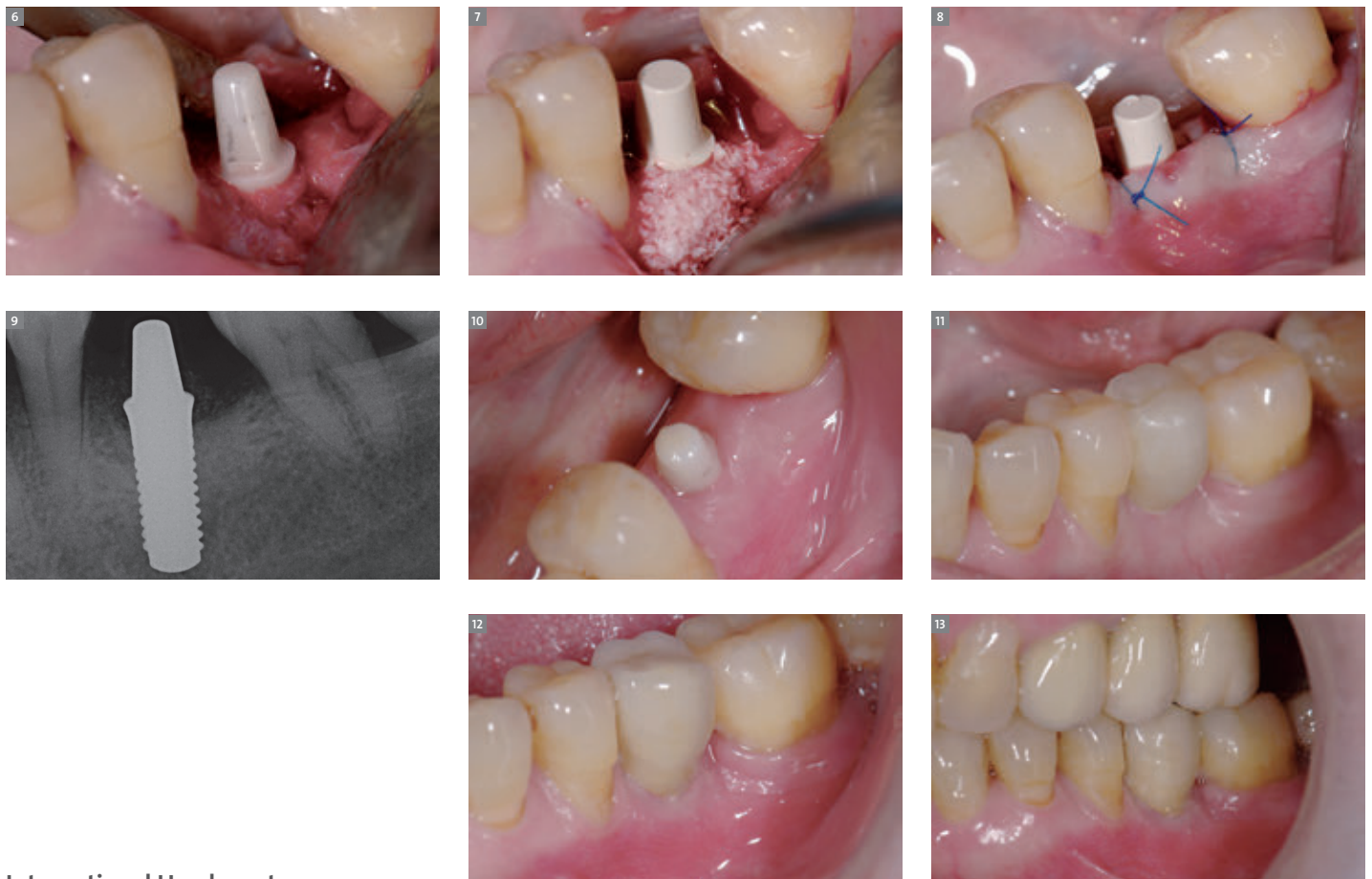PROSTHETIC RESTORATION

After three months of soft and bone tissue healing (Fig. 10), a temporary crown was placed to shape the gingival contours (Fig. 11). The gingival contours were modified with a chairside temporary tooth. After a further three months, the final impres-

sion was taken with the impression coping and a ceramic crown was placed (Figs. 12, 13).

CONCLUSION

The use of a monotype ceramic implant by Straumann with its macro- and micro-rough surface and optimal biocompatibility satisfies not only treatment expectations but also meets the patient's need for a completely metal-free solution. As a preventive treatment approach to avoid a possible cervical shine-through of metal-based implants, the Straumann® PURE Ceramic Implant is an excellent solution in patients with thin periodontal biotype and generalized gingival recessions. The GBR procedure was the same as for titanium implants.



International Headquarters

Institut Straumann AG
Peter Merian-Weg 12
CH-4002 Basel, Switzerland
Phone +41 (0)61 965 11 11
Fax +41 (0)61 965 11 01
www.straumann.com